

Cognitive and Behavioral Consequences in Children with Epilepsy: The Relationship between Paroxysmal EEG Abnormalities and Cognitive/Behavioral Disturbances

Hideaki Kanemura^{1*} and Masao Aihara²

¹Department of Pediatrics, Faculty of Medicine University of Yamanashi, Japan

²Interdisciplinary Graduate School of Medicine and Engineering, University of Yamanashi, Japan

Abstract

A relationship between epilepsy and impairment of neuropsychological functioning has been observed in children with epilepsy. Interictal epileptiform discharges on electroencephalograms (EEGs) are regarded as a correlate of persistent pathological neuronal discharges. Paroxysmal abnormalities in the frontal area may be associated with neuropsychological impairments. Investigations of paroxysmal EEG abnormalities are also needed. Subclinical discharges contribute to the psychosocial problems of children with epilepsy. A combination of spike rate and extended periods of high-frequency paroxysmal EEG abnormalities may predict the atypical evolution of benign childhood epilepsy with centrotemporal spikes. In addition, children with epilepsy with continuous spike-waves during slow sleep have cognitive and behavioral disturbances that are correlated with frequent epileptiform discharges. On the other hand, several studies have suggested that EEG characteristics, especially the localization of paroxysmal discharges, might be important predictors for subsequent epilepsy. Patients with febrile seizure presenting with frontal paroxysmal EEG abnormalities may be at risk for epilepsy. In addition, the frontal paroxysms may indicate a higher risk of epilepsy in autism spectrum disorders. Moreover, the location of paroxysmal EEG abnormalities correlates with behavioral disturbances. Frontal EEG paroxysms may be associated with a higher risk of developing atypical clinical features such as seizure recurrence and cognitive/behavioral problems. Previous and current studies suggest that a combination of spike frequency, extended periods of high-frequency paroxysmal EEG abnormalities, and frontal EEG focus might predict atypical clinical manifestations, such as neuropsychological impairments, and ultimate neuropsychological outcome in children with epilepsy. To prevent these disturbances and problems in children with epilepsy, treatment to remit seizures and EEG abnormalities as soon as possible may be required to achieve the optimal prognosis for children with cognitive/behavioral problems.

Keywords: Behavior; Cognition; Electroencephalogram (EEG); Spike rate frequency; Frontal lobe; Location of EEG focus; Paroxysmal abnormality; Seizure recurrence

Introduction

A relationship between epilepsy and impairment of neuropsychological functioning in children has been observed. Many papers have discussed the impact of childhood epilepsies on cognitive and behavioral development. Many studies have been carried out with institutionalized children with epilepsy with frequent seizures and/or epilepsy syndromes associated with structural brain lesions [1]. On the other hand, epileptic seizures result from an excessive, synchronous discharge of cerebral neurons. Interictal epileptiform discharges on electroencephalogram (EEG) are regarded as a correlate of persistent pathological neuronal discharges [2]. Secondary bilateral synchrony (SBS), which is one of the interictal paroxysmal EEG abnormalities, appears to be associated with cognitive decline and behavioral problems. Indeed, many children with epilepsy with continuous spikes and waves during slow sleep (CSWS), which is a representative epileptic syndrome of SBS, develop severe cognitive and behavior deterioration that is unresponsive to medical treatment as the disease progresses [3]. In addition, children with atypical evolution of benign childhood epilepsy with centrotemporal spikes (BCECTS) may present with neuropsychological impairments related to atypical EEG features such as frequent spikes [4]. Moreover, children with attention deficit/hyperactivity disorder (ADHD) showing rolandic spikes tend to exhibit more hyperactive-impulsive symptoms correlated to frontal lobe functions [5]. Thus, interictal EEG abnormalities may be associated with neuropsychological impairments.

The frontal lobes are critical for normal development because of

their rich connections with other cerebral regions and their central role in efficient executive function [6]. Several current studies have shown that damage to the frontal regions during childhood may interrupt normal maturational processes and organization, resulting in impairments to neurobehavioral development [5,7,8]. Integrative executive functions may thus rely on the health of frontal lobe tissue and connectivity with the rest of the cortex [9]. These findings suggest that paroxysmal abnormalities in the frontal area may be associated with neuropsychological impairments. Thus, investigations focusing specifically on paroxysmal EEG abnormalities are also needed.

Frequency of Interictal Epileptiform Activity and Neuropsychological Impairments in Children with Epilepsy

It is increasingly recognized that transient cognitive impairment may accompany interictal spike discharges, especially when these are frequent [10]. Weglage et al. however, concluded that spike

***Corresponding author:** Hideaki Kanemura, Department of Pediatrics, Faculty of Medicine, University of Yamanashi, 1110 Chuo, Yamanashi 409-3898, Japan, Tel: +81-55-273-9606; Fax: +81-55-273-6745; E-mail: ykimu@yamanashi.ac.jp

Received May 20, 2013; Accepted June 08, 2013; Published June 12, 2013

Citation: Kanemura H, Aihara M (2013) Cognitive and Behavioral Consequences in Children with Epilepsy: The Relationship between Paroxysmal EEG Abnormalities and Cognitive/Behavioral Disturbances. *Pediat Therapeut* 3: 151. doi:10.4172/2161-0665.1000151

Copyright: © 2013 Kanemura H, et al. This is an open-access article distributed under the terms of the Creative Commons Attribution License, which permits unrestricted use, distribution, and reproduction in any medium, provided the original author and source are credited.

frequency was not correlated with specific neuropsychological and language functions [11]. In contrast, several studies have shown that neuropsychological functioning improves with normalization of the EEG [12]. In addition, performances in the neuropsychological assessments were specifically weakened in individuals with active epilepsy with frequent spike-wave discharges on the waking EEG [13]. Current research has shown that EEG improvement, seen as spike rate reduction, with antiepileptic drug treatment showed a high correlation with behavioral improvements, as shown by ADHD-rating scale and global assessments of functioning scores [14]. These findings suggest that subclinical discharges contribute to the psychosocial problems in children with epilepsy [15].

BCECTS is characterized by an absence of neurological deficits, motor focal seizures, a typical EEG, and spontaneous recovery [16]. In general, BCECTS is associated with an excellent prognosis. However, some authors have recently suggested that some children with BCECTS can demonstrate intellectual impairment and behavioral disturbances such as impulsivity [13,17,18]. In a random population of children with BCECTS, the atypical EEG criteria defined by Massa et al. are rarely observed [19]. In recent volumetric studies, a longer active seizure period involving frequent spike-waves coupled with the occurrence of frequent seizures appeared to be associated with prefrontal lobe growth disturbance, which is related to neuropsychological problems [4,7]. Accordingly, clinical and EEG markers are being sought to predict atypical evolution of BCECTS. Current research has shown that spike rates were higher in the atypical evolution of BCECTS group than in the typical BCECTS group (Figure 1) [20]. Moreover, this study also showed that the high frequency of EEG abnormalities such as frequent paroxysmal discharges lasted for extended periods in the atypical group [20]. These findings and previous studies suggest that a combination of spike rate and extended periods of high-frequency paroxysmal EEG abnormalities might predict the atypical evolution of BCECTS [19,21]. Thus, some children with BCECTS may present with cognitive and behavioral disturbances that are correlated with frequent epileptiform discharges.

On the other hand, CSWS is a rare epileptic syndrome occurring in children. CSWS is a functional disorder with the following features: severe paroxysmal EEG disturbance, occupying at least 85% of non-REM sleep; seizures that may be severe but self-limited; behavioral

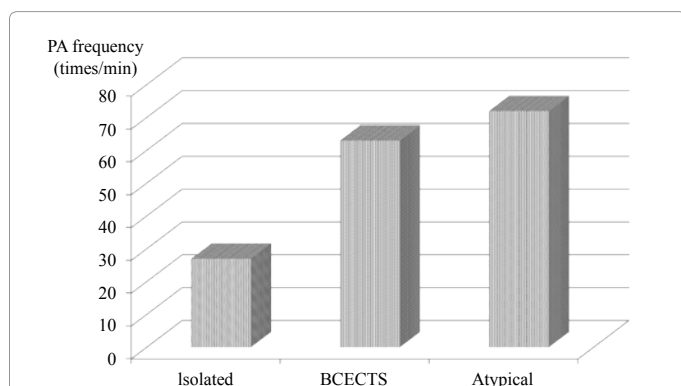


Figure 1: The relationship between seizure recurrence and spike rate. The frequency of paroxysmal abnormalities is higher in the atypical evolutions of BCECTS group than in the isolated seizure and typical BCECTS group. Abbreviation: BCECTS, benign childhood epilepsy with centrotemporal spikes; Isolated, isolated seizure group of BCECTS; Atypical, atypical evolution of BCECTS; PA, paroxysmal abnormality.

	Non-epilepsy	Epilepsy	P-value
FS (n)			
Frontal	1	3	0.035
Rolandic	5	2	0.341
Occipital	5	0	0.875
ASD (n)			
Frontal	1	5	<0.003
Centrotemporal	3	0	
Multifocal	1	1	

Table 1: The locations of EEG abnormalities with and without epilepsy. Abbreviation: FS, febrile seizure; ASD, autism spectrum disorders.

deterioration, with or without premorbid developmental disturbances; and no demonstrable brain pathology sufficient to explain the behavioral deterioration [22]. Furthermore, one of the clinical manifestations of CSWS is stabilization or improvement of behavior once the epileptiform EEG abnormalities resolve [22]. These findings suggest that frequent spikes may be associated with cognitive and behavioral disturbances in CSWS. This hypothesis has been supported by other clinical studies, such as brain volumetric studies [23,24]. In addition, CSWS patients with an EEG response, such as spike rate reduction by levetiracetam (LEV), showed decreased behavioral problems, such as hyperactivity and impulsivity [25]. This finding also supports that hypothesis. Accordingly, children with CSWS have cognitive and behavioral disturbances that are correlated with frequent epileptiform discharges.

Relationship between Frontal Spikes and Neuropsychological Impairments in Children with Epilepsy

Several studies have suggested that EEG characteristics, especially the localization of paroxysmal discharges, might be important predictors of subsequent epilepsy. The EEG is of limited value in the evaluation of children with febrile seizure (FS) [26,27]. An early postictal standard EEG would not be helpful, since EEG findings lack predictive value for the later occurrence of either further febrile or afebrile seizures [27]. However, current research has shown that FS patients with frontal EEG paroxysms had a significantly higher risk of developing epilepsy than those without an EEG abnormality and with paroxysms involving EEG foci in other regions (Table 1) [28]. This finding suggests that patients with FS presenting with frontal paroxysmal EEG abnormalities might be at risk for epilepsy.

On the other hand, in patients with autism spectrum disorders (ASDs), EEG paroxysmal abnormalities are frequently recorded. Recent research has reported that the majority of paroxysmal abnormalities at the time of epilepsy onset appeared in the frontal area [29]. Similarly, current research has shown that the spike patterns in ASDs of epilepsy patients differ from those in patients without epilepsy [30]. This finding suggests that the incidence of later development of epilepsy in ASDs might depend on the location of the EEG paroxysmal abnormality (Table 1) [30], consistent with a previous report [31]. The authors concluded that the frontal paroxysms may indicate a higher risk for epilepsy in ASDs [30].

In another study, the duration of the frontal EEG focus was greater in participants in the atypical evolution of BCECTS group than in those in the rolandic epilepsy group [20]. Neuropsychological findings observed in atypical evolution of BCECTS patients suggested primary or secondary involvement of the frontal cortex, particularly of supplementary motor areas [32]. A previous morphological study

showed that prefrontal lobe volume showed no increase even after remission of seizure disorders in individuals with atypical evolution of BCECTS [4]. These findings may contribute to the result illustrating a correlation between extended periods of frontal EEG focus and atypical evolution of BCECTS. Moreover, current research has revealed that patients with a frontal paroxysmal abnormality showed a significantly higher correlation between paroxysmal abnormality frequency and improvement in behavioral disturbances in ADHD children [14]. However, this study also revealed that patients with rolandic paroxysmal abnormalities showed no correlation between paroxysmal abnormality frequency and improvement in behavioral problems. These findings suggested that the location of EEG paroxysmal abnormalities might correlate with behavioral disturbances. Frontal EEG paroxysms may be associated with a higher risk of developing atypical clinical features such as seizure recurrence and cognitive/behavioral problems.

Pathological Mechanisms Underlying Cognitive and Behavioral Impairments in Children with Epilepsy

There is general agreement about the fact that the immature brain is more prone to generation of epileptic seizures than the mature brain. In contrast, there has been a long-lasting discussion on the possible consequences of seizures in the immature brain. More frequent and severe seizures have been associated with behavioral disturbances in previous studies [33,34]. The frequency of complex partial seizures in the previous year was the strongest predictor of behavioral disturbances [35]. In more recent research, seizure frequency and poor seizure control have been proposed as risk factors associated with attention difficulties and inability to inhibit impulsive responses, since these disturbances improved with adequate seizure control [36-38]. A recent magnetic resonance imaging volumetric study showed that damage to the frontal regions during childhood might interrupt normal maturational processes and organization, resulting in impairments to neurobehavioral development [8]. Moreover, in other reports with BCECTS and CSWS, an active seizure period involving frequent spike-waves coupled with the occurrence of frequent seizures appeared to be associated with prefrontal lobe growth [4,7,23,24]. These findings may support possible explanations for the relationship between seizure activity and neurobehavioral impairments by Austin et al., that seizure activity per se disrupts behavior [36].

Given the impact of behavioral disturbances and their seemingly high prevalence, there is a need for studies of the etiology of seizure-associated behavioral disturbances. Frontal localization of an epileptic focus correlates with executive dysfunction [39]. Several hypotheses have been presented: (a) the high prevalence of similar psychiatric changes among patients with primary frontal and primary temporal epileptogenic zones has been related to the intimate connection of the frontal and temporal limbic system [40]; (b) cognitive and behavioral problems can be the result of epilepsy-related factors, including the age of onset of seizures, the number of seizures, the occurrence of secondary generalized seizures, and the location and extension of the epileptic focus [41]; (c) the association between psychosis or ictal fear and frontal lobe epilepsy has been related to the reciprocal connections between the amygdala, orbitofrontal, and anterior cingulate regions and between the frontal and temporal lobes through the uncinate fasciculus and the superior longitudinal fasciculus [42]; (d) aggressive behavior has been related to activation of limbic activity [38]; and (e) spreading of discharges from primary foci to other frontal, temporal, or limbic structures may be another explanation [43].

How should we Treat Children with Epilepsy Presenting with Cognitive/Behavioral Problems?

As described above, neuronal damage and behavioral impairments/cognitive decline have long been recognized as sequelae of intractable epilepsy in children. Thus, early seizure control is crucial for physiological and social reasons. Several studies, including prospective brain volumetric studies, have shown that an active seizure period involving frequent spike-waves coupled with the occurrence of frequent seizures may be associated with prefrontal lobe growth disturbance, which correlates with neuropsychological impairments [4,7,23,24]. In considering outcomes for children with epilepsy, control of seizures must be weighed against the incidence of neurological impairments.

In epilepsy, localization has been identified as a risk factor for therapy resistance [44]. In particular, seizures originating from the frontal lobe may often be difficult to control. A recent report showed that only half of these patients was controlled on anti-epileptic drug (AED) treatment [45]. Few AEDs may control intractable epilepsy involving the frontal lobe, such as atypical evolution of BCECTS, CSWS, and FLE, but none of them proved to be efficient in a randomized study. A new broad-spectrum AED for childhood epilepsy should be effective in both partial and generalized seizures [46]. Levetiracetam (LEV) is a new AED approved as adjunctive treatment for partial epilepsy [47-49]. Recent research has shown that LEV could be a useful option, with efficacy and safety in children with refractory epilepsy [50]. Moreover, LEV may be an alternative therapy in refractory childhood epilepsy with SBS [25]. This add-on study showed the usefulness of LEV in reducing both SBS on EEG and seizure frequency, and also showed decreased hyperactivity and impulsivity in these patients [25]. These findings suggest that frontal epileptic origin seizures might obtain the greatest benefit from LEV. LEV may represent an important addition to the treatments available for refractory childhood epilepsies with neuropsychological impairments.

In conclusion, a combination of spike frequency, extended periods of high-frequency paroxysmal EEG abnormalities, and frontal EEG focus may predict atypical clinical manifestations, such as neuropsychological impairments, and ultimate neuropsychological outcome in children with epilepsy. To prevent these disturbances and problems in children with epilepsy, early treatment to remit seizures and EEG abnormalities may be required to achieve the optimal prognosis for children with cognitive/behavioral problems.

References

1. Metz-Lutz MN, Massa R (1999) Cognitive and behavioural consequences of epilepsies in childhood. In: Nehlig A, Motte J, Moshe SL, Plouin P, editors. *Childhood epilepsies and brain development*. John Libbey & Company Ltd, London. 123-134.
2. Wolff M, Weiskopf N, Serra E, Preissl H, Birbaumer N, et al. (2005) Benign partial epilepsy in childhood: selective cognitive deficits are related to the location of focal spikes determined by combined EEG/MEG. *Epilepsia* 46: 1661-1667.
3. Smith MC, Hoepfner TJ (2003) Epileptic encephalopathy of late childhood: Landau-Kleffner syndrome and the syndrome of continuous spikes and waves during slow-wave sleep. *J Clin Neurophysiol* 20: 462-472.
4. Kanemura H, Hata S, Aoyagi K, Sugita K, Aihara M (2011) Serial changes of prefrontal lobe growth in the patients with benign childhood epilepsy with centrotemporal spikes presenting with cognitive impairments/behavioral problems. *Brain Dev* 33: 106-113.
5. Holtmann M, Becker K, Kentner-Figura B, Schmidt MH (2003) Increased frequency of rolandic spikes in ADHD children. *Epilepsia* 44: 1241-1244.

6. Anderson V, Levin HS, Jacobs R (2002) Executive functions after frontal lobe injury: a developmental perspective. In: Stuss DT, Knight R, editors. *Principles of frontal lobe function*. Oxford University Press, New York. 504-527.
7. Kanemura H, Aihara M (2009) Growth disturbance of frontal lobe in BCECTS presenting with frontal dysfunction. *Brain Dev* 31: 771-774.
8. Kanemura H, Sano F, Tando T, Sugita K, Aihara M (2012) Repeated seizures induce prefrontal growth disturbance in frontal lobe epilepsy. *Brain Dev* 34: 175-180.
9. Goldberg E, Bilder RM (1987) The frontal lobes and hierarchical organization of cognitive control. In: Perecman E, editor. *The frontal lobes revisited*. JRB Press, New York. 159-187.
10. Ong HT, Wyllie E (2000) Benign childhood epilepsy with centrotemporal spikes: is it always benign? *Neurology* 54: 1182-1185.
11. Weglage J, Demsky A, Pietsch M, Kurlemann G (1997) Neuropsychological, intellectual, and behavioral findings in patients with centrotemporal spikes with and without seizures. *Dev Med Child Neurol* 39: 646-651.
12. Baglietto MG, Battaglia FM, Nobili L, Tortorelli S, De Negri E, et al. (2001) Neuropsychological disorders related to interictal epileptic discharges during sleep in benign epilepsy of childhood with centrotemporal or Rolandic spikes. *Dev Med Child Neurol* 43: 407-412.
13. Metz-Lutz MN, Kleitz C, de Saint Martin A, Massa R, Hirsch E, et al. (1999) Cognitive development in benign focal epilepsies of childhood. *Dev Neurosci* 21: 182-190.
14. Kanemura H, Sano F, Tando T, Hosaka H, Sugita K, et al. (2013) EEG improvements with antiepileptic drug treatment can show a high correlation with behavioral recovery in children with ADHD. *Epilepsy Behav* 27: 443-448.
15. Binnie CD (2003) Cognitive impairment during epileptiform discharges: is it ever justifiable to treat the EEG? *Lancet Neurol* 2: 725-730.
16. Bernardina BD, Sgro V, Fejerman N (2005) Epilepsy with centro-temporal spikes and related syndromes. In: Roger J, Bureau M, Dravet C, Genton P, Tassinari CA, Wolf P, editors. *Epileptic syndromes in infancy, childhood and adolescence (4th edn)*. John Libbey Eurotext, Montrouge. 203-225.
17. Fejerman N, Caraballo RH, Bernardina BD (2007) Atypical evolutions of benign focal epilepsies in childhood. In: Fejerman N, Caraballo RH, editors. *Benign focal epilepsies in infancy, childhood and adolescence*. John Libbey Eurotext, Montrouge. 179-219.
18. Yung AW, Park YD, Cohen MJ, Garrison TN (2000) Cognitive and behavioral problems in children with centrotemporal spikes. *Pediatr Neurol* 23: 391-395.
19. Massa R, de Saint-Martin A, Carcangiu R, Rudolf G, Seegmuller C, et al. (2001) EEG criteria predictive of complicated evolution in idiopathic rolandic epilepsy. *Neurology* 57: 1071-1079.
20. Kanemura H, Sano F, Aoyagi K, Sugita K, Aihara M (2012) Do sequential EEG changes predict atypical clinical features in rolandic epilepsy? *Dev Med Child Neurol* 54: 912-917.
21. Metz-Lutz MN, Filippini M (2006) Neuropsychological findings in Rolandic epilepsy and Landau-Kleffner syndrome. *Epilepsia* 47 Suppl 2: 71-75.
22. Smith MC, Polkey CE (2008) Landau-Kleffner syndrome and CSWS. In: Engel Jr. J, Pedley TA, Aicardi J, Moshe SL, Dichter MA, Trimble MR, Perucca E, editors. *Epilepsy. A comprehensive textbook*. 2nd ed. Lippincott Williams & Wilkins, Philadelphia 2429-2438.
23. Kanemura H, Sugita K, Aihara M (2009) Prefrontal lobe growth in a patient with continuous spike-waves during slow sleep. *Neuropediatrics* 40: 192-194.
24. Kanemura H, Aihara M (2011) Sequential prefrontal lobe volume changes in epileptic patients with continuous spikes and waves during slow sleep. In: Gadze ZP, editor. *Epilepsy in children-clinical and social aspects*. Intech Publishers Rijeka, Croatia 13-24.
25. Kanemura H, Sano F, Sugita K, Aihara M (2013) Effects of levetiracetam on seizure frequency and neuropsychological impairments in children with refractory epilepsy with secondary bilateral synchrony. *Seizure* 22: 43-47.
26. Koyama A, Matsui T, Sugisawa T (1991) Febrile convulsions in northern Japan: a quantitative and qualitative analysis of EEG and clinical findings. *Acta Neurol Scand* 83: 411-417.
27. Stores G (1991) When does an EEG contribute to the management of febrile seizures? *Arch Dis Child* 66: 554-557.
28. Kanemura H, Mizorogi S, Aoyagi K, Sugita K, Aihara M (2012) EEG characteristics predict subsequent epilepsy in children with febrile seizure. *Brain Dev* 34: 302-307.
29. Kawasaki Y, Shinomiya M, Takayanagi M, Niwa S (2010) Paroxysmal EEG abnormalities and epilepsy in pervasive developmental disorders: follow-up study until adolescence and beyond. *Brain Dev* 32: 769-775.
30. Kanemura H, Sano F, Tando T, Sugita K, Aihara M (2013) Can EEG characteristics predict development of epilepsy in autistic children? *Eur J Paediatr Neurol* 17: 232-237.
31. Hashimoto T, Sasaki M, Sugai K, Hanaoka S, Fukumizu M, et al. (2001) Paroxysmal discharges on EEG in young autistic patients are frequent in frontal regions. *J Med Invest* 48: 175-180.
32. Tassinari CA, Rubboli G, Shibasaki H (1998) Neurophysiology of positive and negative myoclonus. *Electroencephalogr Clin Neurophysiol* 107: 181-195.
33. Hoare P (1984) The development of psychiatric disorder among schoolchildren with epilepsy. *Dev Med Child Neurol* 26: 3-13.
34. Austin JK, Risinger MW, Beckett LA (1992) Correlates of behavior problems in children with epilepsy. *Epilepsia* 33: 1115-1122.
35. Schoenfeld J, Seidenberg M, Woodard A, Hecox K, Inglese C, et al. (1999) Neuropsychological and behavioral status of children with complex partial seizures. *Dev Med Child Neurol* 41: 724-731.
36. Austin JK, Dunn DW, Caffrey HM, Perkins SM, Harezlak J, et al. (2002) Recurrent seizures and behavior problems in children with first recognized seizures: a prospective study. *Epilepsia* 43: 1564-1573.
37. Derry CP, Heron SE, Phillips F, Howell S, MacMahon J, et al. (2008) Severe autosomal dominant nocturnal frontal lobe epilepsy associated with psychiatric disorders and intellectual disability. *Epilepsia* 49: 2125-2129.
38. Braakman HM, Vaessen MJ, Hofman PA, Debeij-van Hall MH, Backes WH, et al. (2011) Cognitive and behavioral complications of frontal lobe epilepsy in children: a review of the literature. *Epilepsia* 52: 849-856.
39. Vago C, Bulgheroni S, Franceschetti S, Riva D (2011) Frontal lobe epilepsies: neuropsychological and behavioral consequences in children. In: Gadze ZP, editor. *Epilepsy in children-clinical and social aspects*. Intech Publishers Rijeka, Croatia 187-212.
40. Blumer D, Wakhlu S, Davies K, Hermann B (1998) Psychiatric outcome of temporal lobectomy for epilepsy: incidence and treatment of psychiatric complications. *Epilepsia* 39: 478-486.
41. Fohlen M, Bulteau C, Jalin C, Jambaque I, Delalande O (2004) Behavioural epileptic seizures: a clinical and intracranial EEG study in 8 children with frontal lobe epilepsy. *Neuropediatrics* 35: 336-345.
42. Mega MS, Cummings JL, Salloway S, Malloy P (1997) The limbic system: an anatomic, phylogenetic, and clinical perspective. *J Neuropsychiatry Clin Neurosci* 9: 315-330.
43. Sumer MM, Atik L, Unal A, Emre U, Atasoy HT (2007) Frontal lobe epilepsy presented as ictal aggression. *Neurol Sci* 28: 48-51.
44. Ohtsuka Y, Yoshinaga H, Kobayashi K (2000) Refractory childhood epilepsy and factors related to refractoriness. *Epilepsia* 41 Suppl 9: 14-17.
45. Sinclair DB, Wheatley M, Snyder T (2004) Frontal lobe epilepsy in childhood. *Pediatr Neurol* 30: 169-176.
46. Lagae L, Buyse G, Deconinck A, Ceulemans B (2003) Effect of levetiracetam in refractory childhood epilepsy syndromes. *Eur J Paediatr Neurol* 7: 123-128.
47. Ben-Menachem E, Gilland E (2003) Efficacy and tolerability of levetiracetam during 1-year follow-up in patients with refractory epilepsy. *Seizure* 12: 131-135.
48. Cohen J (2003) Levetiracetam monotherapy for primary generalised epilepsy. *Seizure* 12: 150-153.
49. Wang SB, Weng WC, Fan PC, Lee WT (2008) Levetiracetam in continuous spike waves during slow-wave sleep syndrome. *Pediatr Neurol* 39: 85-90.
50. Kanemura H, Sano F, Tando T, Sugita K, Aihara M (2013) Efficacy and safety of add-on levetiracetam in refractory childhood epilepsy. *Brain Dev* 35: 386-391.