

Closed Head Injury: How Air Reaches the Cranial Venous Sinus?

Abad Cherif El Asri*

Department of Neurosurgery, Military Hospital, Rabat, Morocco

Abstract

Air in the intracranial vascular compartment is uncommon, with only few reported case in the literature. In the absence of surgery or open head trauma, the origin of air bubbles in the venous sinus is still debated. We report a case of patient admitted in emergency room few minutes after a severe closed head injury, and in whom, the cranial CT-scan demonstrated feature of air along the superior sagittal sinus. Mechanisms explaining how air reaches the venous compartment will be discussed.

Keywords: Head injury; Air embolism; Venous sinus

Case Report

A 45-year-old male presented 15 minutes after fall on stairs with severe closed head injury. On admission, the patient was unconscious, in a decerebrating state with anisocoria. There was no evidence of cerebrospinal fluid leak. In the intensive care unit, two 16-gauge peripheral intravenous catheters were inserted and the patient was intubated and artificially ventilated. A cranial CT scan, was performed immediately, and was revealed a left acute subdural haematoma with diffuse massive cerebral oedema and significant mass effect. Lower slices disclosed air at the level of the superior sagittal sinus (Figure.1). Densitometric measurement confirmed the air which varied between 245 and 325 HU. No definite fracture was viewed on the initial CT scan. There were no other external injuries. Immediate surgery was undertaken. A large left-sided fronto-parieto-temporal craniotomy was performed, the parieto-temporal subdural haematoma was removed, and the haemostasis of the bleeding cortical veins was achieved. Post-operatively, the patient declined, and died few hours later.

Discussion

Free air in the intracranial cavity can often be shown on CT after cranial trauma, barotrauma, tumors, infections, some surgical interventions, after craniotomy, craniofacial reconstruction, posterior fossa operations in the sitting position, some interventional procedures

such as lumbar puncture and insertion of arterial or venous catheters, nitrous oxide anaesthesia, and congenital cranium defects [1]. Post-traumatic air embolism in the cerebral venous sinuses is a rare finding in closed injury [1-5]. Various pathways have been proposed to explain intravascular pneumocephalus. One theory postulated that peripherally injected air ascends passively within the venous system in response to gravitational forces counter current to jugular venous flow [5]. Air may also be seen in the scalp veins, infratemporal fossa, carotid canal, straight sinus, superior ophthalmic vein, superior sagittal sinus, veins around the foramen magnum, and the inferior petrosal sinus [4]. In other hand, once air enters the central venous circulation, the lower specific weight of air bubbles as compared to blood will always cause the bubbles to rise to the cranium in a patient positioned upright, provided the air bubbles move at a velocity greater than that of the opposing blood flow in the vein [1,3,4]. The second theory is that fractures cause a defect of dura and arachnoid and, therefore, the difference between intracranial pressure and atmospheric pressure could cause absorption of air through fracture line, and then check-valve mechanism entraps air [2]. In the present case it was difficult to explain the origin of air in the intracranial venous sinus, although that the first theory appear more probable. Although, the air embolism might rich more frequently the intracranial venous compartment, arterial air embolus was previously described. It may result from paradoxical embolism, even in the absence of an intracardiac shunt, as has been reported previously in humans and confirmed in dog models [2,4,5]. Air is thought to pass from the venous to the arterial circulation either via pre pulmonary arteriovenous shunts or by directly crossing the pulmonary capillary bed. The detection of cranial intravascular air in a patient with cranial trauma could be dependent on the timing of the imaging [1,3]. Brain CT is diagnostic only if obtained immediately because air is rapidly resorbed from the brain arterioles. Although intravascular air could not be demonstrated by angiography or magnetic resonance venography due to the patient's status, in the present case radiological findings confirmed that the air was intravascular. This unexpected radiographic finding should not necessarily be cause for alarm, and there is no evidence that intravenous pneumocephalus alone is harmful; intravascular pneumocephalus is different from intraparenchymal pneumocephalus [1,2]. MRI with diffusion weighted imaging (DWI)

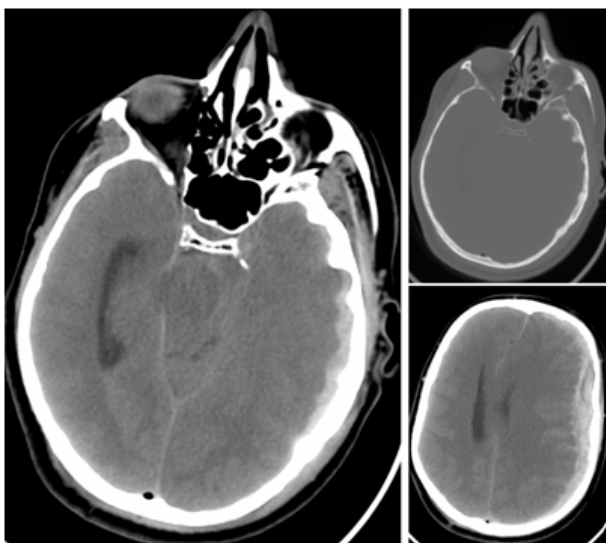


Figure 1: Cranial CT-scan, performed few minutes after the head injury, showing the large fronto-parietal acute subdural haematoma with the presence of air bubbles along the superior sagittal sinus.

*Corresponding author: Abad Cherif El Asri, Department of Neurosurgery, Military Hospital, Rabat, Morocco, E-mail: abad20031@hotmail.com

Received March 22, 2012; Accepted May 23, 2012 Published May 25, 2012

Citation: El Asri AC (2012) Closed Head Injury: How Air Reaches the Cranial Venous Sinus? Emergency Med 2:121. doi:10.4172/2165-7548.1000121

Copyright: © 2012 El Asri AC. This is an open-access article distributed under the terms of the Creative Commons Attribution License, which permits unrestricted use, distribution, and reproduction in any medium, provided the original author and source are credited.

in the few hours might show multiple areas of restricted diffusion affecting predominantly cortical areas [2,4]. As a result, we suggest that when such a finding is noted, the use of intravenous catheters should be investigated and repeat fine-cut imaging and careful consideration of the clinical history and exam should be pursued.

References

1. Cihangiroglu M, Ozdemir H, Kalender O, Ozveren F, Kabaalioglu A (2003) Transverse sinus air after cranial trauma. *Eur J Radiol* 48: 171-174.
2. Orebaugh SL, Margolis JH (1990) Post-traumatic intracerebral pneumatocele: case report. *J Trauma* 30: 1577-1580.
3. Bodkin PA, Shanmuganathan M, Fitzpatrick MO (2010) Air in the cavernous sinus may be due to venous cannulation. *Br J Neurosurg* 24: 309-310.
4. Yang CW, Yang BP (2005) Massive cerebral arterial air embolism following arterial catheterization. *Neuroradiology* 47: 892-894.
5. Thompson TP, Levy E, Kanal E, et al.(1999) Iatrogenic pneumocephalus secondary to intravenous catheterization. Case report. *J Neurosurg* 91: 878-880.