

Clinical Follow-Up after Treatment of Degenerative Lumbar Disease by Posterior Dynamic Stabilizing Technique

Rui Gu, Jian-Wu Zhao, Jian-Hui Zhao*, Jia-Bei Liu and Yi-Fu Sun

Department of Orthopaedic Surgery, China-Japan Union Hospital of Jilin University, China

Abstract

Introduction: Technique of dynamic fixation for treatment of lumbar degenerative has been developed in avoidance of possible adjacent level degeneration. The dynamic rod, consists of titanium alloy cable cord and polyetheretherketone shell, of K-rod posterior dynamic rod system provides flexible feature that mobility preservation of instrumented level shall be achieved. Clinical research for the usage of K-rod system has not been reported with evidence-based support. This retrospective study was aimed to report clinical outcome of K-rod posterior dynamic rod system utilized for degenerative lumbar disease.

Methods: Fifty patients with lumbar degenerative disease ranged from L3 to S1 have been enrolled. Dynamic and hybrid (dynamic rod accompanied by rigid rod) fixations of K-rod system were adequately selected for patients after discectomies of diseased intervertebral discs. Clinical evaluations including Japanese Orthopedic Association Scores (JOA), Oswestry Disability Index (ODI), and Visualized Analogue Scale (VAS) have been conducted pre- and post-operatively.

Results: In the follow-up period (12-36 months, mean 26.4 months), great improvements in JOA, ODI, and VAS were respectively 73.34%, 37.18%, and 77.35% in dynamic fixation group, while those in hybrid fixation group were respectively 76.37%, 30.5%, and 71.68%, with no statistical difference between the two groups. Significantly reduced mobility has been observed in hybrid fixation group compared with its preoperative status.

Conclusions: Current follow-up report of K-rod posterior dynamic rod system represented acceptable clinical satisfactory. The preserved mobility of instrumented segment based on sufficient biomechanical stability can successfully achieve pain relief and functional restoration.

Keywords: Lumbar degenerative disease; K-rod; Non-fusion; Dynamic fixation

Introduction

Spinal rod and pedicle screw fixation represent gold standard in treatment of general degenerative disease of spine, but the loss of segmental motion and the frequently reported complications such as stiff spine, stress-shielding, implant failure, fatigue fractures, and adjacent segment degeneration [1-3] are challenged in recent decades. Novel concept of the semi-rigid fixation has been introduced with the constrained-dynamic feature. Commercial products such as the Isobar (Alphatec Spine, Inc.), BioFlex (Bio-Spine), and DYNESYS (Zimmer, Inc.) are available in current with numerous supportive clinical and biomechanical studies. The K-Rod Posterior Dynamic Rod System (Paonan Biotech Co., Ltd., Taiwan) is also a pedicle screw-based system for dynamic stabilization of spine. By substituting the rigid rod component in conventional pedicle screw system, the flexible feature of the K-Rod system is contributed by its flexible rod consists of titanium alloy cable cords and Polyetheretherketone (PEEK) shells, with an optional combination with rigid rod adjacent to the flexible segment (hybrid type). Sufficient stability at the bridged level and lower effect on adjacent level after implantation of K-Rod system has been biomechanically proved [4]. Due to that few information about the clinical information has been reported in previous literatures, current study aimed to reveal the observation of clinical outcome of K-Rod system via minimal follow-up duration of 12 months.

Materials and Methods

General information

Fifty patients (male: 32, female: 18) underwent instrumentation with K-rod system for treatment of lumbar degenerative disease from February in 2009 to October in 2012. Mean age of patients at surgery was 38 years (range: 19-58). Minimal duration for postoperative follow-

up was 1 year. Numbers of patients with observation disc herniation were 3 in L3-4, 15 in L4-5, 15 in L5-S1, 3 in L3-5, 1 in L2-S1, 12 in L4-S1, and 1 in both L3-4 and L5-S1. One patient has suffered from recurrent disc herniation 6 months after the prior discectomy in a local clinic. Seven patients with multi-level disc herniation underwent dynamic fixation by hybrid K-rod system with adjacent interbody fusion (at the rigid segment of rod), while the other 10 underwent the dynamic fixation only.

All patients have received conservative treatments in our or local clinics for at least 6 months, with insignificant improvements or progressive degenerations, have been confirmed that surgical treatments were necessary. Complete preoperative clinical examinations have been conducted for all patients to exclude contraindications. Radiographs of the neutral anteroposterior view, flexion/extension postures in lateral views, and the MR images were taken to exclude the possible muscle fatigue damage, lumbar deformity, and severe medical illness.

Surgical technique

Patients were operated upon under intravenous-inhalation

***Corresponding author:** Jian-Hui Zhao, MD, Department of Orthopaedic Surgery, China-Japan Union Hospital of Jilin University, 126 Xiantai Blvd, Changchun Changchun, Jilin 130033, China, Tel: +86-0431-89876939; Fax: +86-0431-89876939; E-mail: jhzhao.md@gmail.com

Received February 16, 2016; Accepted February 25, 2016; Published February 29, 2016

Citation: Gu R, Zhao JW, Zhao JH, Liu JB, Sun YF (2016) Clinical Follow-Up after Treatment of Degenerative Lumbar Disease by Posterior Dynamic Stabilizing Technique. Orthop Muscular Syst 5: 208. doi:10.4172/2161-0533.1000208

Copyright: © 2016 Gu R, et al. This is an open-access article distributed under the terms of the Creative Commons Attribution License, which permits unrestricted use, distribution, and reproduction in any medium, provided the original author and source are credited.

compound anesthesia in the prone position, left vacant abdomen. The curvature of lumbar spine has been adjusted to meet the physiological lordosis and was confirmed by C-arm. The midline approach was considered with exposure of spinous process, laminae, and bilateral exterior facet joints. Titanium polyaxial pedicle screws were inserted into the vertebral bodies adjacent to the diseased intervertebral discs with identical insertion depth as possible [5]. Laminectomy was performed referring to the direction of disc herniation. The nucleus pulposus was carefully removed without causing damage on the superior and inferior endplates. The bilateral rods were fixed as parallel as possible [6]. Usage of the dynamic (Figure 1) / hybrid systems (Figure 2) are listed in Table 1.

Postoperative management

Antibiotics were administrated for 3 times in the period from 30 minutes preoperatively to 24 hours postoperatively. Drainage tube was removed 24-48 hours after surgery. Ambulatory was allowed for patient who received only K-rod system fixation 5 days after surgery, while 10 days were allowed for patients (with waist support) underwent K-rod system fixation combined with adjacent interbody fusion. The waist support was removed after 4-6 weeks and began to have lumbar and dorsal muscle training. Follow-ups in our clinic were performed at 1, 3, 6, 12 months, and every 6 months from the second year after surgery.

Clinical evaluation

Japanese Orthopedic Association Scores (JOA), Oswestry Disability Index (ODI), and Visualized Analogue Scale (VAS) were considered for pre- and post-operative evaluation on low back pains and quality of lives for patients. Quantified improvements were calculated as follows [7]:

$$\text{Improvement in JOA (\%)} = (\text{post-op score} - \text{pre-op score}) / (29 - \text{pre-op score}) \times 100\%$$

$$\text{Improvement in ODI (\%)} = (\text{pre-op score} - \text{post-op score}) / (45 - \text{post-op score}) \times 100\%$$

$$\text{Improvement in VAS (\%)} = (\text{pre-op score} - \text{post-op score}) / (\text{pre-op score}) \times 100\%$$

As for kinematic assessment, the pre- and post-operative

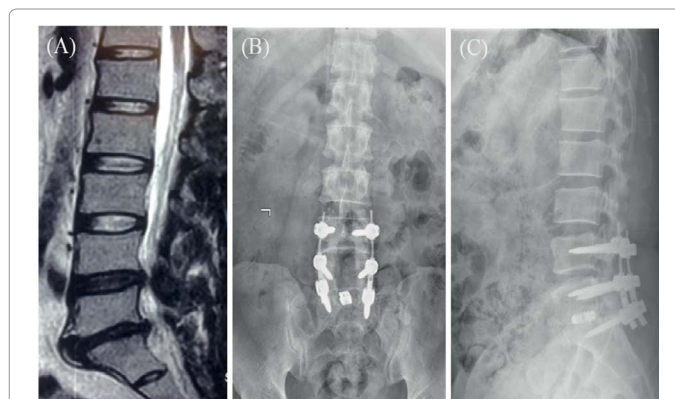


Figure 2: A 52-year-old male diagnosed as L4-5 and L5-S1 disc herniation in MR image (A). Radiographs of 14 months after hybrid K-rod system instrumentation in anteroposterior (B) and lateral (C) views. Dynamic fixation at L4-5 while the L5-S1 has been fixed with rigid rod with cage insertion. Good clinical outcome with adequate intervertebral space preservation at both instrumented levels without adjacent level problem.

Levels of disc degeneration	Number of patients
Single-level	
dynamic L3-4	3
dynamic L4-5	15
dynamic L5-S1	15
Multi-levels	
dynamic L3-4 / rigid L4-5	2
dynamic L4-5 / rigid L5-S1	4
dynamic L2-3, L4-5 / rigid L3-4, L5-S1	1
dynamic L4-S1	8
dynamic L3-5	1
dynamic L3-4, L5-S1	1

Table 1: Usage of dynamic / rigid rods in degenerative levels.

lateral radiographs in flexion/extension postures were acquired for measurements in segmental (with dynamic fixation) and full lumbosacral Range of Motions (ROMs) [8].

Statistics

All data were imported into SPSS 18.0 for statistical evaluation. Quantified data were represented as (mean value ± standard deviation). Differences between preoperative status and the performance in the last follow-up were assessed by paired *t* test, while the intergroup comparisons were conducted by on way ANOVA. Statistical significance was represented by $p < 0.05$.

Results

Follow-up duration was 26.4 months (12-36 months) for the 50 patients in this study. The mean operational time consumption was 126 ± 38 (90-250) minutes, and the mean operative blood loss was 120 ± 40 (80-500) ml. No nerve root was harmed in all surgeries. One patient suffered from lower extremity deep venous thrombosis 10 days postoperatively and was transferred to Division of Vascular Surgery with successful treatment. A top right pedicle screw loosening was observed in one patient received dynamic fixation at L3-4 and rigid fixation at L4-5, and secondary surgery was performed. No complications such as implant failure and loosening were observed in the rest of the patients.

Statistical significances ($p < 0.05$) in JOA, ODI, and VAS have been

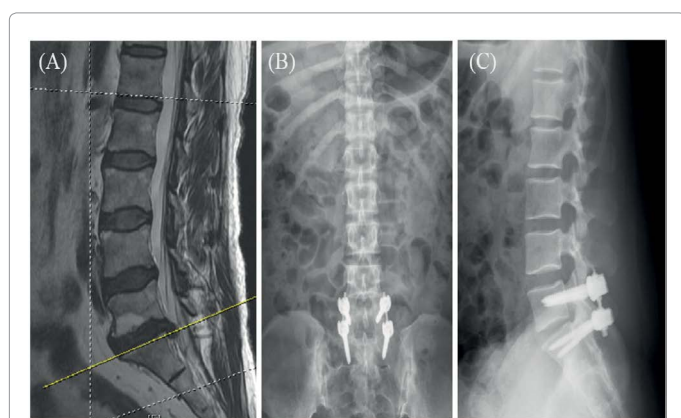


Figure 1: A 40-year-old female diagnosed as L5-S1 disc herniation in MR image (A). Radiographs of 10 months after single-level K-rod dynamic fixation at L5-S1 in anteroposterior (B) and lateral (C) views showed good intervertebral space preservation at the instrumented level without adjacent level problem.

represented between pre- and post-operative evaluations (Table 2). Table 3 represents the comparative information, although insignificant in statistics ($p > 0.05$), for the aforementioned clinical index/scores between the usage of dynamic only and the hybrid instrumentations. Segmental or full lumbar range of motion has not been obvious altered after dynamic fixation only, but the full lumbar motion was significantly reduced after hybrid instrumentation (Table 4).

Discussion

Lumbar interbody fusion with rigid fixation after intervertebral disc removal has been considered as the standard surgical strategy for lumbar degenerative disease. With outstanding elastic modulus, fatigue endurance, and biocompatibility, titanium or titanium alloy has been widely accepted as the material applied for spinal instrumentation device. However, complications such as accelerated adjacent disc degeneration, loss of mobility of the instrumented level, reduced total lumbar range of motion due to over-rigidity have been reported. Surgical technique for maintaining spinal stability without compromising its dynamic feature has then been pursued in recent decades [9,10]. The elastic rod made of PEEK material in the K-rod system has preserved segmental mobility while the risks of pedicle screw loosening and failure can be reduced. Biomechanical study has demonstrated that similar stress representation at spinal segments adjacent to instrumented level by PEEK rod may be beneficial to reduce the postoperative adjacent level degeneration [9]. The K-rod system may be more preferable because of its flexible feature that partially enables physiological mobility of instrumented vertebrae, and may avoid complications such as loss of intervertebral motion, stiff spine, and degeneration of adjacent levels [11].

High prevalence of adjacent level degeneration and clinical syndromes around 33.3% reported in Rahm and Hall's clinical follow-up for 5 years due to spinal fusion with rigid fixators [12], while similar clinical study by Ghisell has suggested that reoperations were essential for patients with severe complication after spinal fusion surgeries [13]. Problem of adjacent level degeneration has been demonstrated and noted in numerous biomechanical and clinical studies [14,15]. With the change of life style in recent decades, lumbar disc herniation has now commonly been discovered in young population. Long-

term adjacent level problem and loss of physiological mobility, due to conventional lumbar discectomy and interbody fusion with rigid fixation device, are not acceptable for these young patients [16]. In comparison with conventional simple decompression or spinal fusion, similar physiological performance preserved by dynamic fixation technique may retain adequate patterns of intervertebral motion and load transfer. Risk of postoperative adjacent level degeneration can be reduced while enhancement of structural stability for diseased lumbar segments can be achieved [16].

Lumbar degenerative disease is majorly observed in population of heavy-task occupations, especially for farmyard labors with poor financial capabilities. Severe multi-level disc degenerations /disc herniation accompanied with spinal canal stenosis and articular process degeneration are common. Conventional surgery by applying rigid fixation would greatly compromise spinal mobility and lead to adjacent level problem [17]. Although the developments in concept of non-fusion and implants/instruments for dynamic fixation have been rapidly enhanced, multi-level disc herniation accompanied with severe lumbar degeneration and spinal canal stenosis remained a difficult issue in spinal surgery. Technique of hybrid fixation with both rigid and dynamic features may be considerable for these patients. Careful preoperative physical examinations, MRI, CT, and planar radiographic diagnoses are essential for confirming the status of diseased spinal segments to determine specific surgical plans [18]. For young patients, simple discectomy instrumented with K-rod system would be more preferable in avoidance of the loss of spinal mobility due to multi-level lumbar fusion. Patients with lumbar disc herniation accompanied by spinal canal stenosis, and severe articular process degeneration will be recommended to receive hybrid fixation of K-rod system after discectomy and decompression. Essential restoration of space for nerve root decompression should follow the general concept as described in similar reports of dynamic stabilization devices [18,19].

Clinical outcome in current study revealed that great satisfactory is received from K-rod system applied for patients with lumbar degenerative disease. The dynamic rod not only represented sufficient biomechanical stabilizing effect but partially preserved the mobility of instrument for the instrumented lumbar segment. Avoided or postponed adjacent level degeneration shall be highly expected while the quality of life for patients can be maintained. Although the follow-up period in current study was not very long (26.4 months in average), no significant loss of mobility and screw loosening have been observed in all segments instrumented with dynamic rods.

Conclusion

In summary, the K-rod posterior dynamic rod system can adequately reconstruct physiological performance in load transfer and mobility to meet the biomechanical requirement in stabilization of lumbar spine. Based on the essential achievement of spinal stability, the preservation of dynamic function of instrumented segments may effectively reduce the possible risk for adjacent levels, which can be highly recommended in clinical practice.

References

1. Korovessis P, Papazisis Z, Koureas G, Lambiris E (2004) Rigid, semirigid versus dynamic instrumentation for degenerative lumbar spinal stenosis: a correlative radiological and clinical analysis of short-term results. *Spine (Phila Pa 1976)* 29: 735-742.
2. Mulholland RC, Sengupta DK (2002) Rationale, principles and experimental evaluation of the concept of soft stabilization. *Eur Spine J* 11: 198-205.
3. Liu M, Kan W, Li P, He D (2011) [Effectiveness of discectomy combined with

	Pre-op	Post-op	p value
JOA	10.2 ± 3.6	24.2 ± 2.1	< 0.01
ODI	19.0 ± 5.9	4.5 ± 2.1	< 0.01
VAS	6.6 ± 1.4	1.6 ± 0.8	< 0.01

Table 2: Quantified comparisons of clinical evaluations.

Fixation type	Dynamic only	Hybrid	p value
No. of patients	43	7	-
JOA	73.3 ± 8.7	76.4 ± 9.8	0.661
ODI	37.2 ± 15.2	30.5 ± 5.2	0.119
VAS	77.4 ± 11.2	71.7 ± 9.8	0.697

Table 3: Improvements in clinical evaluation parameters (%).

Segment(s)	Pre-OP	Post-OP	p value
L3-4	6.8 ± 1.3	6.8 ± 1.4	1.00
L4-5	7.6 ± 1.0	7.5 ± 1.0	0.32
L5-S1	8.4 ± 0.9	8.4 ± 0.8	0.1
L1-S1 (dynamic fixation only)	31.1 ± 3.4	31.0 ± 3.4	0.62
L1-S1 (hybrid fixation)	28.0 ± 3.9	24.8 ± 4.2	<0.01

Table 4: Comparisons of segmental and full lumbosacral range of motions (°).

- Isobar non-fusion internal fixation in treating lumbar disc protrusion]. *Zhongguo Xiu Fu Chong Jian Wai Ke Za Zhi* 25: 229-234.
4. Lin HM, Pan YN, Liu CL, Huang LY, Huang CH, et al. (2013) Biomechanical comparison of the K-ROD and Dynesys dynamic spinal fixator systems-a finite element analysis. *Biomed Mater Eng* 23: 495-505.
 5. Courville C, Torretti J, Sengupta DK (2008) Dynamic stabilization: principles and current clinical practice. *Semin Spine Surg* 20: 146-153.
 6. Schmoelz W, Erhart S, Unger S, Disch AC (2012) Biomechanical evaluation of a posterior non-fusion instrumentation of the lumbar spine. *Eur Spine J* 21: 939-945.
 7. Qi L, Li M, Zhang S, Xue J, Si H (2013) Comparative effectiveness of PEEK rods versus titanium alloy rods in lumbar fusion: a preliminary report. *Acta Neurochir (Wien)* 155: 1187-1193.
 8. Canbay S, Aydin AL, Aktas E, Erten SF, Basmaci M, et al. (2013) Posterior dynamic stabilization for the treatment of patients with lumbar degenerative disc disease: long-term clinical and radiological results. *Turk Neurosurg* 23: 188-197.
 9. Sengupta DK, Bucklen B, McAfee PC, Nichols J, Angara R, et al. (2013) The Comprehensive Biomechanics and Load-Sharing of Semirigid PEEK and Semirigid Posterior Dynamic Stabilization Systems. *Adv Orthop* 2013: 745610.
 10. Stoll TM, Dubois G, Schwarzenbach O (2002) The dynamic neutralization system for the spine: a multi-center study of a novel non-fusion system. *Eur Spine J* 11: 170-178.
 11. Zhang QH, Zhou YL, Petit D, Teo EC (2009) Evaluation of load transfer characteristics of a dynamic stabilization device on disc loading under compression. *Med Eng Phys* 31: 533-538.
 12. Rahm MD, Hall BB (1996) Adjacent-segment degeneration after lumbar fusion with instrumentation: a retrospective study. *J Spinal Disord* 9: 392-400.
 13. Ghiselli G, Wang JC, Bhatia NN, Hsu WK, Dawson EG (2004) Adjacent segment degeneration in the lumbar spine. *J Bone Joint Surg Am* 86-86: 1497-503.
 14. Schmoelz W, Huber JF, Nydegger T, Claes L, Wilke HJ (2006) Influence of a dynamic stabilisation system on load bearing of a bridged disc: an in vitro study of intradiscal pressure. *Eur Spine J* 15: 1276-1285.
 15. Morishita Y, Ohta H, Naito M, Matsumoto Y, Huang G, et al. (2011) Kinematic evaluation of the adjacent segments after lumbar instrumented surgery: a comparison between rigid fusion and dynamic non-fusion stabilization. *Eur Spine J* 20: 1480-1485.
 16. Lutz JA, Otten P, Maestretti G (2012) Late infections after dynamic stabilization of the lumbar spine with Dynesys. *Eur Spine J* 21: 2573-2579.
 17. Zhong ZC, Chen SH, Hung CH (2009) Load- and displacement-controlled finite element analyses on fusion and non-fusion spinal implants. *Proc Inst Mech Eng H* 223: 143-157.
 18. Sapkas G, Mavrogenis AF, Starantzis KA, Soultanis K, Kokkalis ZT, et al. (2012) Outcome of a dynamic neutralization system for the spine. *Orthopedics* 35: 1497-1502.
 19. Schmidt H, Heuer F, Wilke HJ (2009) Which axial and bending stiffnesses of posterior implants are required to design a flexible lumbar stabilization system? *J Biomech* 42: 48-54.