

# Clinical and Immunological Study of 21 Patients after Spermatic Cord Torsion

Youness Chakir\*, Yassine Berni, Amine Moataz, Mohamed Dakir, Adil Debbagh, Rachid Aboutaieb

Department of Urology and Andrology, Sexual Health Laboratory, CHU Ibn Rochd, FMPC, Casablanca Morocco

## ABSTRACT

Spermatic Cord Torsion (SCT) is a urological emergency affecting in most cases adolescents and young adults. It is a rotation of the spermatic cord around its axis. The aim of the study was to investigate the clinical and immunological course of a series of patients operated on for spermatic cord torsion and to discuss the results. All the cases included in the study had a spermatic cord torsion confirmed surgically, and who agreed to have a spermogram and anti-seminal antibody test after three months to one year of surgery. The cases included in this study were adolescent patients aged 14-19 years and young adults (20-40 years) with operated SCT. After 3 months to 1 year, 21 patients were followed by echo Doppler (13 cases) and spermogram with antispermatozoid antibodies (21 cases). Thus, after orchidopexy, the majority of patients operated on within 6 hours had a normal spermogram without the presence of antispermatozoid antibodies. All patients operated after 6 hours had an abnormal spermogram with the presence of anti-sperm antibodies in 3 cases out of 9. The four cases of orchiectomy of the series benefited from a spermogram with search for antispermatozoid antibodies. It was abnormal in 2 cases and two cases had positive antispermatozoid antibodies. We conclude that SCT is a urological emergency that must be operated without delay, because the prognosis of fertility depends on the rapidity of the surgical management.

**Key words:** Spermatic cord torsion; Fertility; Antibodies

## INTRODUCTION

Spermatic Cord Torsion (SCT) is an acute urological emergency affecting in most cases in pubertal boys aged and occurs due to a rotation of the spermatic cord. This can include rotation of the tunica vaginales (extra vaginal torsion), this type happens almost in the perinatal period or solely be the spermatic cord and testis that rotate within the tunica vaginalis (intra vaginal torsion) [1]. The affected testis can be completely removed by performing an orchiectomy or it can be manually untwisted and fixated in the scrotum by doing an orchidopexy. Auto-immune hypothesis: Acute ischemia secondary to torsion of the spermatic cord would be responsible for a break in the hematotesticular barrier, the contralateral testis would suffer through antispermatozoid antibodies [2]. This prospective case series study investigates the impact of SCT on testicular function, immunological response by secretion of the anti spermatozoïde antibodies, and discusses possible damage to the contralateral testis.

## METHODOLOGY

This work is a prospective descriptive study of a series of 21 cases of spermatic cord torsion surgically confirmed and managed at the urology department of the IBN ROCHD University Hospital in Casablanca, over a period that extends from January 2020 to January 2021. All the cases selected for the study had a torsion of the spermatic cord and were all operated on and who agreed to do a spermogram and look for antispermatozoid antibodies after at least three months of surgery.

- The first step was to establish a clinical records operating record.
- The second step was to collect the data for each file
- The third step concerned the analysis of the data in the series under consideration.

**Correspondence to:** Department of Urology and Andrology, Sexual Health Laboratory, CHU Ibn Rochd, FMPC, Casablanca Morocco, E-mail: dr.chakir.youness@gmail.com

**Received:** 10-May-2022, Manuscript No. ANO-22-17425; **Editor assigned:** 13-May-2022, PreQC No. ANO-22-17425(PQ); **Reviewed:** 27-May-2022, QC No. ANO-22-17425; **Revised:** 06-June-2022, Manuscript No. ANO-22-17425(R); **Published:** 13-June-2022, DOI:10.35248/2167-0250.22.11.259

**Citation:** Chakir Y, Berni Y, Moataz A, Dakir M, Debbagh A, Aboutaieb R (2022) Clinical and Immunological Study of 21 Patients after Spermatic Cord Torsion. *Andrology*. 11:259.

**Copyright:** © 2022 Chakir Y, et al. This is an open-access article distributed under the terms of the Creative Commons Attribution License, which permits unrestricted use, distribution, and reproduction in any medium, provided the original author and source are credited.

### Inclusion criteria:

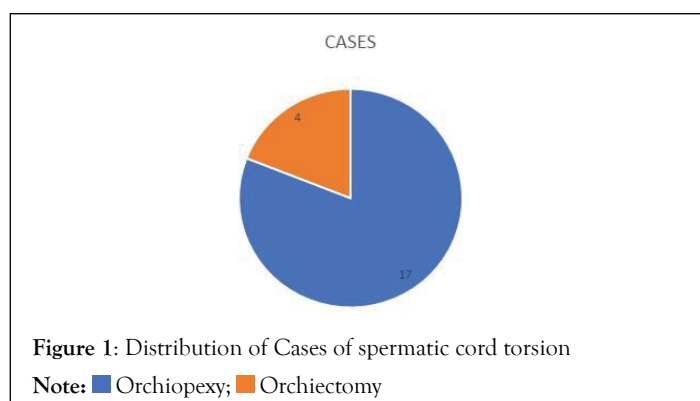
The cases included in this study were adolescent patients aged 14 to 19 years (according to the WHO a teenager is between 10 and 19 years old); as the service only supports patients over the age of 14; and young adults (20-40 years) with a TCS, operated on at the urology department of the Ibn ROCHD University Hospital Center (CHU) in Casablanca and having done a spermogram.

### Exclusion criteria:

- Adolescents under the age of 14.
- Adults over 40 years of age.

## RESULTS

In the urological emergencies of our university hospital, the prevalence of torsion is 6% and an average incidence of 23 cases per year. In our study period, 28 cases of spermatic cord twisting were operated. Four patients refused to follow up with a spermogram, three patients were lost to follow-up. After a setback of 3 months to 1 year, 21 patients were followed by Doppler echo (13 cases) and spermogram with anti-sperm antibody testing (21 cases). Indeed, 17



cases were treated with orchidopexy and 4 cases with orchiectomy (Figure 1).

### Orchidopexy

The average age of cases treated with orchidopexy (17 cases) was 17 years. The average time to surgical exploration in cases treated with orchidopexy was 9 hours (extremes 2 hours and 25 hours).

### Clinical follow-up

Three cases (19%) had moderate residual scrotal pain in the twisted testicle. Pain and discomfort when walking were reported in one case.

### Scrotal ultrasound with follow-up doppler

It was performed in 9 cases in patients operated on within less than 6 hours (5 cases) and more than 6 hours (4 cases).

### Size

- The contralateral testicle served as a control. Atrophy of the twisted testicle was found in 3 cases (33%) among patients with a delay of more than 6 hours. (n°13, n°15, n°17) (Table 1).
- The other six cases had normal-sized testicles (#2, #3, #6, #7, #8, #9) (Table 1).

### Echo structure

All testicles were homogeneous on scrotal ultrasound.

### Vascularization

Doppler showed normal blood flow in all cases, even in the atrophied testicles.

**Table 1:** Results of the Spermogram gram in case of SCT after orchidopexy cases.

No	Age	Side	T.S	Delay	Aspect	Gesture	Sperm gram	Anti-sperm AB
1	16	D	2	2 hours	Purple	Orchidopexy	Asthenospermia	-
2	21	D	1	3 hours	Pinkish	Orchidopexy	Oligozoospermia	-
3	17	D	1	3 hours	Pinkish	Orchidopexy	Normospermia	-
4	18	G	2	3 hours	Pinkish	Orchidopexy	Normospermia	-
5	15	G	2	4 hours	Purple	Orchidopexy	Normospermia	-
6	15	G	2	5 hours	Purple	Orchidopexy	Normospermia	-
7	15	G	2	6 hours	Purple	Orchidopexy	Normospermia	-
8	16	G	2	6 hours	Purple	Orchidopexy	Teratospermia	-
9	18	G	2	8 hours	Purple	Orchidopexy	Asthenospermia	-
10	17	D	1	9 hours	Purple	Orchidopexy	Oligozoo-asthenospermia	-
11	15	D	1	10 hours	Purple	Orchidopexy	Asthenospermia	-
12	20	G	2	10 hours	Purple	Orchidopexy	Azoospermia	+
13	22	G	1	11 hours	Purple	Orchidopexy	Azoospermia	+
14	20	D	1	11 hours	Purple	Orchidopexy	Asthenospermia	+
15	19	G	1	2 hours	Purple	Orchidopexy	Oligozoospermia	-
16	16	D	1	24hours	Pinkish	Orchidopexy	Oligo-asthenospermia- hypospermia	-
17	14	G	1	3 hours	Pinkish	Orchidopexy	Asthenospermia	-

**Note:** T.S: Turns of spermatic cord

**Table 2:** Results of the sperm gram in case of SCT after orchiectomy.

No	Age	Side	T.S	Delay	Aspect	Gesture	Sperm gram	Anti-sperm AB
1	19	D	1	12 hours	Blackish	Orchiectomy	Normospermia	-
2	15	G	2	12 hours	Blackish	Orchiectomy	Normospermia	+
3	17	G	1	8 hours	Blackish	Orchiectomy	Oligozoo-asthenospermia	-
4	16	G	1	24 hours	Blackish	Orchiectomy	Oligozoo-hypospermia	+

Note: T.S: Turns of spermatic cord

## Spermogram

**Quality:** The results of the semen analysis are presented in Table 1. An abnormal spermogram was found in 12 out of 17 cases (71%).

## Anti-sperm antibodies

The analysis to look for antibody activity against sperm antigens revealed (Table 1).

- Anti-sperm negative AC research: 14 cases
- Anti-sperm positive AC research: 3 cases (n°12, n°13, n°14). The surgical exploration time was more than 10 hours in all 3 cases.

Thus, after orchidopexy, the majority of patients operated within less than 6 hours had a normal spermogram without the presence of anti spermatozoid antibodies. All patients operated after 6 hours had an abnormal spermogram with the presence of anti spermatozoid antibodies in 3 out of 9 cases.

## Orchiectomy

The average age of cases treated with orchiectomy (4 cases) was 16 years. The average surgical exploration time was 17 hours (extremes 12 hours and 24 hours).

## Clinical

On clinical examination palpation finds a contralateral testicle enlarged in 3 cases.

## Scrotal ultrasound

It was carried out in 4 cases. It showed compensatory hypertrophy on the contralateral side in all cases.

## Spermogram

All four cases benefited from a spermogram with a search for antispermatozoid antibodies. It was abnormal in 2 cases and two cases had positive antispermatozoid antibodies (Table 2).

## DISCUSSION

In our context the torsion of the spermatic cord is a frequent surgical emergency, the management is a little late for many reasons: The lack of knowledge of the diagnosis by the primary care doctors or the geographical distance of the patient from an adapted care structure. In our series, after orchidopexy (n=17), the majority of patients operated within less than 6 hours had a normal spermogram without the presence of antispermatozoid antibodies. All patients operated after a period of 6 hours had an abnormal spermogram with the presence of antispermatozoid antibodies in

3 out of 9 cases. Fertility prognosis is studied in the literature and the role of antispermatozoid antibodies is not fully elucidated. But sperm antibodies secreted after the blood barrier is altered after testicular trauma or a twisting episode are thought to be harmful to a man's fertility. However, one study suggests that ASAs are not associated with sperm DNA damage and that ASAs are unlikely to have a direct or indirect significant effect on sperm DNA integrity [3]. Also the presence of anti-sperm CAs does not influence the success of Assisted Reproduction Techniques (ART) [4]. The animal study showed in an experiment that antispermatozoid antibodies appear after testicular torsion. The vast majority of these antibodies disappeared after a certain period of time and they are located on the tail without obvious explanations [5]. Another study in rats shows that an immunological mechanism (IgG) by fixation in the contralateral testicle after one month of a torsion episode may be responsible for impaired testicular function [6]. Another experimental study in animals shows that IgG deposited on the basement membrane of seminiferous tubules appears to be involved in the genesis of testicular lesions [7]. It is therefore proposed that the same phenomena probably exist in humans. But in many men without a history of trauma or testicular torsion, seminal antibodies can be found, and even in fertile men. An ancient series of 25 torsions concludes that sterility is consistent with the number of years after testicular torsion and the existence of testicular atrophy and is correlated with an immunological mechanism [8]. Other authors propose that the results of their series confirm poor gonadal function after torsion, but do not support the recent suggestion that it is caused by autoimmunization [9]. A series of fifty-five patients concludes that torsion is associated in many cases with bilateral testicular dysplasia of the germinative epithelium in spermatoblasts. Disruption of spermatogenesis after unilateral twisting occurs in 50%-60% of patients, while anti-sperm antibodies have no importance with regard to lesions of the germinal epithelium. Pre-existing dysplasia of the germinal epithelium may be the cause of this disturbance [10]. A systematic review of the literature and meta-analysis, finds that there was a significant negative effect of ASA on sperm concentration, sperm motility (a+b) and sperm liquefaction [11]. Another review of the literature concludes that hypoxia of testicular torsion induces oxidative stress. The endocrine function of the testicles appears to be unchanged in the majority of series while sperm quality is more frequently affected. However, the impact on fertility assessed by paternity rates in a series after TT remains normal compared to the general population, further studies should confirm this finding. Contralateral histological testicular lesions have been demonstrated in several human series and in rats. The role of antispermatozoid antibodies remains uncertain. Many studies do not show an elevation of ASA after torsion [12]. Our series suggests that timely management of TCS can prevent the formation of ASA,

and also avoid subsequent testicular atrophy or infertility. Parents and emergency doctors must be made aware of the value of urgent care in the operating room.

## CONCLUSION

After an episode of torsion of the spermatic cord, the young adult or the teenager often accompanied by his parents asks the question on the prognosis of the fertility in the future. In our context patients also ask about erectile dysfunction and "virility" problems. In the absence of large randomized series studying long-term prognosis and in the absence long-term therapeutic trial, we do not give our patients an exhaustive answer. According to published studies, many men who had SCT in childhood have been able to give birth to a live child. What we remember in our study is that patients should be operated on as soon as possible, especially before six hours to avoid the formation of antiserum antibodies and subsequent disturbances of the sperm gram. We need to do other series that follow our patients over the long term to properly study the future of fertility in these patients and also respond to the interest of antioxidants, corticosteroids or even immunotherapy as a treatment that preserves fertility after an episode of testicular torsion.

## AUTHOR CONTRIBUTIONS

Y.C et Y.B : did the bibliographic and field research.

A.M, M.D, A.D, R.A supervise the study and have corrected the manuscript.

## COMPETING INTERESTS

All authors declare no competing interests.

## ACKNOWLEDGMENTS

None.

## REFERENCES

1. Audenet F. Torsion du cordon spermatique et des annexes testiculaires : physiopathologie, diagnostic et principes du traitement. *EMC*. 2012;5(2):1-7.
2. Mongiat-Artus P. Torsion du cordon spermatique et des annexes testiculaires. *EMC*. 2008;1(1):1-7.
3. Zini A, Phillips S, Lefebvre J, Baazeem A, Bissonnette F, Kadoch IJ, et al. Anti-sperm antibodies are not associated with sperm DNA damage: a prospective study of infertile men. *J Reprod Immunol*. 2010;85(2):205-208.
4. Zini A, Lefebvre J, Kornitzer G, Bissonnette F, Kadoch IJ, Dean N, et al. Anti-sperm antibody levels are not related to fertilization or pregnancy rates after IVF or IVF/ICSI. *J Reprod Immunol*. 2011;88(1):80-84.
5. Merimsky E, Orni-Wasserlauf R, Yust I. Assessment of immunological mechanism in infertility of the rat after experimental testicular torsion. *Urol Res*.1984;12(3).
6. Koşar A, Küpeli B, Alçığır G, Ataoglu H, Sarıca K, Küpeli S. Immunologic Aspect of Testicular Torsion: Detection of Antisperm Antibodies in Contralateral Testicle. *European Urology*. 1999;36(6):640-644.
7. Schanaider A, Aiex C, Errico G. Immunological Effects of Acute Testicular Torsion on the Contralateral Testis in Rats. *Eur J Pediatr Surg*. 2011;21(06):370-374.
8. Mastrogiacomo I, Zanchetta R, Graziotti P, Betterle C, Scruferi P, Lembo A. Immunological and Clinical Study in Patients after Spermatic Cord Torsion. *Andrologia*. 2009;14(1):25-30.
9. Fraser I, Slater N, Tate C, Smart JG. Testicular torsion does not cause autoimmunization in man. *Br J Surg*. 1985;72(3):237-238.
10. Hagen P, Buchholz MM, Eigenmann J, Bandhauer K. Testicular Dysplasia Causing Disturbance of Spermiogenesis in Patients with Unilateral Torsion of the Testis. *Urol Int*. 1992;49(3):154-157.
11. Cui D, Han G, Shang Y, Liu C, Xia L, Li L, et al. Antisperm antibodies in infertile men and their effect on semen parameters: A systematic review and meta-analysis. *Clinica Chimica Acta*.2015;444:29-36.
12. Jacobsen FM, Rudlang TM, Fode M, Østergren PB, Sønksen J, Ohl DA, et al. The Impact of Testicular Torsion on Testicular Function. *World J Mens Health*. 2019;37:e20.