

## Clavicular Fracture in a Newborn

Zahouani Tarik\* and Rajegowda Benamanahalli

Department of Pediatrics, Lincoln Medical and Mental Health Center, USA

\*Corresponding author: Zahouani Tarik, Department of Pediatrics, Lincoln Medical and Mental Health Center, USA, Tel: 718-579-5030; E-mail: [Tarikzahouani@gmail.com](mailto:Tarikzahouani@gmail.com)

Received date: November 20, 2016; Accepted date: November 25, 2016; Published date: December 05, 2016

Copyright: © 2016 Tarik Z, et al. This is an open-access article distributed under the terms of the Creative Commons Attribution License, which permits unrestricted use, distribution and reproduction in any medium, provided the original author and source are credited.

### Clinical Image Description

A baby boy was born at 40 weeks of gestation via vaginal delivery to a 36 y/o whose prenatal course was unremarkable. The Apgar score was 9 at the 1st and 5th minutes. The infant was large for gestational age with a birth weight of 4160 g. The head circumference was 33 cm, chest circumference 32 cm, abdominal circumference 31 cm and length 53 cm. On physical examination, we noted that the right arm was not moving as well as the left arm with poor motor reflex and a slight fullness over the right clavicular fossa but no crepitus. An X-ray was performed showing a displaced fracture of right distal clavicle (Figure 1).

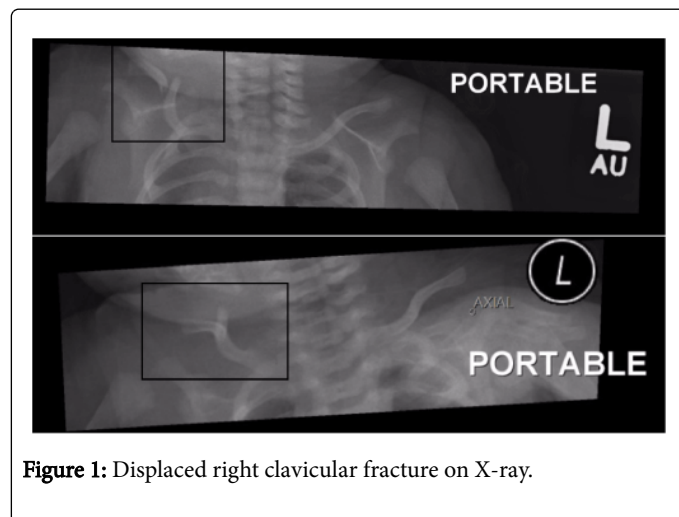


Figure 1: Displaced right clavicular fracture on X-ray.

Clavicular fracture is the most common fracture in neonate with an incidence ranging between 0.5 to 1.6% [1]. Risk factors include breech delivery, shoulder dystocia, increased birth weight (>4 kg), instrumental delivery and use of oxytocin [1]. The diagnosis of nondisplaced clavicular fractures is often delayed even with the careful examination of the baby in the nursery, as they are clinically silent until the formation of a palpable callous most commonly noticed in the follow up visit in the clinic [2]. At that time, it creates a parental anguish and such situation can become a medicolegal case. Displaced clavicular fracture, as in our case, presents soon after birth with decreased movement of the affected extremity, edema, asymmetrical bone contour, tenderness, crepitus and crying with passive motion [2]. Radiography confirms the diagnosis. Management is conservative with observation, clinical and radiographic follow up [1,2]. The prognosis is excellent and complications such as Erb palsy and brachial plexus injury are rare and have to be ruled out. Generally when they occur there is a complete and spontaneous recovery [2]. Each case has to be reviewed with the obstetrics team to improve the practice and to prevent similar injuries.

### References

1. Lam MH, Wong GY, Lao TT (2002) Reappraisal of neonatal clavicular fracture: relationship between infant size and neonatal morbidity. *Obstet Gynecol* 100: 115-119.
2. Kanik A, Sutcuoglu S, Aydinlioglu H, Erdemir A, Arun Ozer E (2011) Bilateral clavicle fracture in two newborn infants. *Iran J Pediatr* 21: 553-555.