

Classification of Anatomic Variations in the Left Gastric Vein during Laparoscopic Gastrectomy

Wang Y, Huang CM*, Zheng CH, Li P, Xie JW, Wang JB, Lin JX and Lu J

Department of Gastric Surgery, Fujian Medical University Union Hospital, No.29 Xinquan Road, Fuzhou 350001, Fujian Province, China

Abstract

Background: The left gastric vein (LGV) is an important blood vessel requiring dissection during gastric surgery. Since the drainage patterns of the LGV vary, it is easily injured, and bleeding from the LGV may be difficult to control. This study therefore analyzed anatomic variations in the LGV observed during laparoscopic gastrectomy.

Methods: LGV drainage patterns were analyzed relative to intraoperative vascular anatomy in 1325 patients with gastric cancer who underwent radical resection from May 2007 to June 2012. The rates of occurrence of these anatomic variants were determined, and lymph node dissection and surgical outcomes were described.

Results: The location of the LGV was identified during laparoscopic gastrectomy in all 1325 patients. The LGV passed to the ventral side of the splenic artery (SpA) and common hepatic artery (CHA) in 743 patients (56.1%, type 1); the dorsal side of the CHA in 550 patients (41.5%, type 2); the dorsal side of the SpA in 4 patients (0.3%, type 3); and along the hepatogastric ligament, draining directly into the liver, in 21 patients (1.6%, type 4). In 7 patients (0.5%), the LGV was absent, and the right gastric vein was enlarged (type 5). The mean number of suprapancreatic LNs (Nos. 7-9) retrieved from all patients was 7.99 ± 3.89 , and the mean number of LN metastases was 1.17 ± 2.11 . Comparison of findings during the first part of the study period with later in the study period, when surgeons were more experienced, showed that operation time ($P < 0.05$) and intraoperative blood loss ($P < 0.05$) were significantly lower in the later period.

Conclusions: The LGV in most patients runs across the ventral side of the SpA and CHA, or along the dorsal side of the CHA. Knowledge of different anatomic variations will help avoid damage to the LGV during laparoscopic gastrectomy.

Keywords: Left gastric vein; Anatomic variant; Laparoscopic gastrectomy

Introduction

The left gastric vein (LGV), formerly called the gastric coronary vein, is an important tributary of the portal system. It runs along the lesser curvature of the stomach, descends along the gastropancreatic fold, and drains into the portal vein (PV) and splenic vein (SpV). Accidental injury to the LGV is often due to its various patterns of inflow and route relative to the surrounding arteries. Because the LGV and mesenteric vein flow into the PV and SpV, which are major blood vessels, injury to the LGV can lead to heavy blood loss and difficulty in maintaining hemostasis, even during open gastrectomy.

Laparoscopic surgery for gastric cancer is as oncologically effective as open surgery, while having significant advantages over the latter, including smaller sized surgical incisions, reduced intraoperative bleeding, less postoperative pain, faster recovery of bowel function, shorter hospital stay, faster return to daily activities, and improved quality of life [1-5]. However, the vessels around the stomach are anatomically complicated and have many variations. The LGV requires dissection during gastric surgery, but its drainage patterns vary. The surgeon's intuitive touch and exposure are lacking during laparoscopic surgery, with only the laparoscopic grasping forceps used for traction and separation in the suprapancreatic area. The shape of the blood vessels cannot be determined intuitively, increasing the likelihood of vascular injury and LGV bleeding during lymph node dissection in patients with gastric cancer. This can affect the patient's circulation and ability to undergo subsequent surgery. Therefore, it is important to determine the anatomic variations of the LGV. This study therefore analyzed anatomic variations in the LGV observed in 1325 patients

who underwent laparoscopic radical resection for gastric cancer.

Materials and Methods

Patients

Beginning in May 2007, the Department of Gastric Surgery of the Affiliated Union Hospital of Fujian Medical University established a video database of laparoscopic gastrectomy. By June 2012, the video database included data on 1325 patients who had undergone laparoscopic radical resection for gastric cancer. The LGV of these patients was anatomically exposed during lymph node dissection. This study compared operation time and intraoperative blood loss in patients who underwent laparoscopic assisted gastrectomy (LAG): (1) between May 2007 and December 2009, the initial period of LAG, and (2) between January 2010 and June 2012, during which surgeons were more experienced with LAG.

***Corresponding author:** Chang-Ming Huang, Professor, Department of Gastric Surgery, Fujian Medical University Union Hospital, No. 29 Xinquan Road, Fuzhou 350001 Fujian Province, China, E-mail: hcmr2002@163.com

Received October 30, 2013; **Accepted** November 23, 2013; **Published** November 25, 2013

Citation: Wang Y, Huang CM, Zheng CH, Li P, Xie JW, et al. (2013) Classification of Anatomic Variations in the Left Gastric Vein during Laparoscopic Gastrectomy. *Anat Physiol* 3: 127. doi:10.4172/2161-0940.1000127

Copyright: © 2013 Wang Y, et al. This is an open-access article distributed under the terms of the Creative Commons Attribution License, which permits unrestricted use, distribution, and reproduction in any medium, provided the original author and source are credited.

Surgical procedures

The assistant initially held and tensed the gastropancreatic fold and turned the stomach up. Subsequently, the surgeon gently pressed down the pancreas, exposing its superior border and, using an ultrasonic scalpel, separated the pancreas membrane to reach the posterior pancreas space. The anatomic space at the surface of the SpA was separated from left to right to reach the root of the SpA. From the root of the SpA, the assistant pulled up the lymphatic fatty tissue, which was dissected, and used an ultrasonic scalpel to separate the anatomic space at the surface of the artery. The lymphatic fatty tissue along the celiac artery was dissected, and the roots of the LGA and LGV were exposed. Finally, the surgeon dissected the lymphatic fatty tissue around the LGA and LGV using an ultrasonic scalpel, and skeletonized and cut the LGA and LGV at the superior border of the CHA or SpA. All operations were undertaken with the goal of curative resection (R0), along with D2 LN dissection according to the Japanese Classification of Gastric Carcinoma, third edition (JCGC3) [6]. The surgical processes and vascular anatomy were documented in all patients using the surgical video and high definition images. Written informed consent was obtained from all patients for publication of this report and any accompanying images, and the study was approved by our institutional review board.

Statistical analysis

Student's t-tests were used to evaluate continuous variables. Probability (p) values <0.05 were regarded as statistically significant.

Results

Normal location of the LGV in relation to the perigastric arteries

The location of the LGV was identified during laparoscopic gastrectomy in all 1325 cases, and its location in relation to the perigastric arteries is summarized in Table 1. The LGV passed to the ventral side of the splenic artery (SpA) and common hepatic artery (CHA) in 743 patients (56.1%, type 1; Figure 1), and to the dorsal side of the CHA in 550 patients (41.5%, type 2; Figure 2).

Rare locations of the LGV in relation to the perigastric arteries

In four patients (0.3%, type 3), the LGV ran across the dorsal side of the SpA and drained into the splenic vein (Figure 3), a drainage pattern differing from that of normal LGVs. In patients with this variant, small blood vessels from the anterior and posterior walls of the lesser curvature of the stomach drained into the LGV. The LGV lay close to the LGA in the high part of the lesser curvature, descended along the gastropancreatic fold, ran across the dorsal side of the SpA and drained into the splenic vein.

Aberrant locations of the LGV in relation to the perigastric arteries

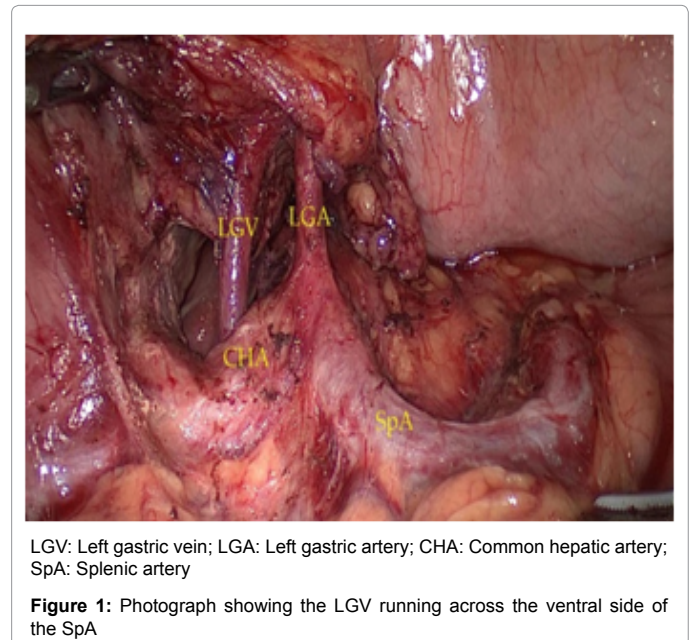
We observed two patterns of aberrantly located LGVs in relation to the perigastric arteries. In one type, also known as the intrahepatic type and observed in 21 patients (1.6%), the LGV ran along the hepatogastric ligament and drained directly into the liver (Figure 4). In addition, no LGV was detected in the plica gastropancreatica and hepatogastric ligament of 7 patients (0.5%, type 5); in these patients, the right gastric vein was enlarged to compensate for the absence of the LGV (Figure 5).

LN dissection

The mean number of suprapancreatic LNs (Nos. 7-9) retrieved from all patients was 7.99 ± 3.89 , and the mean number of LN metastases was 1.17 ± 2.11 . The mean numbers of retrieved and metastatic suprapancreatic LNs in patients with types 1-5 LGV are shown in Table 2.

Surgical outcomes

The mean operation time in all 1325 patients was 227.13 ± 49.13 min, and the mean intraoperative blood loss was 141.53 ± 74.94 ml. The mean operation time was significantly shorter (164.03 ± 35.05 min vs. 222.41 ± 60.13 min, $P < 0.05$) and the mean intraoperative blood loss significantly lower (62.07 ± 63.52 ml vs. 80.95 ± 102.21 ml, $P = P < 0.05$) in patients who underwent surgery between January 2010 and June 2012 than between May 2007 and December 2009, suggesting better patient outcomes after surgeons had more experience with laparoscopic gastrectomy.



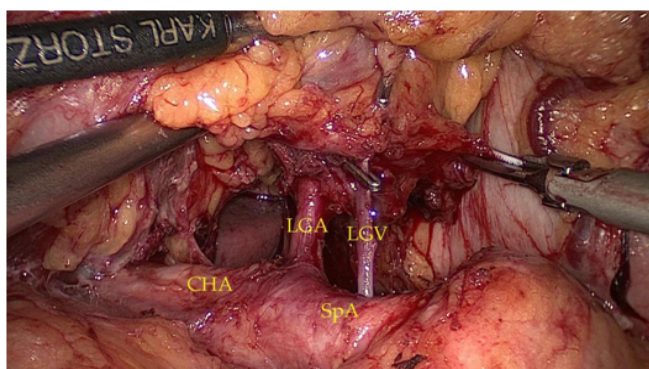
Author/Site	Ventral side of the SpA	Ventral side of the CHA	Dorsal side of the CHA	Dorsal side of the SpA	Drains into the liver	Absence	Number of patients
Miyaki et al. [10]					2(0.8%)		245
Lee et al. [21]		21(51.2%)	20(48.8%)				41
Kawasaki et al.[22]	17(21.0%)	18(22.2%)	40(49.4%)	2(2.5%)		2(2.5%)	81
Natsume et al. [9]	28(22.4%)	42(33.6%)	49(39.2%)	6(4.8%)			125
Miyaki et al. [23]	20(28.2%)	13(18.3%)	30(42.3%)	8(11.3%)			175
Present study	743(56.1%)		550(41.7%)	4(0.3%)	21(1.6%)	7(0.5%)	1325

Table 1: Previous findings on the location of the LGV in relation to the perigastric arteries

	Ventral side of the SpA and CHA	Dorsal side of the CHA	Dorsal side of the SpA	Drains into the liver	Absence
No. of retrieved LNs	7.92 ± 3.86	8.22 ± 3.69	8.50 ± 4.74	8.09 ± 3.23	7.15 ± 3.92
No. of metastatic LNs	1.35 ± 2.32	0.95 ± 1.68	1.50 ± 2.60	1.13 ± 2.30	0.38 ± 1.08
Patients with LN metastases (%)	300(40.38%)	190(34.55%)	1(25.00%)	6(28.57%)	2(28.57%)
No. of No.7 retrieved LNs	3.13 ± 2.10	3.38 ± 2.35	3.70 ± 2.45	3.36 ± 2.19	2.23 ± 1.25
No. of No.8 retrieved LNs	2.27 ± 1.64	2.41 ± 1.91	2.35±2.83	2.64 ± 1.43	2.46 ± 1.45
No. of No.9 retrieved LNs	2.52 ± 1.95	2.43 ± 1.73	2.45±2.06	2.09 ± 0.90	2.46 ± 2.50

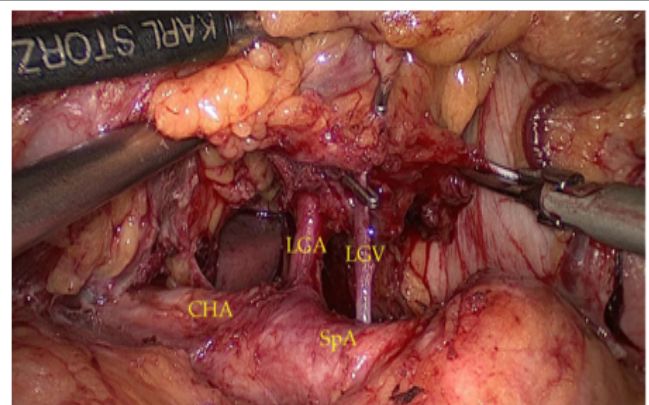
All results reported as mean ± SD, except where indicated.

Table 2: LN dissection results in the 1325 patients who underwent laparoscopic gastrectomy at our institution



LGV: Left gastric vein; LGA: Left gastric artery; CHA: Common hepatic artery; SpA: Splenic artery

Figure 2: Photograph showing the LGV running across the dorsal side of the CHA



LGV: Left gastric vein; LGA: Left gastric artery; CHA: Common hepatic artery; SpA: Splenic artery

Figure 3: Photograph showing the LGV running across the dorsal side of the SpA

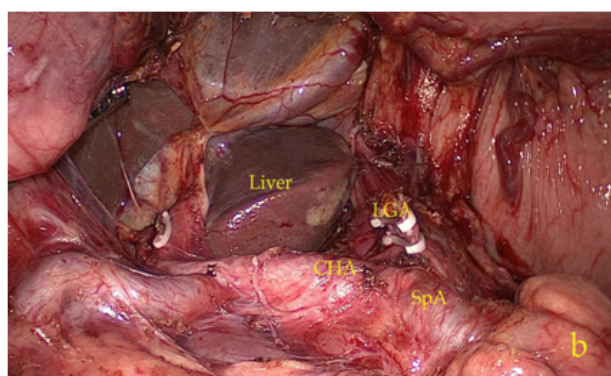
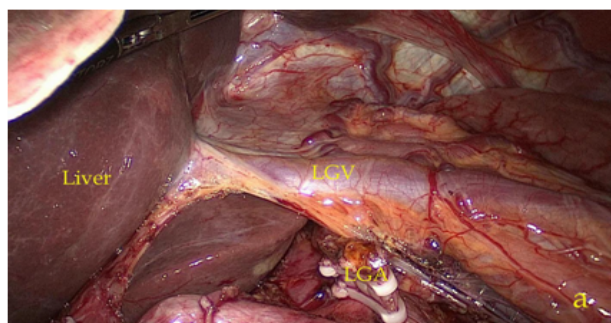
Discussion

The LGV is one of the most important blood vessels requiring dissection during gastric surgery. Thus, alterations in LGV drainage patterns can affect surgical processes [7,8]. Knowledge of the anatomical features of the LGV is therefore required to avoid accidental dissection of the vessel. In most individuals, the LGV starts from small branches of the anterior and posterior walls of the stomach, collects blood vessels from the lesser curvature of the stomach, and descends along the gastropancreatic fold. The drainage patterns of the LGV can vary. For example, evaluation of abdominal CT scans in 125 patients showed that, in 49 (39.2%), the LGV ran across the dorsal side of the

CHA, whereas, in 28 (22.4%), it ran across the ventral side of the SpA [9]. In 2 of 245 cadavers (0.8%), the LGV entered the liver directly after passing through the hepatogastric ligament [10]. Although there have been several anatomic studies of the LGV [11-15], the reasons for the different drainage patterns remain obscure. Embryologically, the primitive foregut venous plexus (PFVP) courses along the primitive foregut, while the ductus venosus (DV of Arantius) is anastomosed to the PFVP, resulting in the anastomotic omental veins (AOV) [16,17]. During standard development of the PFVP, the AOV gradually disappear, with both the right and left gastric veins ending in the main portal vein (PV). Veins, however, must adapt to changes in the intestinal canal and expansion of the liver, resulting in differences in LGV drainage patterns, probably during the course of evolution. We found that the LGV in most patients ran across the ventral sides of the SpA and CHA, or along the ventral side of the SpA and the dorsal side of the CHA.

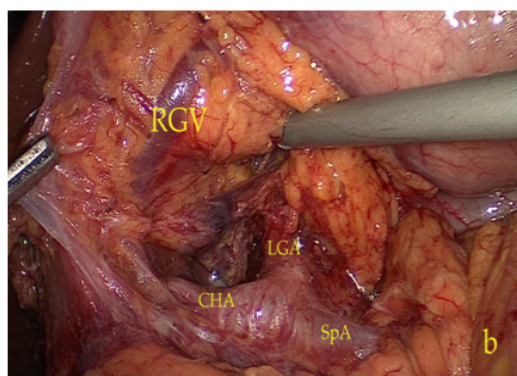
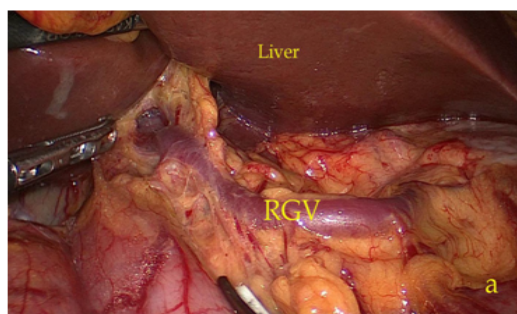
Since the first report of laparoscopic-assisted distal gastrectomy for early gastric cancer in 1994 [18], this method has become widely accepted due to its advantages over conventional open surgery, including smaller surgical incisions, less intraoperative blood loss, reduced pain, shorter hospital stays, and reduced morbidity and mortality rates [19]. The laparoscopic technique, however, still has significant limitations: laparoscopic surgery is generally a two-dimensional type of surgery with losses in depth perception and spatial orientation. In addition, the laparoscopic technique cannot utilize the surgeon's intuitive touch and exposure, and only the laparoscopic grasping forceps can be used for traction and separation in the local area. The inability to manipulate tissue and the limited visibility of the operative field hinder the identification of vessels and procedure-specific anatomical landmarks. Dissection of lymph nodes in the suprapancreatic area is particularly difficult laparoscopically, since the vessels in this area are especially intricate and variable and are covered by much fatty lymphoid tissue. Furthermore, the suprapancreatic area is complex, situated at a deep location and difficult to expose, and the operating space is narrow. Surgery in this area increases operating times and the risks of visceral and vascular injuries, especially in patients with anatomical vascular variations and in obese patients. Intraoperative bleeding, difficulties in identifying the correct anatomy, and limited vision are major causes of conversion to open surgery. Thus, familiarity with anatomical vascular variations in the suprapancreatic area is very important for surgeons.

The LGV, an important blood vessel located in the suprapancreatic area, requires dissection during gastric surgery. This blood vessel is small and fragile and can be easily injured during suprapancreatic lymph node dissection in patients with gastric cancer. Moreover, LGV bleeding may be difficult to control [20,21]. Familiarity with the location of the LGV in relation to the perigastric arteries may benefit these patients. Normally, surgeons operating on the region around the superior border of the pancreas should first identify and cut the LGV in the region at the superior border of the CHA or SpA, then dissect the



LGV: Left gastric vein; LGA: Left gastric artery; CHA: Common hepatic artery; SpA: Splenic artery

Figure 4: Photographs showing the LGV running along the hepatogastric ligament and draining directly into the liver (a) Anterior view; (b) Posterior view



RGV: Rightgastric vein; LGA: Left gastric artery; CHA: Common hepatic artery; SpA: Splenic artery

Figure 5: Photographs showing absence of the LGV with compensatory enlargement of the right gastvein (a) anteriorview;(b) posterior view

lymph nodes. Injury to the LGV during laparoscopic gastrectomy will result in bleeding and an unclear operative field, which may be difficult to control and may increase the difficulty of lymph node dissection. This may affect the operation procedure, prolong the operation time and increase the complication rate. If the bleeding is improperly handled, it may result in incomplete lymph node dissection, leaving residual cancer cells in metastatic lymph nodes and resulting in a postoperative decrease in lymph node metastasis rate, thus affecting the characteristics and completeness of oncological resection. In obese patients and in patients with enlarged lymph nodes at the superior border of the pancreas, exposure of the LGV may be more difficult due to increased amounts of lymphatic fatty tissue surrounding the LGV, thus increasing the likelihood of damaging the LGV. Care should be taken to identify anatomic variations in patients undergoing laparoscopic gastrectomy, and to carefully dissect lymphatic fatty tissue at the superior border of the pancreas. We found that increased experience with laparoscopic gastrectomy significantly reduced operation time ($P < 0.05$) and intraoperative blood loss ($P < 0.05$), suggesting that increased knowledge of LGV anatomy prior to surgery increases the confidence of surgeons in operating around the LGV and that surgical skill is required for laparoscopic LN dissection in the suprapancreatic area.

In summary, we have described five anatomic variants of the LGV. In most patients, this vein runs across the dorsal side of the CHA and the ventral side of the SpA. Knowledge of LGV variants may help avoid damage to this vessel during laparoscopic gastrectomy.

Author Disclosures

Drs. Yi Wang, Chang-Ming Huang, Chao-Hui Zheng, Ping Li, Jian-Wei Xie, Jia-Bin Wang, Jian-Xian Lin and Jun Lu have no conflicts of interest or financial ties to disclose.

Author Contributions

Yi Wang, Chang-Ming Huang and Chao-Hui Zheng conceived of the study, analyzed the data, and drafted the manuscript; Chao -Hui Zheng helped revise the manuscript critically for important intellectual content; Ping Li, Jian-Wei Xie, Jia-Bin Wang, Jian-Xian Lin, and Jun Lu helped collect data and design the study. All authors read and approved the final manuscript.

References

1. Lee J, Kim W (2009) Long-term outcomes after laparoscopy assisted gastrectomy for advanced gastric cancer: analysis of consecutive 106 experiences. *J Surg Oncol* 100: 693-698.
2. Uyama I, Sugioka A, Fujita J, Komori Y, Matsui H, et al. (1999) Laparoscopic total gastrectomy with distal pancreatectomy and D2 lymphadenectomy for advanced gastric cancer. *Gastric Cancer* 2: 230-234.
3. Shuang J, Qi S, Zheng J, Zhao Q, Li J, et al. (2011) A case-control study of laparoscopy-assisted and open distal gastrectomy for advanced gastric cancer. *J Gastrointest Surg* 15: 57-62.
4. Moon-Soo Lee, Ju-Hee Lee, Do Joong Park, Lee HJ, Kim HH, et al. (2013) Comparison of short- and long-term outcomes of laparoscopic assisted total gastrectomy and open total gastrectomy in gastric cancer patients. *Surg Endosc* 27: 2598-2605.
5. Ju-Hee Lee, Sang-Hoon Ahn, Do Joong Park, Kim HH, Lee HJ, et al. (2012) Laparoscopic Total Gastrectomy with D2 Lymphadenectomy for Advanced Gastric Cancer. *World J Surg* 36: 2394-2399.
6. Japanese Gastric Cancer Association (2011) Japanese gastric cancer treatment guidelines 2010(ver.3). *Gastric Cancer* 14: 113-123.
7. Matsuki M, Kani H, Tatsugami F, Yoshikawa S, Narabayashi I, et al. (2004) Preoperative assessment of vascular anatomy around the stomach by

- 3D imaging using MDCT before laparoscopy-assisted gastrectomy. *Am J Roentgenol* 183: 145-151.
8. Takiguchi S, Sekimoto M, Fujiwara Y, Yasuda T, Yano M, et al. (2004) Laparoscopic lymph node dissection for gastric cancer with intraoperative navigation using three-dimensional angio computed tomography images reconstructed as laparoscopic view. *Surg Endosc* 18: 106-110.
 9. Natsume T, Shuto K, Kohno T (2010) Anatomic Variations of the Celiac Trunk and the Left Gastric Vein Assessing by Dual-Phase CT Angiography for Safety Laparoscopic Gastrectomy. *J Surg Res* 158: 387-388.
 10. Miyaki T, Yamada M, Kumaki K (1987) Aberrant course of the left gastric vein in the human: possibility of a persistent left portal vein. *Acta Anat* 130: 275-279.
 11. Roi DJ (1993) Ultrasound anatomy of the left gastric vein. *Clin Radiol* 47: 396-398.
 12. Shoichi Matsutani, Hideaki Mizumoto (2012) To-and-fro waveforms in the left gastric vein in portal hypertension. *J Med Ultrasonics* 39: 101-104.
 13. Bergman RA, Thompson SA, Afifi AK (1988) *Compendium of Human Anatomic Variations*. Baltimore, Urban & Schwarzenberg.
 14. Douglass BE, Baggenstoss AH, Hollinshead WH (1950) The anatomy of the portal vein and its tributaries. *Surg Gynecol Obstet* 91: 562-576.
 15. Hiwatashi A, Yoshimitsu K, Honda H, Kuroiwa T, Irie H, et al. (1999) Pseudolesion in segment II of the liver observed on CT during arterial portography caused by the aberrant left gastric venous drainage. *Abdom Imaging* 24: 357-359.
 16. Broman I (1903) über die Existenz eines bisher unbekanntes Kreislaufes im embryonalen Magen. *Ann Anz* 23: 390-391.
 17. Nebot-Cegarra J, Domenech-Mateu JM (1984) Ontogenetic study of the hepatogastroesophageal anastomotic omental veins. *Acta Anat (Basel)* 119: 210-216.
 18. Kitano S, Iso Y, Moriyama M, Sugimachi K (1994) Laparoscopy assisted Billroth I gastrectomy. *Surg Laparosc Endosc* 4: 146-148.
 19. Kim MC, Jung GJ, Kim HH (2007) Morbidity and mortality of laparoscopy-assisted gastrectomy with extraperigastric lymph node dissection for gastric cancer. *Dig Dis Sci* 52: 543-548.
 20. Ibukuro K, Tsukiyama T, Mori K, Inoue Y (1996) Peripancreatic veins on thin-section (3 mm) helical CT. *Am J Roentgenol* 167: 1003-1008.
 21. Lee SW, Shinohara H, Matsuki M, Okuda J, Nomura E, et al. (2003) Preoperative simulation of vascular anatomy by three-dimensional computed tomography imaging in laparoscopic gastric cancer surgery. *J Am Coll Surg* 197: 927-936.
 22. Kawasaki K, Kanaji S, Kobayashi I, Fujita T, Kominami H, et al. (2010) Multidetector computed tomography for preoperative identification of left gastric vein location in patients with gastric cancer. *Gastric cancer* 13: 25-29.
 23. Miyaki A, Imamura K, Kobayashi R, Takami M, Matsumoto J, et al. (2012) Preoperative assessment of perigastric vascular anatomy by multidetector computed tomography angiogram for laparoscopy-assisted gastrectomy. *Langenbecks Arch Surg* 397: 945-950.