

## Cervical Ectopic Pregnancy: A Challenge

Israel Quiroz-Pizar<sup>1</sup>, Rogelio Suárez Yepiz<sup>2</sup>, Donovan Casas-Patiño<sup>3\*</sup>, Alejandra Rodríguez-Torres<sup>4</sup> and Cuauhtémoc Galeana-Castillo<sup>5</sup>

<sup>1</sup>Radiology Department, Unit of Family Medicine number 195, Instituto Mexicano del Seguro Social, Mexico

<sup>2</sup>Obstetrician, Instituto Mexicano del Seguro Social HGR 1, Mexico

<sup>3</sup>Professor of Health Education UAEM/UAP-Nezahualcoyotl and CU-Amecameca, Family Physician, Unit of Family Medicine number 181 Valle de Chalco, Instituto Mexicano del Seguro Social, Mexico

<sup>4</sup>Family Physician, Sonographer, Unit of Family Medicine number 195 Chalco. Instituto Mexicano del Seguro Social. Instituto Mexicano de diagnóstico por Imagen, IMDI, Mexico

<sup>5</sup>Obstetrician, Sonographer, Hospital General Amecameca, IMDI, Mexico

### Abstract

Cervical ectopic pregnancy is extremely rare, however, complications due to lack of early diagnosis compromises the patient's life.

This is the presentation of a case initiated with an abortion and culminated in a radical surgical treatment which required cervical ectopic pregnancy. It emphasizes the initial ultrasound findings which were confounding factors for initial diagnosis and definitive treatment.

**Keywords:** Ectopic pregnancy; Cervical pregnancy; Hysterectomy; Ultrasound; Pregnancy complications

### Introduction

Fortunately cervical pregnancy is the rarest form of ectopic pregnancy. The reports of their frequency are highly variable, ranging from one in 2,550 to one in 18,000 and other reports described one in 95,000 pregnancies. Cervical pregnancy is less than 1% of all ectopic pregnancies [1-5]. Some of the risk factors are: endometrial lesions due to previous cesarean scars, curettage or chronic infections, or the use of intrauterine devices, and more recently the use of techniques of assisted fertilization and embryo transfer [1-6].

Early diagnosis has helped to provide conservative management and reduce morbidity and mortality [3], otherwise the delay in the diagnosis will cause a hemodynamic compromise that may require hysterectomy by up to 50% of cases [6-8].

The diagnosis of cervical pregnancy may be provided by clinical data. In the early weeks of pregnancy, it is usually presented as transvaginal bleeding, resembling fresh blood and with a constant lower abdominal pain, not cramping, which is characteristic of threatened abortion. During the physical examination it is usually found that the external cervix Os is closed and the cervix is enlarged and painful when moved. Nevertheless, this information is not specific [1,4,6].

The ultrasound, preferably endovaginal, is the resource that shows the characteristic findings of cervical pregnancy: the uterine cavity is empty with the gestational sac in the Os which dilate it and eventually also to the inner hole of the cervical neck [1,2]. Furthermore, the use of Doppler color, enables the distinction between viable cervical ectopic pregnancy or abortion remains due to the difference of blood presence between them [4,6,7].

Kobayashi in 1969 established the criteria for cervical pregnancy: intrauterine echo-structures poorly demarcated or diffuse, enlarged uterus, no intrauterine pregnancy and distended cervix [3-14].

Ushakov, meanwhile, established a classification of ultrasonographics criteria of cervical pregnancy [15].

1. Gestational sac in the endocervix.
2. Presence of an intact portion of the gestational sac between the channel and the internal cervical Os.

3. Invasion of trophoblastic tissue in the endocervix
4. Visualization of embryonic or fetal structures in ectopic gestational sac with cardiac activity.
5. Empty uterine cavity.
6. Endometrial Desidualizacion.
7. Hourglass-shaped uterus.
8. Presence of arterial flow in the peritrophoblastic tissue showed by Doppler color.

Differential diagnoses include: incomplete abortion, complete or inevitable, cervical tumors, uterine tumors, degenerated cervical leiomyoma, trophoblastic tumor or placenta previa [9,16-20].

The diagnosis and treatment of this condition have changed significantly since 15 years ago. Early diagnosis is performed by vaginal ultrasonography during the treatment. We can say that there are reports about the use of methotrexate which has been used locally or systemically [5], as well as flat bottom probes and cervix cerclage [10,12]. Other procedures are the embolization by angiography of the cervical arteries [11-14] or injection of methotrexate and potassium chloride sonographically guided [6,14,16] or cervix cerclage [8]. Thanks to these conservative treatments hysterectomy incidence of cervical pregnancy decreased from 89 to 21% in the last years. [16,19-21]

### Case Report

This 34-year-old female pregnant for the third time with two

**\*Corresponding author:** Donovan Casas-Patiño, Professor of Health Education UAEM/UAP-Nezahualcoyotl and CU-Amecameca, Family Physician, Unit of Family Medicine number 181 Valle de Chalco, Instituto Mexicano del Seguro Social, Mexico, E-mail: [capo730211@yahoo.es](mailto:capo730211@yahoo.es)

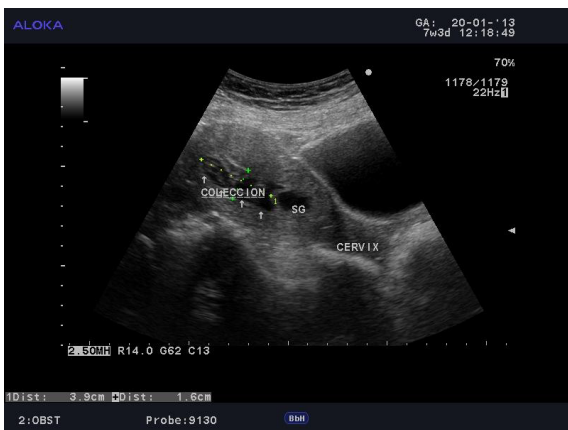
**Received** April 30, 2013; **Accepted** August 16, 2013; **Published** August 18, 2013

**Citation:** Quiroz-Pizar I, Yepiz RS, Casas-Patiño D, Rodríguez-Torres A, Galeana-Castillo C (2013) Cervical Ectopic Pregnancy: A Challenge. J Med Diagn Meth 2: 131. doi:10.4172/2168-9784.1000131

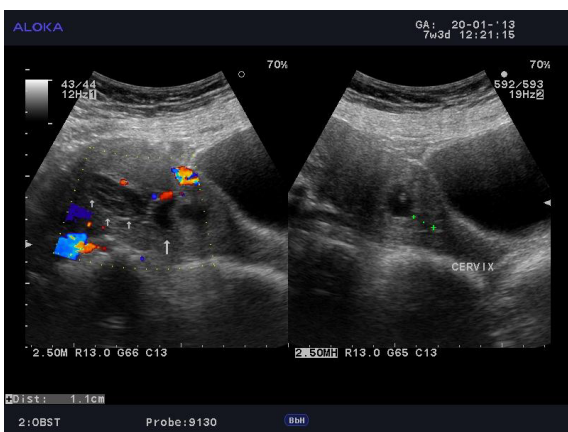
**Copyright:** © 2013 Quiroz-Pizar I, et al. This is an open-access article distributed under the terms of the Creative Commons Attribution License, which permits unrestricted use, distribution, and reproduction in any medium, provided the original author and source are credited.

previous cesarean sections without a history of curettage and / or assistance of in vitro fertilization, was admitted to the emergency service due to previous secondary amenorrhea for pregnancy around 6 weeks gestation by last menstrual period and transvaginal bleeding of just a few hours and colicky hypogastric pain, which was analyzed by pelvic ultrasound. A gestational sac was found at the level of the distal third of uterus, inside embryo heart activity and the presence of liquid collection from the third upper level of uterus. The ultrasound reported an abortion in evolution (Figure 1-4)

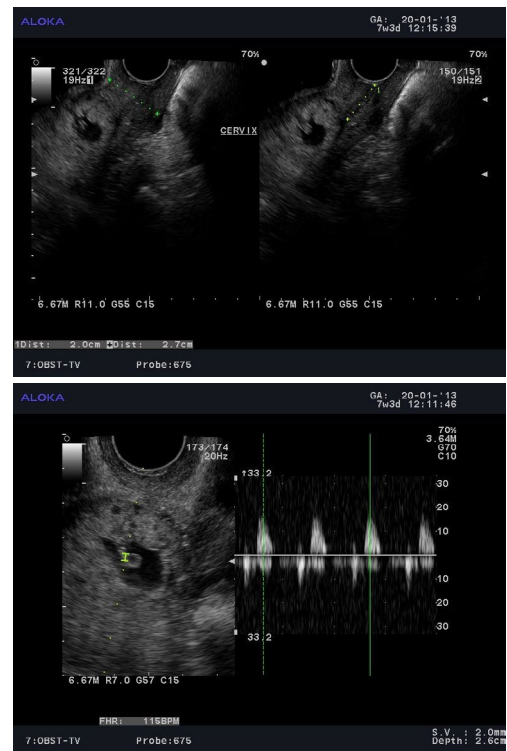
She stayed four days in the hospital and she left when the bleeding and abdominal pain disappeared. Two days after this discharge she started with transvaginal bleeding again, so she was hospitalized and ultrasound was performed, observing substantial changes in relation to the previous study, including a great intrauterine collection, but there were a persistent embryonic vitality and an important signal of perisacral blood flow, suspecting cervical ectopic pregnancy. The patient had more bleeding so we proceeded to carry out hysterectomy. The evolution of the patient was satisfactory and without complications so four days later she left the service. The pathology report showed an hypersecretory endometrium with Arias-Stella reaction, and hemorrhagic decidua and chorionic villi above the internal os.



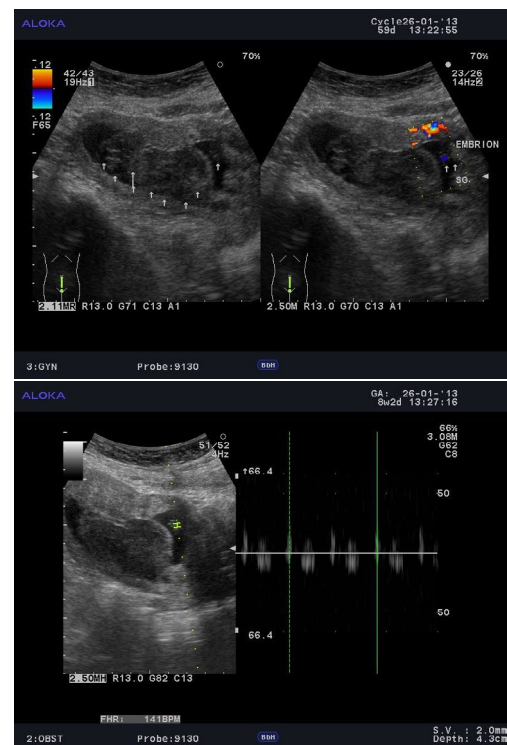
**Figure 1:** Longitudinal section of the uterus through the abdomen in which we see the gestational sac and a collection in the upper of the uterus (First hospitalization).



**Figure 2:** Longitudinal section of the uterus through the abdomen where gestational sac is seen at 1.1 cm above the internal os. (First hospitalization).



**Figure 3:** Longitudinal section of uterus by vaginal sonography. Observe the presence of gestational sac above the os. (First hospitalization).



**Figure 4:** These are the changes observed in comparison with the initial echography. The fluid collection increased and showed characteristics of not recently hematoma. This collection pushed down the gestational sac, however the cardiac activity persisted. (Second hospitalization).

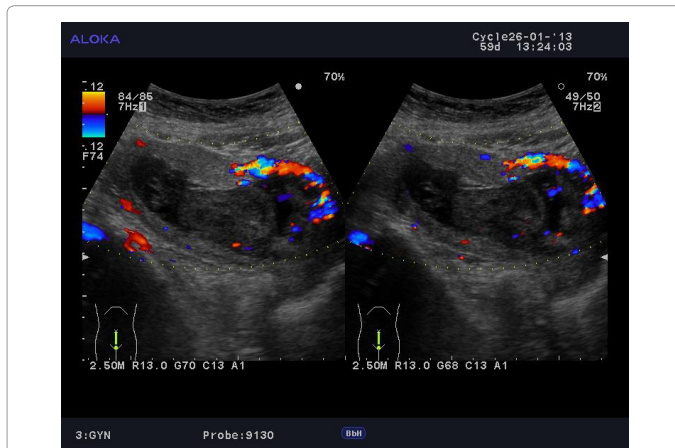
## Discussion

As has been proposed to differentiate abortion vs. cervical pregnancy by ultrasonographic findings as: 1. For the same gestational age, the uterine body is greater in abortion than in cervical pregnancy, in which the image can be seen as an “hourglass”; 2. In abortion, the endometrial cavity looks like an echogenic mass product of pregnancy tissues and blood clots, while in the cervical pregnancy we see a hyper-echogenic endometrium which is a result of the decidual reaction and 3. In abortion the internal Os is open and the endometrial cavity communicates directly with the endocervical canal, while in cervical pregnancy, it is closed [22] (Figure 5 and 6). We recognize that the confounding factor reported in this case was the presence of the fluid collection observed in the first study. We investigate the presence of cervical pregnancy in our hospital and no case was reported in the last five years. Because of the few cases of cervical pregnancy and the first

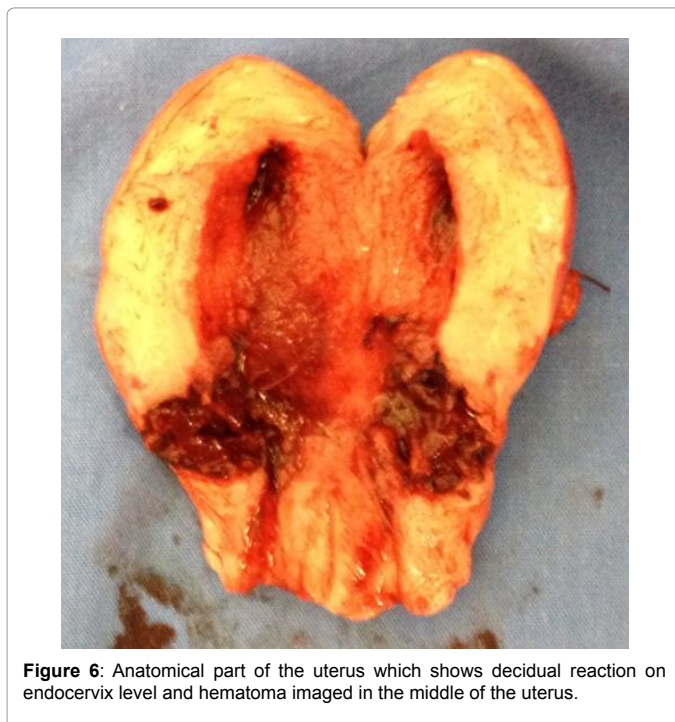ultrasonographic report, the wrong diagnosis was made, which could compromise the patient’s life. We gave feedback analyzing the clinical features and we conclude that if we had performed an appropriate semiology the diagnostic could have been suspected independently of the scan’s findings, because a technological resource such as an ultrasound, represents a support to confirm or reject a diagnosis, otherwise it could be a confounding factor.

Not in all cases the diagnosis of cervical pregnancy is easy. There have been some cases reported as heterotopic cervical and intrauterine pregnancy in which the cervical gestational sac showed no Doppler flow data, which was a distractor. However, the beta fraction of gonadotropic hormone was higher than it should have been in relation to the age of the pregnancy being this last cervical suspected pregnancy [21]. Another even more complex case was that of cervical ectopic pregnancy with placenta accrete with bladder involvement. There have also been reported cases of cervical ectopic twin pregnancy [23], etc.

All these situations obviously require radical treatment once the early diagnosis was made. In this case, the diagnosis was not made immediately but the suspect and the radical surgical treatment were made just on time. We conclude with a statement that reflects the feeling that we left this case: “The majority of Obstetricians will never see a cervical pregnancy, the minority who do encounter this complication will wish they had not “[Baptisti 1953] [24].



**Figure 5:** This image shows the peripheral flow blood of the gestational sac. (Second hospitalization).



**Figure 6:** Anatomical part of the uterus which shows decidual reaction on endocervix level and hematoma imaged in the middle of the uterus.

## References

1. Plascencia N, Hernández M, Guadarrama R, Guerra L, Salmón F, et al. (2008) Embarazo cervical, tres casos. *Ginecol Obstet Mex* 76: 744-8.
2. Vidal C. (2006) Embarazo cervical. Comunicación de un caso y revisión de la literatura. *Ginecol Obstet Mex* 74:594-598.
3. Orduño C, Méndez F, Valenzuela H, (2007) Embarazo ectópico cervical. Reporte de un caso. *Bol Clin Hosp Infant Son* 24: 89-92.
4. Corrales Y (2012) Embarazo ectópico bilateral. Presentación de un caso y revisión de la literatura. *Medisur* 10: 73-79.
5. Kirk E, Condous G, Haider Z, Syed A, Ojha K, Bourne T (2006) The conservative management of cervical ectopic pregnancies. *Ultrasound Obstetrics Gynecology* 27: 430-7.
6. Tejero C, Ortega M, Royo B, Pilar A, Lapresta M, et al. (2010) Gestación ectópica cervical tratada mediante punción ecoguiada intrasacul de metotrexato. *REV CHIL OBSTET GINECOL* 75: 325– 328.
7. Shavell V, Ebdallah M, Zakaria M, Berman J, Diamond M et al. (2012) Misdiagnosis of cervical ectopic pregnancy. *Archives of Gynecology and Obstetrics* 285: 423-426
8. Troncoso F, Cardone X, Rondini C (2005) Embarazo ectópico cervical. diagnóstico y tratamiento conservador con cerclaje cervical. *REV CHIL OBSTET GINECOL* 70: 257-259.
9. Cano L, Vital V, Alvarado I, Ferreira A, Hinojosa J (2002) Esterilidad Primaria y Embarazo cervical. *Ginecol Obstet Mex* 70:451-456.
10. Hafner, Ivkovic, Serman A, Bauman R, Ujevic B, (2010) Modification of conservative treatment of heterotopic cervical pregnancy by Foley catheter balloon fixation with cerclage sutures at the level of the external cervical os: a case report. *Journal of Medical Case Reports*. 4:212.
11. Nakao Y, Yokoyama M, Iwasaka T (2008) Uterine artery embolization followed by dilation and curettage for cervical pregnancy. *Obstet Gynecol* 11: 506-507.
12. Yu Bo, Douglass N, Guarnaccia M, Sauer M (2009) Uterine artery embolization as an adjunctive measure to decrease blood loss prior to evacuating a cervical pregnancy. *Archives of gynecology and obstetrics* 279: 721-724.
13. Andres MP, Campillos JM, Lapresta M, Lahoz I, Crespo R, et al. (2012) Management of ectopic pregnancies with poor prognosis through ultrasound guided intrasacul injection of methotrexate, series of 14 cases. *Arch Gynecol Obstet* 285: 529-33.

14. Taylor J, Yalcinkaya T, Akar M (2011) Successful conservative management of cervical ectopic pregnancy: a case series. *Archives of gynecology and Obstetrics* 283: 1215-1217.
15. Avery D, Wells M, Harper D (2009) Cervico- Isthmic Corporeal Pregnancy with delivery at term: A review of the literature with a Case Report. *Obstetrical and Gynecological Survey* 64: 335-344.
16. Cifuentes J, Martínez J, Cabrera C, Spichinger O, Fariás G, et al. (2006) Embarazo cervical: Una decisión difícil de tomar. *Rev Chil Ultrasonog* 9: 10-12.
17. Vidal C, Trujillo J, Grover F (2006) Embarazo cervical. Comunicación de un caso y revisión de la literatura. *Ginecol Obstet Mex* 74: 594-8.
18. Jaswal T, Sunita S, Smiti N, Sagwan K, Chauhan M, et al. (2002) Cervical ectopic pregnancy with placenta percreta and bladder wall invasion. *Acta Obstet Gynecol Scand* 81: 991-992.
19. Cherng J, Ma-Lee K, Shen J (2007) Transvaginal Ultrasound-Guided Treatment of Cervical Pregnancy. *Obstet Gynecol* 109: 1076-1082.
20. Sherer D, Gorelick C, Dalloul M, Sokolovski M, Kheyman M (2008) Three-Dimensional Sonographic Findings of a Cervical Pregnancy. *J Ultrasound Med* 27:155-158.
21. Briceño C (2002) Embarazo cervical. *Rev Obstet Ginecol Venez* 62: 4 Caracas dic.
22. Porpora M, D'Elia C, Bellavia M, Pultrone D, Cosmi E (2003) Heterotopic cervical pregnancy: a case report. *Acta Gynecol Scand* 82:1058-1059.
23. Pascual M, Ruiz J, Tresserra F, Sanuy C, Grases P ,et al.(2001) Cervical ectopic twin pregnancy: diagnosis and conservative treatment. *Human Reprod* 16: 584-586.
24. Mortimer C, Aiken D (1968) Cervical pregnancy. *Journal of Obstetrics and Gynaecology* 75: 741-745..