

## Central Serous Chorioretinopathy

Yassine Mouzari\* and Kriet M

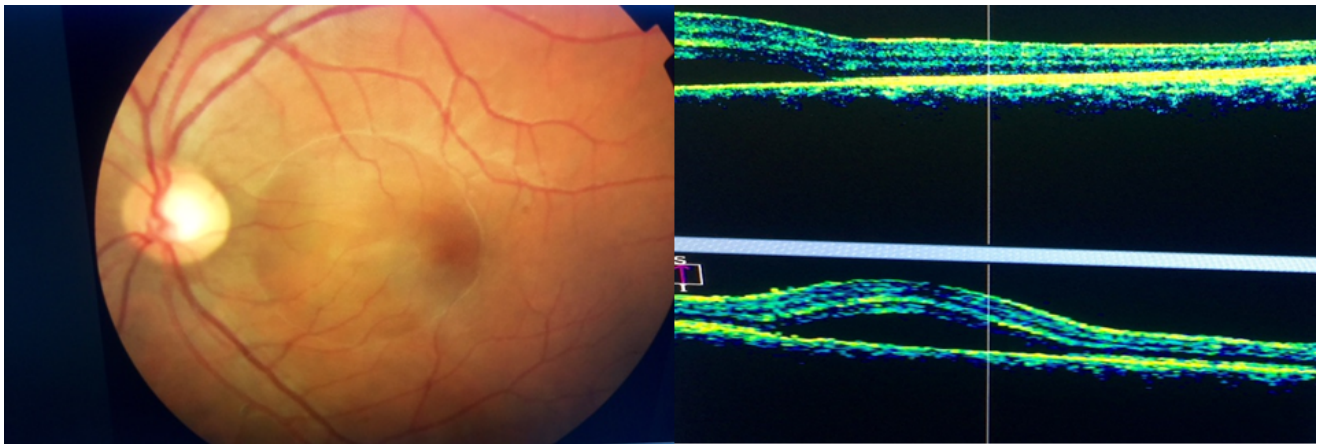
Department of Ophthalmology, Avicenne Military Hospital of Marrakech, Morocco

\*Corresponding author: Yassine Mouzari, Department of Ophthalmology, Avicenne Military Hospital of Marrakech, Morocco, Tel: +212 641-930448; E-mail: mouzari76@yahoo.fr

Rec date: Nov 02, 2016, Acc date: Nov 04, 2016, Pub date: Nov 07, 2016

Copyright: © 2016 Mouzari Y, et al. This is an open-access article distributed under the terms of the Creative Commons Attribution License, which permits unrestricted use, distribution, and reproduction in any medium, provided the original author and source are credited.

### Image Article



**Figure 1:** Chorioretinitis central serous of left eye.

Chorioretinitis central serous left eye in a young elderly patient with the presence of a bubble in the fundus macular confirmed in October by the appearance of a serous.