

Cardiac Calcification Following Severe Sepsis: A Case Report and Review of the Literature

Türkay Akbaş^{1*}, Miraç Özen², Cafer Adıgüzel³, Nuri Çağatay Çimşit⁴ and Sait Karakurt⁵

¹Department of Internal Medicine and Critical Care Unit, Marmara University, Turkey

²Department of Internal Medicine, Marmara University, School of Medicine, Turkey

³Department of Haematology, Marmara University, Turkey

⁴Department of Radiology, Marmara University, Turkey

⁵Department of Pulmonary and Critical Care Medicine, Marmara University, Turkey

Abstract

There are two types of myocardial calcification: metastatic calcification that is encountered in chronic renal disease patients and dystrophic calcification which develops in injured myocardium. Myocardial infarction, trauma, surgery and myocarditis are the most commonly faced reasons for dystrophic calcification. Here we present a rare case of a patient in whom myocardial calcification was diagnosed after severe sepsis.

Keywords: Myocardial calcification; Sepsis-related myocardial injury

Introduction

Sepsis is an important cause of organ failures in the Intensive Care Unit (ICU). All organ systems including myocardium can be injured severely during sepsis [1,2]. Myocardial injury may end up with calcification which is a rare complication of severe sepsis. In this paper, we discuss a patient who developed diffuse left ventricular wall calcification during severe systemic sepsis.

Case and Method

A 36-year-old woman with acute myeloblastic leukemia was admitted to the ICU with septic shock. The patient had leukemia diagnosis about two and a half months ago. She took chemotherapies of cytosine arabinoside (170 mg/day) and idarubicin (20 mg/day) in the week of the diagnosis. Two days after chemotherapy, the patient became neutropenic and five days later, she developed a fever. The patient stayed in the hospital until admission to the ICU because of severe neutropenia, thrombocytopenia and unresolved infectious state. Laboratory findings of CRP, procalcitonin, white blood cell count and platelet count studied at the time of ICU admission were 268 mg/L, 97 ng/mL, 200/mm³ and 2000/mm³, respectively. After ICU admission, her first blood culture was positive for *Escherichia coli*. Then, *Acinetobacter baumannii* was isolated on day 5 and *Enterococcus faecium* on day 9 from blood cultures. The patient had multiorgan failures of renal, cardiovascular, hepatic and respiratory systems, and critical illness myopathy developed during bacteremic periods. The patient had noradrenalin during the first 3 days of the ICU stay in which a maximum dose of 40 mcg/min was administered for 24 hours. Dopamine was added to noradrenalin during the first day, with a maximum dose of 20 mcg/kg/min for a few hours. Antibiotic treatments were managed according to the antibiograms. The patient benefited from the therapies, became mechanical ventilation-free, and did not have any renal replacement therapy. Daily physiotherapy for critical illness myopathy was continued. The extreme levels of serum creatinine, phosphorus and calcium measured during multiorgan failures were respectively 1.84, 8.1 and 7.7 mg/dL, and calcium-phosphate product was calculated as 68.2 mg²/dl². The peak levels of Troponin T and creatine phosphokinase-MB were 47.6 ng/L (normal < 14) and 9.18 IU/L (normal < 5) with no significant electrocardiographic changes.

The patient started to have fever exceeding 39 celsius on day 15. *Pseudomonas aeruginosa* was isolated from deep tracheal aspirate on day 20 and antibacterial treatment was modified. Chest and abdomen computed tomographies (CT) were taken on day 25 due to persistent fever. Abdomen CT was normal, but thorax CT showed bilateral pneumonia and diffuse left ventricular wall calcification (Figure 1) that was not seen on the previous CT scan from a month ago (Figure 2). After reexamining the chest X-ray taken one day before thorax CT, a vague curvilinear calcification was noticed at the left ventricular wall (Figure 3). Previous echocardiography done two and a half months ago was normal, but the new one showed hypokinetic posterior, inferior and septal walls of the left ventricle with a 40% ejection fraction. For excluding leukemia-induced fever, a bone marrow biopsy was carried out that showed the disease in remission. The patient also

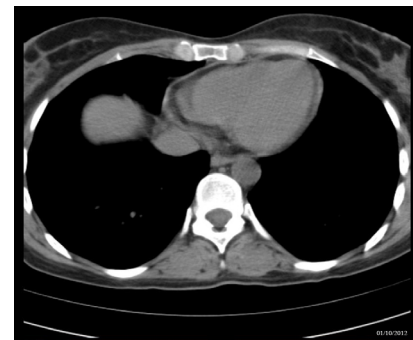

Figure 1: Computed tomography scan performed one week before the ICU admission showing a normal heart.

***Corresponding author:** Dr. Türkay Akbaş, Department of Internal Medicine and Critical Care, School of Medicine, Marmara University, Unit Fevzi Çakmak Mahallesi, Mimar Sinan Caddesi, No: 41 Ust Kaynarca, Pendik, Istanbul, Turkey, Tel: 090-532-238-31-97; E-mail: turkayakbas@yahoo.com

Received April 25, 2014; Accepted May 27, 2014; Published May 29, 2014

Citation: Akbaş T, Özen M, Adıgüzel C, Çimşit NÇ, Karakurt S (2014) Cardiac Calcification Following Severe Sepsis: A Case Report and Review of the Literature. J Anesth Clin Res 5: 409. doi:10.4172/2155-6148.1000409

Copyright: © 2014 Akbaş T, et al. This is an open-access article distributed under the terms of the Creative Commons Attribution License, which permits unrestricted use, distribution, and reproduction in any medium, provided the original author and source are credited.

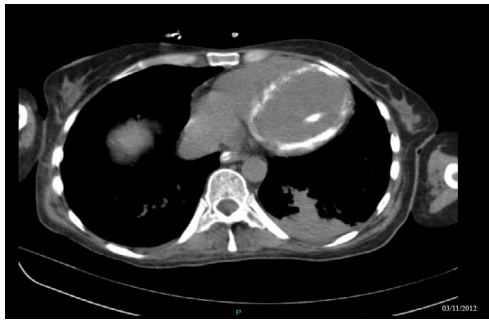

Figure 2: Computed tomography scan performed on day 25 after the ICU admission showing a diffuse left ventricular calcification.

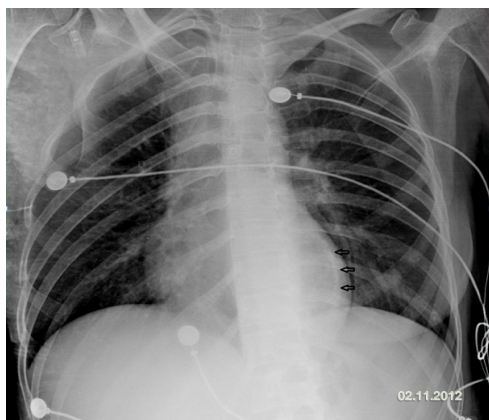


Figure 3: Anteroposterior radiograph performed on day 24 after the ICU admission demonstrating a vague curvilinear calcification along the left ventricular wall (arrows).

did not benefit from empirically commenced antifungal and antiviral treatments and died because of septic shock on day 37. Unfortunately, the family did not give approval for an autopsy; however we obtained informed consent for the writing of the case from the legal relative.

Discussion

Myocardial calcification is classified as either dystrophic or metastatic. Metastatic calcification is commonly encountered in chronic renal failure patients, where changes in calcium and phosphate metabolisms are thought to lead to metastatic calcification in various organs including cardiovascular system [3,4]. Dystrophic calcification is not common and reported after myocardial infarction, trauma, surgery and myocarditis [3,4]. It develops rapidly from days to months in areas of myocardial necrosis, hemorrhage, or fibrosis [3,4]. It is also reported in patients with severe sepsis and septic shock [5-10].

Sepsis itself causes cardiomyopathy described as acute left ventricular wall dilation and decrease in ejection fraction. Typically, cardiac dysfunction is detectable within the first 24 hours of septic shock and completely reversible in survivors by 7-10 days [1,2]. The mechanism of cardiomyopathy can not be attributed to decreased coronary blood flow as angiographic examinations showed normal, even increased coronary blood flow [1]. It is thought to be because of sepsis-induced flow disturbances, endotoxins, circulating myocardial depressant substances and cytokines, alterations of calcium flux in myocytes, and development of mitochondrial dysfunction [1,2,11]. Additionally, catecholamines released during septic shock or given

during the treatment of septic shock are proposed to induce myocardial injury [6,7,9]. Whatever the cause of injury is, the presence of injured myocardium can act as a site for calcium deposition.

Since cardiac calcification after severe sepsis and septic shock is rare, it is generally discussed on case reports as the patients being treated with catecholamines, having elevated cardiac markers without marked electrocardiographic abnormalities, not having end-stage renal disease, and most importantly, having the diagnosis of myocardial calcification by CT images weeks after the ICU admission [5-10]. Information about serum calcium and phosphate levels was mentioned in two reports. Calcium and phosphate levels were stated as normal in one report [8], whereas low calcium but high phosphate levels with calcium-phosphate product of $55.4 \text{ mg}^2/\text{dl}^2$ were reported in another one [7].

CT is a gold diagnostic tool for cardiac calcification and generally, the diagnosis of myocardial calcification is achieved accidentally by thorax CT [4]. Echocardiography gives different results. It may be totally normal [10] or it may support calcification by demonstrating increased echodensity of the ventricular walls [5,8,9]. It may also disclose calcified myocardium directly [6], or reveal left ventricular systolic dysfunction [7], Chest X-ray is not diagnostic, but an increased density around the left ventricle gives a clue for calcification [9]. Diagnosis is also achieved by postmortem histopathological studies [8,10]. Calcification mainly affects the left ventricle, but the right ventricle can be involved as well [4,8]. These patients may have the risk of sudden cardiac death [8,10]. Improved cardiac function with an increase in ejection fraction is reported in survived patients but without a change in calcification [6,7].

In this paper, we discussed the case of a patient with septic shock who had the diagnosis of dystrophic myocardial calcification after 3 weeks of ICU stay. The patient had elevated cardiac markers without electrocardiographic changes. The diagnosis was done accidentally by thorax CT. Echocardiography disclosed mild left ventricular dysfunction. Although serum calcium level was normal, serum phosphate level increased during the development of acute kidney injury. In one week, kidney function including serum phosphate returned to normal levels. This excludes the probability of metastatic calcification. The patient had chemotherapy about two and a half months ago and her thorax CT taken before ICU admission showed a normal heart. Thus, we excluded the possibility of chemotherapy-induced myocarditis. Since the patient had severe sepsis with multiorgan failures, sepsis-related dystrophic calcification was the best explanation.

In conclusion, dystrophic myocardial calcification can be encountered in patients with severe sepsis and septic shock. It evidences the severity of septic shock-related cardiomyopathy which can lead to sudden cardiac death.

Acknowledgement

This case has been presented at the 14th National Congress of Turkish Thoracic Society, Antalya, Turkey, 2013.

No financial support has been received from any organization or person during the writing of the manuscript. All authors have disclosed that they have no financial involvement with any organization or entity. They also have disclosed that this paper has not been published and is not under consideration for publication elsewhere. All authors read, edited and ultimately approved the final manuscript.

References

1. Flierl MA, Rittirsch D, Huber-Lang MS, Sarma JV, Ward PA (2008) Molecular events in the cardiomyopathy of sepsis. *Mol Med* 14: 327-336.

2. Grocott-Mason RM, Shah AM (1998) Cardiac dysfunction in sepsis: new theories and clinical implications. *Intensive Care Med* 24: 286-295.
3. Catellier MJ, Chua GT, Youmans G, Waller BF (1990) Calcific deposits in the heart. *Clin Cardiol* 13: 287-294.
4. Gowda RM, Bost LM (2004) Calcifications of the heart. *RadiolClin North Am* 42: 603-617, vi-vii.
5. vanKruisdijk RC, van der Heijden JJ, Uijlings R, Otterspoor LC (2011) Sepsis-related myocardial calcification. *Circ Heart Fail* 4: e16-18.
6. Schellhammer F, Ansén S, Arnold G, Brochhagen HG, Lackner K (2002) Myocardial calcification following septic shock. *Cardiology* 98: 102-103.
7. Simonson S, Miller WT Jr, Perl A, Torigian DA (2007) Diffuse left ventricular myocardial calcification in the setting of sepsis on CT imaging. *J Thorac Imaging* 22: 343-345.
8. Sinicina I, Matevosian E, Fischer F, Mall G, Graw M (2005) The petrified heart in sepsis. *Virchows Arch* 447: 875-878.
9. Lapatto-Reiniluoto O, Vaalamo M, Takkunen O, Mänttari M (2000) Left ventricular calcification following resuscitation. *J Intern Med* 248: 85-87.
10. Rossi MA, Santos CS (2003) Sepsis-related microvascular myocardial damage with giant cell inflammation and calcification. *Virchows Arch* 443: 87-92.
11. Takasu O, Gaut JP, Watanabe E, To K, Fagley RE, et al. (2013) Mechanisms of cardiac and renal dysfunction in patients dying of sepsis. *Am J RespirCrit Care Med* 187: 509-517.