

## Can Headache Help to Rule Out Stroke Mimics during Stroke Alert?

Evgeny V Sidorov<sup>1\*</sup>, David M. Thompson<sup>2</sup>, Vijay Pandav<sup>3</sup>, Joshua Santucci<sup>1</sup>, Bradley Bohnstedt<sup>4</sup> and Bappaditya Ray<sup>1</sup>

<sup>1</sup>Department of Neurology, University of Oklahoma Health Science Center, U.S.A

<sup>2</sup>Department of Statistics, University of Oklahoma Health Science Center, U.S.A

<sup>3</sup>St. Francis Medical Center, Tulsa, Oklahoma, U.S.A

<sup>4</sup>Department of Neurosurgery, University of Oklahoma Health Science Center, U.S.A

\*Corresponding Author: Evgeny V Sidorov, Associate Professor, Department of Neurology, University of Oklahoma Health Sciences Center, 920 Stanton L. Young Blvd., Suite 2040, Oklahoma City, OK 73104-5036, U.S.A, Tel: 405-271-4113; Fax: 405-271-5723; E-mail: [Evgeny-Sidorov@ouhsc.edu](mailto:Evgeny-Sidorov@ouhsc.edu)

Received date: November 15, 2017; Accepted date: November 22, 2017; Published date: November 27, 2017

Copyright: © 2017 Sidorov EV, et al. This is an open-access article distributed under the terms of the Creative Commons Attribution License, which permits unrestricted use, distribution, and reproduction in any medium, provided the original author and source are credited.

### Abstract

**Objective:** When patients present to the emergency department (ED) with acute focal neurological deficit, sometimes it is hard to make a decision about IV thrombolysis. In such situations, neurologists need to make a judgment call about it. According to some studies, IV thrombolysis is safe for patients with stroke mimics; however, a small possibility of hemorrhage still exists. Furthermore, unnecessary IV thrombolysis in stroke mimics significantly increases cost of care. We aimed to determine if presence of headache in patients with focal neurological deficit during stroke alerts makes a difference in the neurologist decision about IV thrombolysis.

**Methods:** A retrospective chart review of 326 patients who presented to The University of Oklahoma Medical Center (OUMC) as a stroke alert in 2013.

**Results:** At OUMC, 151 patients were ineligible for IV thrombolysis. Out of the remaining 175 patients, 62 presented with and 113 without headache. Seven out of the 62 patients with headache were initially diagnosed in the ED with ischemic stroke and received IV thrombolysis. On later evaluation, all of these 62 patients turned out to be stroke mimics. Forty-five out of 113 patients without headache were initially diagnosed as ischemic stroke in the ED and received IV thrombolysis. Nine of these 45 patients were later diagnosed as stroke mimics while 36 had ischemic stroke. Out of the remaining 68 patients without headache, who were initially diagnosed with stroke mimics and did not receive IV thrombolysis, 4 were later diagnosed with ischemic stroke and 64 were confirmed stroke mimics. In general, patients with headache had much less frequent IV thrombolysis 7/62 (11%) than patients without headache 45/113 (40%) ( $p < 0.0001$ ). No patients with headache, compared to 40 patients (36 who had IV thrombolysis+4 who did not) without headache, were later diagnosed with ischemic stroke ( $p < 0.0001$ ).

**Conclusion:** Patients with headache and acute focal neurological deficit less frequently receive IV thrombolysis and are less frequently diagnosed with ischemic stroke after completion of workup. Presence of headache may help neurologists to decide whether to do IV thrombolysis.

**Keywords:** Code stroke; IV thrombolysis; Headache; Stroke mimics

### Introduction

Stroke is the fifth leading cause of mortality and has affected the lives of 6.3 million people living in the United States [1]. IV thrombolysis is one of the few effective treatments available for acute ischemic stroke (AIS), which is given within 3.0-4.5 h from the last time that someone observed the patient to be without neurological deficit [2]. This narrow therapeutic window forces physicians to make quick decisions, which often leads to administration of IV tPA to patients with stroke mimics [3]. While several studies proved IV tPA to be safe, risk of hemorrhage still exists [3,4]. Furthermore, mistaken IV thrombolysis makes care more expensive due to cost of the following ICU observation and drug itself [5-7]. Thus it is in the best interest of both patient and physician to avoid administering IV tPA to stroke mimic patients. This decision at times is very hard to make and different information from the history and presenting symptoms should be taken into account. One such symptom is the presence of

headache during stroke alert, which is comparatively easy to determine, except for when a patient has aphasia or severe encephalopathy [8,9]. In this study we aimed to evaluate if the presence of headache during stroke alert in patients with focal neurological deficit can help neurologists decide about IV thrombolysis.

### Materials and Methods

#### Patients

We retrospectively reviewed the charts of patients where stroke alert was activated during 2013 and collected the following information: age, gender, heart rate, systolic and diastolic blood pressure at presentation, NIHSS, presence and type of headache (unilateral, bilateral, thunderclap) during stroke alert, and discharge diagnosis. All patients in our study had focal neurological deficit at presentation including, but not limited to: hemisensory loss, hemiparesis, hemianopsia, facial weakness, aphasia or neglect. Patients younger

than 18 years of age were excluded from the study because IV thrombolysis is not approved for this age group.

**Design**

We calculated the proportion of stroke alert patients with and without headache who had IV thrombolysis. Then, we calculated the proportion of all stroke alert patients with and without headache who were ultimately diagnosed with AIS. Lastly, we looked at how often the decision about IV thrombolysis was correct and how the presence of headache and its characteristics during stroke alert influenced this decision.

**Stroke alert protocol**

The University of Oklahoma Medical Center (OUMC) emergency department charge nurse activates stroke alerts for all patients with new focal neurological deficit within 7 h. Neurology residents evaluate the patient, perform a non-contrast head CT, and communicate with the attending physician regarding IV thrombolysis/thrombectomy. CT angiogram (CTA) of head and neck vessels is only done on selected patients. Physicians rarely could request emergent brain MRI to clarify diagnosis.

**Statistical analysis**

We used chi square test to compare, between stroke alert patients with confirmed AIS or stroke mimics, the percentage who reported headaches. We regarded an alpha value of 0.05 as being statistically significant. We used SAS v9.4 for our analysis.

**Results**

A total of 326 stroke alert patients presented to OUMC during 2013. We excluded 68 patients from analysis because they were outside of the 4.5 h window for consideration of IV tPA. We also excluded from the analysis another 81 patients who had different contraindications for IV tPA administration (taking anticoagulants, platelets below 100 k, recent surgeries). Two patients left the ED against medical advice. This study focuses on the remaining 175 patients, for whom the decision whether to provide IV tPA was based on clinical presentation and non-contrast head CT. Clinical characteristics of these patients are presented in Table 1.

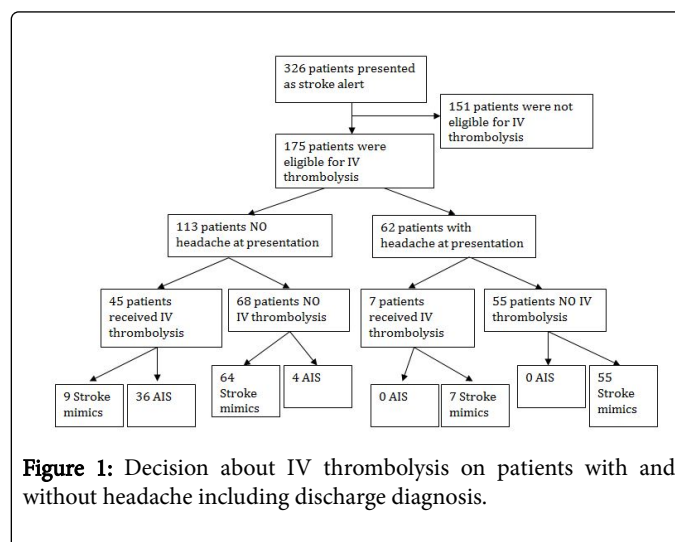
Clinical Characteristics	Acute Ischemic Stroke	Stroke mimic	p value
	N=40	N=135	
Mean Age (years) at presentation	69	57	0.00001
Mean Systolic Blood Pressure (mm Hg) at Presentation	151	144	0.39
Mean Diastolic Blood Pressure (mm Hg) at Presentation	78	84	0.62
Mean Heart Rate (bpm) on Admission	80	79	0.9
Mean NIHSS at presentation	12	4	0.0000002
Headache at presentation	0 (0%)	62 (45.9%)	<0.0001

Received IV tPA	36 (90%)	16 (11.9%)	<0.01
-----------------	----------	------------	-------

**Table 1:** Clinical characteristics of patients with discharge diagnosis of stroke vs. stroke mimic

**Headache during stroke alert and decision about IV thrombolysis**

In this study, 175 patients were considered for IV thrombolysis: 62 of them presented with and 113 without headache. Seven out of the 62 patients with headache were initially diagnosed in the ED with ischemic stroke and received IV thrombolysis. On later evaluation, all of these 62 patients, including those who received IV thrombolysis, turned out to be stroke mimics. Forty-five out of the 113 patients without headache were initially diagnosed as ischemic stroke in the ED and received IV thrombolysis. Nine of these 45 patients were later diagnosed as stroke mimics, while 36 had ischemic stroke. The remaining 68 patients without headache were initially diagnosed with stroke mimics and did not receive IV thrombolysis. Four of them later were diagnosed with ischemic stroke and 64 were confirmed to be stroke mimics (Figure 1). Information about quality and location of headaches was not available in the chart.



**Figure 1:** Decision about IV thrombolysis on patients with and without headache including discharge diagnosis.

In general, after initial evaluation in the ED, patients who presented with headache less frequently received IV thrombolysis 7/62 (11%) than patients who presented without headache 45/113 (40%) (p<0.0001). After complete evaluation, including brain MRI, no patients with headache compared to 40 patients (36 who had IV thrombolysis+4 who did not) without headache were diagnosed with ischemic stroke (p<0.0001). Table 2 shows the discharge diagnosis of all patients.

Discharge diagnosis	IV tPA	No IV tPA
Acute Ischemic Stroke	36	4
Migraine with motor aura	10	52
Seizures	2	26
Toxic Metabolic Encephalopathy with reactivation of old deficit	1	16
Posterior Reversible Vasoconstriction Syndrome (PRES)	0	4

Transient Ischemic Attack (TIA)	3	5
Conversion Disorder	0	4
Cervical myelopathy	0	3
Anxiety/Pain	0	4
Hypoglycemia	0	2
Bell's palsy	0	3

**Table 2:** Discharge diagnosis of all patients with and without IV tPA.

## Discussion

This small retrospective study shows that patients with acute focal neurological deficit who had headache during stroke alert presentation were more commonly diagnosed with stroke mimics and less frequently had IV thrombolysis compared to patients who had no headache at presentation. In contrast, patients who presented without headache were more frequently diagnosed with AIS and received IV thrombolysis, than patients who presented with headache. As such, the presence of headache may help to influence the neurologist decision whether or not to administer IV tPA.

In our study, none of the 16 stroke mimic patients who received IV thrombolysis had bleeding complications, a finding that aligns with those of other authors, who proved that IV tPA in stroke mimics is safe [4]. However, besides bleeding risk, IV tPA adds unnecessary cost to the treatment of stroke mimics because of the drug itself and the following ICU or stroke unit observation [10]. Kleindorfer and colleagues found that the price for IV tPA has increased substantially from \$30.50 per 1 mg in 2005 to \$64.30 per 1 mg in 2014, which brought the cost of single IV tPA infusion to over \$5,000 [11]. Cost for 24 h ICU observation varies from \$1,834 to \$10,794 [12,13]. As a result, all of this makes it financially beneficial for both hospitals and patients to avoid unnecessary IV thrombolysis.

Although in our study no patients with headache had AIS, most likely because of small sample size or inability to report headache, the literature reports frequency of headache in AIS patients from 7.4 to 11% [8,9,14,15]. Headache during AIS is more common in younger patients, those with arterial dissection, and posterior circulation stroke [8,16]. Thus, headache cannot be used as a single dichotomous variable in the decision whether or not to administer IV tPA. Rather, headache can help neurologists make better clinical decisions regarding IV thrombolysis in combination with other symptoms and history details. In our study, stroke mimic patients were younger and had lower NIHSS (Table 1). We also noticed a trend that AIS patients had higher systolic blood pressure at presentation. We found no difference in diastolic blood pressure or heart rate of presenting patients.

Frequent headache in stroke mimics in our study corresponds to a high number of patients discharged with the diagnosis of migraine with motor aura (Table 2). Although initially designed, we could not determine headache characteristics in our patients because this information was not available in the chart. We relate this to the retrospective way of data collection and limited time for patient evaluation during stroke alerts. Other limitations of this study include comparatively small sample size and physicians' bias to diagnose stroke mimics, in particular migraine with aura. A high number of patients initially suspected for basilar artery thrombosis were later diagnosed with toxic-metabolic encephalopathy or reactivation of old deficits.

Overall, our study indicates that headache is a common symptom during stroke alert and is more frequently associated with stroke mimics than with AISs. The presence of headaches may help neurologists to think about stroke mimics, but at the same time, it does not rule out AIS. Thorough evaluation of headache patients with acute focal neurological deficit is still necessary. Although brain MRI better differentiates strokes from stroke mimics, it is rarely available in community hospitals in emergency settings [17]. Other clinical features besides headache such as young age, low NIHSS, recurrent admissions with similar symptoms, or absence of atrial fibrillation or old strokes on head CT may also help to suspect a stroke mimic. Future studies should concentrate on validating and organizing these symptoms into a scale in order to increase the probability of reserving thrombolysis for real AISs.

## References

- Blackwell DL, Lucas JW, Clarke TC (2014) Summary health statistics for U.S. adults: national health interview survey, 2012. *Vital Health Stat* 10 260: 1-161.
- Hacke W, Kaste M, Bluhmki E, Brozman M, Davalos A, et al. (2008) Thrombolysis with alteplase 3 to 4.5 hours after acute ischemic stroke. *N Engl J Med* 359: 1317-1329.
- Guillan M, Alonso-Canovas A, Gonzalez-Valcarcel J, Garcia Barragan N, Garcia Caldentey J, et al. (2012) Stroke mimics treated with thrombolysis: further evidence on safety and distinctive clinical features. *Cerebrovasc Dis* 34: 115-120.
- Chernyshev OY, Martin-Schild S, Albright KC, Barreto A, Misra V, et al. (2010) Safety of tPA in stroke mimics and neuroimaging-negative cerebral ischemia. *Neurology* 74: 1340-1345.
- Nguyen PL, Chang JJ (2015) Stroke Mimics and Acute Stroke Evaluation: Clinical Differentiation and Complications after Intravenous Tissue Plasminogen Activator. *J Emerg Med* 49: 244-252.
- Sivakumaran P, Gill D, Mahir G, Baheerathan A, Kar A (2016) A Retrospective Cohort Study on the Use of Intravenous Thrombolysis in Stroke Mimics. *J Stroke Cerebrovasc Dis* 25: 1057-1061.
- Tsivgoulis G, Zand R, Katsanos AH, Goyal N, Uchino K, et al. (2015) Safety of intravenous thrombolysis in stroke mimics: prospective 5-year study and comprehensive meta-analysis. *Stroke* 46: 1281-1287.
- Kumral E, Bogousslavsky J, Van Melle G, Regli F, Pierre P (1995) Headache at stroke onset: the Lausanne Stroke Registry. *J Neurol Neurosurg Psychiatry* 58: 490-492.
- Pollak L, Shlomo N, Korn Lubetzki I, National Acute Stroke Israeli Survey Group (2017) Headache in stroke according to National Acute Stroke Israeli Survey. *Acta Neurol Scand* 135: 469-475.
- Alexandrov AW, Coleman KC, Palazzo P, Shahripour RB, Alexandrov AV (2016) Direct stroke unit admission of intravenous tissue plasminogen activator: safety, clinical outcome, and hospital cost savings. *Ther Adv Neurol Disord* 9: 304-309.
- Kleindorfer D, Broderick JP, Demaerschalk BM, Saver JL (2016) Abstract WP78: The Cost of Alteplase Has More Than Doubled Over the Past Decade. *Stroke* 47: AWP78.
- Gershengorn HB, Garland A, Gong MN (2015) Patterns of Daily Costs Differ for Medical and Surgical Intensive Care Unit Patients. *Ann Am Thorac Soc* 12: 1831-1836.
- Dasta JF, McLaughlin TP, Mody SH, Piech CT (2005) Daily cost of an intensive care unit day: the contribution of mechanical ventilation. *Crit Care Med* 33: 1266-1271.
- Chen PK, Chiu PY, Tsai IJ, Tseng HP, Chen JR, et al. (2013) Onset headache predicts good outcome in patients with first-ever ischemic stroke. *Stroke* 44: 1852-1858.
- Abadie V, Jacquin A, Daubail B, Vialatte AL, Lainay C, et al. (2014) Prevalence and prognostic value of headache on early mortality in acute stroke: the Dijon Stroke Registry. *Cephalalgia* 34: 887-894.

16. Arboix A, Massons J, Oliveres M, Arribas MP, Titus F (1994) Headache in acute cerebrovascular disease: a prospective clinical study in 240 patients. *Cephalgia* 14: 37-40.
17. Rai AT, Carpenter JS, Peykanu JA, Popovich T, Hobbs GR, et al. (2008) The role of CT perfusion imaging in acute stroke diagnosis: a large single-center experience. *J Emerg Med* 35: 287-292.