

## Breast Tuberculosis Report of Two Cases

Fatnassi R<sup>1\*</sup>, Mkinini I<sup>1</sup>, Kaabia O<sup>1</sup>, Rigmoun H<sup>1</sup>, Hamdi A<sup>1</sup>, Essaidi H<sup>2</sup> and Khairi H<sup>2</sup>

<sup>1</sup>Department of Gynaecology, Hospital Ibn El Jazzar, Kairouan, Tunisia

<sup>2</sup>Department of Gynaecology, Hospital Farhat Hached, Soussa, Tunisia

### Abstract

Breast tuberculosis is rare and represents only 1/4000 of the surgical affections of the breast. It is the women's prerogative, especially in the procreative period. Multiparity and breast feeding seem to be supporting factors. Clinical symptoms are various. The diagnosis is essentially based on histological examination. Indeed, the isolation of the Bacilli of Koch (BK) is possible only in 25 to 30% of all cases. Treatment is based on anti-tuberculars. Surgery has a much reduced place.

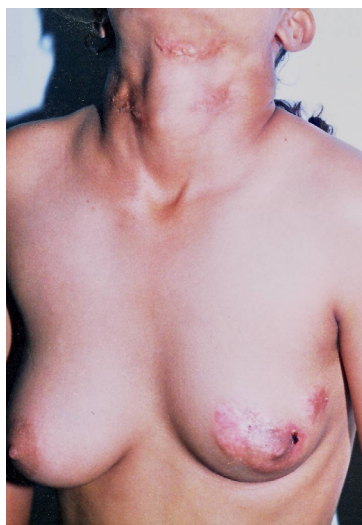**Keywords:** Tuberculosis; Breast; Histology; Anti-tuberculars

### Introduction

Breast tuberculosis was first described in 1829 by Sir Ashley Copper as a "cold mammal tumour" [1]. It is a very rare illness. In fact, only 700 cases have been reported in literature. Its symptoms are various. The diagnosis is easy, commonly based on histological examination, rarely on bacteriological one. It is exceptional on young and menopausal women. We observed two cases: one is a 14 year old girl and the other in a 43 year old menopausal woman.

### Case 1

M.I. a 14 year old girl, with a low socio-economical level, was admitted at the Gynaecological Department at Kairouan's Hospital to explore a recurrent gathering in her left breast. There is no tubercular case in the family but she had cervical abscesses at the age of twelve that were not treated and that she recovered in 3 months leaving scars. The physical exam finds a girl in a good state with cervical scars typically indicating tuberculous lymphadenitis of the cervical nodes with a mass of firm, matted nodes with chronic draining fistulous tracts to overlying skin. The right breast is normal. The left one contains a cold abscess in the Supero External Quadrant with a fistula on the skin springing pus that has the texture of soft white cheese called caseum, associated with mammal scars signing for old abscesses (Figure 1). There are no axillary



**Figure 1:** Neck sequela of tuberculous lymphadenitis in the cervical nodes associated with multiple mammal injuries due to a chronic mastitis. (Case 1).

lymph nodes. The microscopic examination and the microbiological culture of a sample of the pus are negative. The mammography and the chest X-ray are normal. The blood tests show an inflammatory syndrome with a sedimentation speed of 50/80. The tuberculin skin test is positive with an induration of about 10 millimetres. The biopsy showed a granuloma, with multinucleated giant cells with nuclei arranged like a horseshoe (Langhans giant cells) surrounding the epithelioid infected macrophages without any caseous necrosis in the center of caseating tubercle (Figure 2). These results suggested breast tuberculosis. The patient received a three months treatment including 0.75 g/day of Streptomycine, 3 pills/day of Isoniazide, 2 pills/day of Rifampicine and 3pills/day of Piazoline. Then a 9 months therapy based on Isoniazide and Rifampicine with the same dose. The medical treatment lasted about a year. The evolution was good with a total cure of the breast lesions within a month of treatment.

### Case 2

Z.O. a 43 year old multiparous woman, with a low socio-economical level, was admitted at the Gynaecology Department at Kairouan's Hospital to explore a left breast nodule that appeared recently without any mammal flow or skin inflammatory phenomenon. The patient has no familial history of breast disease. She has a past record of recurrent left mammal abscesses starting three years ago, treated with M penicillin and complicated with a skin fistula. The physical examination finds a woman in a good general condition. The right breast is normal. The inspection of the left breast notices small mammal scars sequelae of the fistula associated with mammal retraction without any other skin hurt (Figure 3). A nodule of about 5 centimetres is palpated in the left breast: it is stony, with unclear limits, movable. There is no mammal flow. A pack of left axillary lymph nodes is also palpated. The mammography associated with a mammal ultra-sonography shows a tissular injury of about 5 centimetres in the left breast highly suspicious of breast cancer ACR5 (Figures 4 and 5).

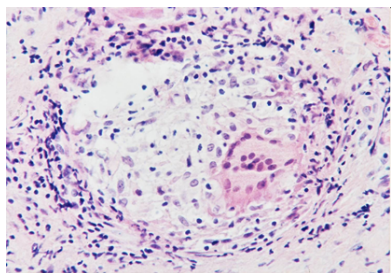
The microscopic examination of the biopsy of the nodule showed a granuloma, with multinucleated giant cells with nuclei arranged like a horseshoe (Langhans giant cells) surrounding the epithelioid infected

**\*Corresponding author:** Fatnassi Ridha, Department of Gynecology and Obstetrics, Ibn El Jazzar Hospital- Kairouan, 3140 Kairouan-Tunisia, Tel: +216 98 451 341; E-mail: [ridha.fatnassimohamed@rns.tn](mailto:ridha.fatnassimohamed@rns.tn)

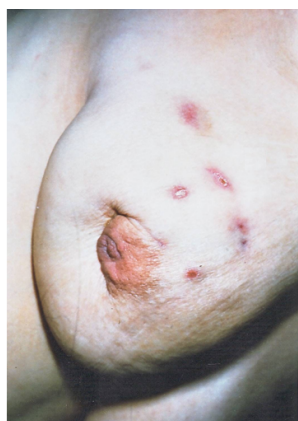**Received** May 30, 2014; **Accepted** July 25, 2014; **Published** July 27, 2014

**Citation:** Fatnassi R, Mkinini I, Kaabia O, Rigmoun H, Hamdi A, et al. (2014) Breast Tuberculosis Report of Two Cases. Gynecol Obstet (Sunnyvale) 4: 229. doi:10.4172/2161-0932.1000229

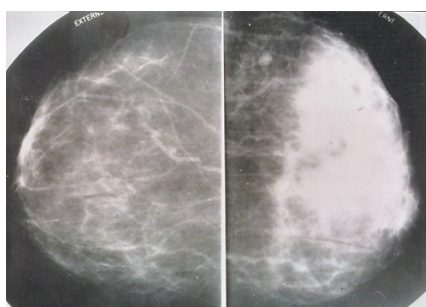
**Copyright:** © 2014 Fatnassi R, et al. This is an open-access article distributed under the terms of the Creative Commons Attribution License, which permits unrestricted use, distribution, and reproduction in any medium, provided the original author and source are credited.



**Figure 2:** A granuloma, with multinucleated giant cells with nuclei arranged like a horseshoe (Langhans giant cells) surrounding the epithelioid infected macrophages without any caseous necrosis in the centre of caseating tubercle. (Case 1).



**Figure 3:** Sequelae of recurrent mammal abscesses.(Case 2).



**Figure 4:** Mammography: A heterogenic denseness of about 5 centimetres with woolly limits in the left breast highly suspicious of breast cancer ACR5. (Case 2).

macrophages with caseous necrosis in the centre of caseating tubercle leading to the diagnosis of breast tuberculosis. The search for other locations of tuberculosis (microbiological culture of three days sample of sputum, chest X-ray and Intra Veinous Urography) was negative. The tuberculin skin test is positive with an induration of about 11 millimetres. The questioning revealed no other case of tuberculosis neither in the family nor at work. The patient has not been inoculated against tuberculosis in youth. She received a one year medical treatment based on anti-tuberculars the same protocol as the previous patient. The evolution was good with a total cure of the breast injuries without any recurrency.

## Discussion

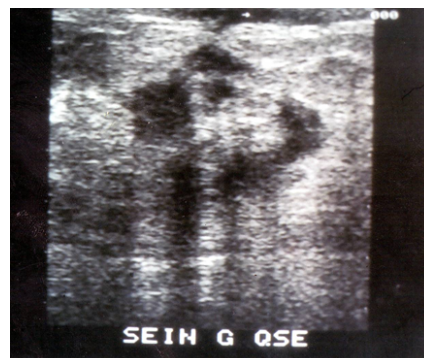The breast tuberculosis is rare. It is the least common visceral location of the infection. In fact, it represents only 1/4000 cases of all surgical affections of the breast. It is exceptional in teenagers, menopausal women and in men (Only 30 cases were ever reported) [2]. It is very common in genitally active women. Pregnancy, breast feeding and multiparity seem to be supporting factors. It is still a recurrent illness in endemic countries, very rare in the West. As it is different from all other kinds of tissues, the mammal tissue is relatively resistant to the MTB [3,4].

The breast tuberculosis is called “primitive” when it is the unique demonstration of the illness. It is the most common cause (case 2). It is “secondary” when it is associated with other rare locations (case 1: breast tuberculosis after a lymphatic one) [2,5]. The breast contagion with blood way; accessory, it can be lymphatic retrograde [6]. Lesions in continuity with the parietal chest ones define the tuberculosis parameters. The skin or galactophoric ways, even possible, are rare. Our first case is remarkable by the age of appearance of the illness and by the fact that it is a “secondary” breast tuberculosis [1,4].

The various symptoms reflect the anatomic abnormalities (galactophorous, ducto-lobular unity) [7,8]; they vary from differential diagnosis of breast cancer to recurrent cold abscesses resistant to nonspecific antibiotics.

- The tuberculosis lobulitis or deep tuberculosis mastitis is due to the injury of glandular tissues. It causes either nodes of various sizes hard or tough with unclear limits, commonly in the Supero-External Quadrant. The injury can be diffuse or sticky to either superficial or deep planes. Some ante-menstrual breast pain can be noticed. The tuberculosis lobulitis can cause cold abscesses leading to skin fistula or miliary in case of generalised granula; the second alternative is very rare.
- The tuberculosis galactophoritis or superficial tuberculosis mastitis is due to the lesion of the galactophore. It is uncommon. It happens in peri-menopausal women. The node, in this case, is associated with mammal retraction. A mammal blood or pus flow can be seen. The evolution into an ulcer with serous or brown flow from a fistula rhythmmed by the periods. Axillar, sus-clavicular or neck lymph nodes are seen in 75% of all cases [6] they are movable, rarely voluminous and bilateral. They can be the first symptom leading the patient to take medical advice. The evolution can last from some weeks to many years [5].

The diagnosis of breast tuberculosis is based on some presumptive



**Figure 5:** The mammal ultra-sonography: Tissular mammal injury heterogenic is containing multiple abscesses. (Case 2).

physical, mammographic and histological signs. Only the microbiological culture and/or the microscopic examination of breast biopsy can confirm the diagnosis. The mammography can show denseness with woolly limits skin thick, sometimes micro-calcifications are noticed [8,9]. These signs are not specific and can set a problem of differential diagnosis with breast cancer. The microbiological examination and/or culture of pus can isolate the *Mycobacterium Tuberculosis*. It is a formal argument for the diagnosis of breast tuberculosis. The germ has not been identified in any of our cases. The microbiological examination and/or culture is positive in only 25 to 30% of all cases according to the literature [7,10,11]. The microscopic examination of the pus can alert if it discovers epithelioid infected macrophages and/or caseous necrosis. Most commonly, the conclusion of the examination is: non-specific inflammatory aspect. The microscopic examination of the breast biopsy confirms the diagnosis with shores of caseous necrosis bordered by a granuloma of multinucleated giant cells with nuclei arranged like a horseshoe (Langhans giant cells) surrounding the epithelioid cells into an inflammatory infiltration.

The treatment of breast tuberculosis includes two parts:

- Medical treatment is based on an association of four anti-tuberculars such as Streptomycine, Isoniazide, Rifampicine and Piazoline during three months that is followed by a nine-month bi-therapy with Isoniazide and Rifampicine. One year of medical treatment is the standard, but sometimes nine months can be sufficient.
- Surgical treatment is very restricted, nowadays, to a cleaning of abscesses or a removal of residual injuries after a well conducted medical treatment to quicken the cure.

## Conclusion

Breast tuberculosis is rare. Multiparity and breast feeding seem to be supporting factors. This disease is characterized by its various symptoms that can set a problem of differential diagnosis with breast cancer. The unquestionable diagnosis is based on the microbiological culture and/or the microscopic examination. The treatment is mainly medical. The cure is generally the standard.

## References

1. Pricop F, Pricop M, Dumetrache F, Pavaleanu M (1996) Mammary tuberculosis of two cases. *RevFrGynecolObstet* 91: 381-382.
2. Gerbal R (1964) A case of breast tuberculosis in women. *These Paris* 665.
3. Rothman GM, Meroz A, Kolkov Z, Lewinski UH (1989) Breast tuberculosis and carcinoma. *Isr J Med Sci* 25: 339-340.
4. Martínez-Parra D, Nevado-Santos M, Meléndez-Guerrero B, García-Solano J, Hierro-Guilmain CC, et al. (1997) Utility of fine-needle aspiration in the diagnosis of granulomatous lesions of the breast. *DiagnCytopathol* 17: 108-114.
5. Harris SH, Khan MA, Khan R, Haque F, Syed A, et al. (2006) Mammary tuberculosis: analysis of thirty-eight patients. *ANZ J Surg* 76: 234-237.
6. Hale JA, Peters GN, Cheek JH (1985) Tuberculosis of the breast: rare but still extant. Review of the literature and report of an additional case. *Am J Surg* 150: 620-624.
7. Guillet JL, Salmon RJ, Durand JC, Pilleron JP (1982) Mammary tuberculosis. *Lancet* 2: 166.
8. Madhusudhan KS, Gamanagatti S (2008) Primary breast tuberculosis masquerading as carcinoma. *Singapore Med J* 49: e3-e5.
9. Mehta G, Mittal A, Verma S (2010) Breast tuberculosis- clinical spectrum and management. *Indian J Surg* 72: 433-437.
10. Geffray L, Moreau X, Abgrall J, Chagnon A (1985) Tuberculous mastitis pseudo neoplastic. *Concours medical* 21: 107-146.
11. Tanrikulu AC, Abakay A, Abakay O, Kapan M (2010) Breast Tuberculosis in Southeast Turkey: Report of 27 Cases. *Breast Care (Basel)* 5: 154-157.