

Bilateral Lacrimal Gland Mantle Cell Lymphoma: A Case Report and Review of the Literature

Cristiana Bellan¹, Polito Maria Sole², Barbarino Marcella², Polito Ennio², Kenneth O Simbiri^{1,4}, Giacomina Massaro-Giordano⁵ and Antonio Giordano^{1,3}

¹Department of Medicine, Surgery Neuroscience and Department of Medical Biotechnologies, University of Siena, Italy

²Anatomical Pathology section, University of Siena, Italy

³Sbarro Institute for Cancer Research and Molecular Medicine & Center for Biotechnology, Temple University Philadelphia PA, USA

⁴Jaramogi Oginga Odinga University of Science and Technology, Bondo, Kenya

⁵Scheie Eye Institute, Philadelphia, USA

*Corresponding author: Kenneth O Simbiri, Molecular Medicine & Center for Biotechnology, Temple University, 431, 1900 N 12th Street, Philadelphia, PA 19122, USA, Tel: 610-883-6071; E-mail: simbirioa@gmail.com

Received date: October 04, 2016; Accepted date: December 05, 2016; Published date: December 12, 2016

Copyright: © 2016 Bellan C, et al. This is an open-access article distributed under the terms of the Creative Commons Attribution License, which permits unrestricted use, distribution, and reproduction in any medium, provided the original author and source are credited.

Abstract

Background: In this report we will describe a case of mantle cell lymphoma (MCL) in the conjunctiva and underlying clinical, histologic, immunological and genetic findings jointly with review of current literature.

Case presentation: Here we report a case of MCL presenting as bilateral conjunctival masses of a period of over four in a 70-year-old man.

Method and results: Histological examination revealed a proliferation of monotonous small-to-medium-sized lymphoid cells with cleaved nuclei in the subconjunctiva. The lymphoid infiltrate expressed CD20, CD5, BCL-2, cyclin D1, and the transcription factor SOX11.

Conclusion: We suggest a more focused approach to differential diagnosis of this cancer, as MCL is a more aggressive disease than other entities. Due to the rarity of this lymphoma a multidisciplinary team is essential to achieve the best therapeutic approach.

Keywords: Lacrimal gland; Ocular adnexal lymphomas; Bilateral conjunctiva

Introduction

Extranodal lymphomas are rare and about 8 percent of them arise from ocular adnexa. Ocular adnexal lymphomas (OAL) involve the tissues and structures surrounding the eye namely conjunctiva, eyelids, lacrimal gland, and orbital connective tissues. Primary or secondary lymphomas account for 55% of all orbital tumors in adult OALs often diagnosed in the 5th to 7th decade of life with female preponderance [1]. The majority of these lymphomas have been characterized as B-cell NHL. About 80-90% of primary OAL are extranodal marginal zone B-cell lymphomas of mucosa-associated lymphoid tissue (MALT) which can arise in the orbit (40%), followed by conjunctiva (35%-40%), lacrimal gland (10%-15%), and eyelid (10%) [1-5].

There is a predisposition toward bilateral involvement (10%-15% of cases), particularly for conjunctival presentations [6,7]. MCL has been identified as an uncommon type of B-cell lymphoma that represents 3-10% of NHLs [1]. It is more frequent in older patients with a male preponderance. Its presence in the ocular adnexa is extremely rare, and only a few cases have been described. MCL represents 1-5% and 9% of the lymphomas the ocular adnexal region [1]. The most commonly involved site of MCL in this region, similar to extranodal marginal zone lymphoma is the orbit followed by the lacrimal gland and the eyelid [1]. We hereby describe a 70-year-old male lacking a history of

lymphoma showing bilateral conjunctival masses that are diagnosed as MCL engaging the ocular adnexa, noted to be a rare cause of orbital and OAL. Consequently, we review the literature to investigate differential diagnoses and potential challenges to current diagnostic procedures.

Case Presentation

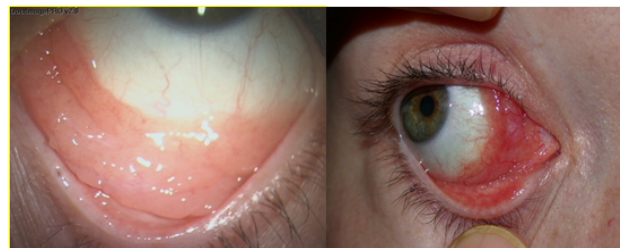


Figure 1: “Salmon pink,” painful masses of the right and left orbits which had been growing over the past four months.

We present a 70-year-old man with a 4-month history of epiphoria treated for nasolacrimal duct obstruction. As it was unresponsive to topical medical therapy, further examinations were performed that showed bilateral rubbery, mobile conjunctival masses (Figure 1). The

masses were firm and sensitive to touch. The patient underwent conjunctival masses biopsy after signed consent approved by the Department of Medicine, University of Siena.

Histological examination showed monotonous small-to-medium sized lymphoid cell proliferation with angulated, hyperchromatic nuclei and limited cytoplasm within a background of hyalinized vessels. The cells infiltrated the subepithelial tissue in a diffuse pattern without nodular architecture. Noted were tumor cells with condensed chromatin, irregular nuclear membranes, and indistinct nucleoli (Figure 2). Plasma cells or immunoblastic cells were rare and the surface epithelium thin showing no evidence of lymphoepithelial lesion. By immunohistochemistry the neoplastic cells were CD20, Bcl-2, and cyclin-D1 positive and were negative for CD5, CD10, and CD23 (Figure 3). The mitotic index (i.e. Ki-67 percent) was 15-20% of the neoplastic cells. During the clinical work-up for staging, a bone marrow biopsy was performed that showed atypical lymphoid aggregates, an indication of possible involvement of a lymphoma.

Chest and abdomen CT revealed no lymph node enlargement. However, there was hepatosplenomegaly. The patient was given chemotherapy consisting of cytoxan, vincristine, and prednisone (CVP).

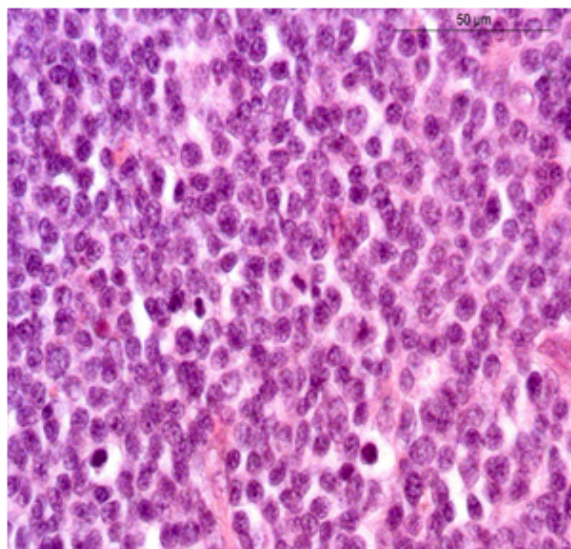


Figure 2: The lacrimal masses showing a monotonous proliferation of small lymphocytes with hyperchromatic angulated nuclei and scant cytoplasm. (H&E; 400× magnification).

Discussion

The lacrimal gland is from the anatomical point of view related to the orbit but embryologically and functionally it is more closely related to the salivary glands. As salivary glands, lacrimal gland have an epithelial structure but following chronic inflammatory disorders can acquire lymphoid tissue (MALT) and as a consequence, it may be prone to an unusually wide range of pathologies including various neoplastic, infective, infiltrative, inflammatory and structural processes ranging from benign adenomas, adenocarcinomas, histiocytosis, benign dacrocysts and sarcoidosis to lymphomas. These lesions can be

very difficult to differentiate both radiologically and pathologically. Imaging, in addition to pathological examination of the lesion, plays an important role in identify a pathological cause and avoid a delay in diagnosis.

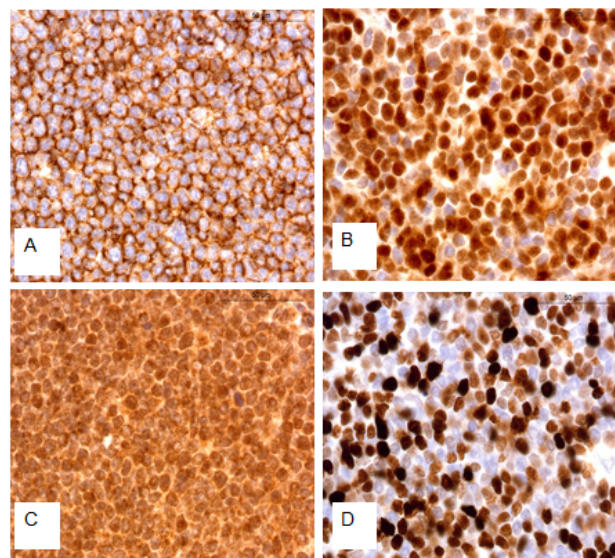


Figure 3: (a) CD20 staining positivity in the neoplastic cells, (b) Cyclin D1 staining positivity in the neoplastic cells and (c) SOX11 positivity. Cyclin D1 and SOX11 positivity is strongly associated with mantle cell lymphoma; (d) proliferation index by KI-67 immunohistochemistry. (400x magnification).

The ocular adnexa include the conjunctiva, eyelids, lacrimal gland, and orbital soft tissues. Lymphomas in this region are rare and account for 1-2% of lymphomas and 8% of the extranodal lymphomas. However, these entities represent 55% of all orbital tumors in adults [4].

The most frequent site of OAL origin is the orbit (40%), followed by conjunctiva (35%-40%), lacrimal gland (10%-15%), and eyelid (10%) [4].

There is a predisposition toward bilateral involvement (10%-15% of cases), particularly for conjunctival presentations [6].

Time from onset of symptoms and diagnosis takes a variable period, ranging from 1 month to 10 years. Probably due to the slow evolution of symptoms, in particular in conjunctival lymphomas, because it can mimic a chronic conjunctivitis and with an impressive initial response to topical steroids [7-12].

The symptoms depend on the localization of the lymphoma. Conjunctival lesions typically present as a painless unilateral "salmon patch" involving the fornix (Figure 1) and mediobulbar conjunctiva [12]. Most patients with conjunctival lymphoid tumors are symptomatic at presentation, generally with minor complaints such as a lump, irritation or ptosis [12].

Although primary ocular adnexal lymphomas are not common, they represent about 6-8% of extranodal lymphomas [4,13]. In particular, the primary involvement of conjunctiva by lymphoma, comprises 28% of OAL [14]. Most of the primary conjunctival

lymphomas, similar to other primary OAL, are low-grade extranodal marginal zone B-cell lymphomas (EMZL) of MALT, and other types of lymphomas are extremely rare according to the World Health Organization classification [14-16].

According to a study on OAL by Ferry et al. around two-thirds of the patients with the less common B-cell adnexal lymphoma subtypes already have a prior history of lymphoma, and in the remaining newly diagnosed one-third, almost all of the patients present with widespread disease by staging.

In general, MCL is a slightly rare type of B cell lymphoma that represents 3-10 percent of the non-Hodgkin mature B cell lymphomas. The median age of incidence of MCL is about 60 years with a male preponderance [1,2] as demonstrated in two studies by Looi et al. and Rasmussen et al. In these study populations ocular adnexa MCL was more common in older men (approximately 6: 1) with a higher male-to-female ratio than systemic MCL [10,11]. In addition, the study of Rasmussen et al. showed a preferential involvement of the orbit and eyelid with a more common bilateral involvement in patients with primary ocular adnexal MCL than in patients with secondary ocular adnexal MCL, associated with a shorter overall survival than patients with secondary ocular adnexal MCL [10]. Clinically, MCL generally presents with extensive lymphadenopathy and splenomegaly. Most of the patients present with advanced Ann Arbor stage IV, accompanied by bone marrow involvement. When MCL involves the orbit and ocular adnexa, the typical clinical presentation is an orbital mass. Possible symptoms are proptosis, diplopia, conjunctival (salmon-pink) swelling, conjunctival redness and irritation, and ptosis caused by involvement of the dermis or the orbicularis muscle of the superior eyelid.

From the histologic point of view, classically there is an infiltration of monomorphic small-to-medium sized lymphoid cells in a diffuse, nodular, or mantle zone pattern, with no admixing centroblast and immunoblast-like cells [10].

The immunohistochemical markers expression in MCL in the ocular region is the same as that in nodal MCL. The expression of CD5 and the lack of expression of CD23, CD10, and bcl-6 are important features useful for distinguishing MCL from other B-cell lymphomas, including small lymphocytic lymphomas (like chronic lymphocytic leukemia which is CD23 positive), follicular lymphomas (which are Bcl6 positive), and marginal zone B-cell lymphomas (MZL). In particular MZL, which rises to the top of the list for lymphomas of ocular adnexal, is positive for CD79a, CD20, CD43 (usually), and IgM. It is typically negative for BCL-2, IgD, CD10, CD23, CD5, and cyclin D1. The lack of expression of cytokeratin by neoplastic cells easily differentiates lymphoid from epithelial proliferation. Cytogenetically, 70-75% of MCL show the t (11; 14) (q13; q32) translocation, involving the Cyclin D1 (CCND1) gene, which results in deregulated overexpression of Cyclin D1 [17]. Therefore, the overexpression of Cyclin D1 is a very useful and specific marker for the diagnosis of MCL [16,18].

The difference between benign and malignant lymphoid proliferations of the orbit and ocular adnexa, requires clinical or radiological criteria of histological, immunological, and molecular analyses [1].

However, the advances made in computed tomography (CT) and magnetic resonance tomography (MRI) techniques have made them better tools for the morphological diagnosis of primary orbital lymphomas. CT is useful in the evaluation of location, size, and degree

of infiltration; however, it cannot reliably distinguish between benign and malignant processes. On CT, orbital lymphoid tumor usually presents as a diffuse, irregular, solid, enhancing mass, molding around adjacent tissues and displacing rather than infiltrating orbital structures [19]. The mass is usually homogeneous in density, either isodense or slightly hyperdense when compared to the extraocular muscles showing, after administration of contrast, only mild to moderate enhancement, similar to the extraocular muscles and lacrimal gland [20-22]. Orbital lymphoid tumor typically does not cause bone destruction except diffuse, large B-cell lymphoma type with aggressive clinical behavior calcification, hemorrhage, and loss of rapid flow through vessels are not observed [23].

On MRI, orbital lymphoid tumors show a low to intermediate signal intensity compared with extraocular muscles on T1-weighted MRI and slight hypointensity or slight hyperintensity on T2-weighted scans. The tumors display homogeneously intermediate to marked enhancement with the administration of contrast agent [23].

In addition to CT and/or MRI, a valuable adjunct in the diagnosis and management of orbital lymphoma is Positron emission tomography (PET) imaging. PET has been used to detect extranodal lymphomatous sites that had not been identified with conventional imaging [24]. Because the indolent EMZL is the most common type of orbital and OAL known to have a low rate of systemic involvement with only localized disease, the gold standard of treatment at that time was mainly radiotherapy [13].

However, MCL although rare in the orbit and ocular adnexal regions, is considered an aggressive neoplasm. Thus, the standard care of orbital and ocular adnexal MCL, which is usually presented at an advanced stage, as in our case, has been limited to palliative systemic chemotherapy. Conventional chemotherapy includes cyclophosphamide, vincristine, prednisone; cyclophosphamide, hydroxyl-daunorubicin, vincristine, prednisone; or mitoxantrone, chlorambucil, and prednisone. Treatment with a combination of systemic chemotherapy plus rituximab has been shown to increase response rates, but progression free survival (PFS) and overall survival (OS) figures are still being evaluated [13]. The clinical outcome of patients with MCL of the orbit and ocular adnexa is characterised by poor survival [8,10]. Furthermore, Rasmussen et al. indicate that bone marrow involvement was seen more frequently in patients with primary ocular adnexal MCL (79%) than in those with secondary ocular adnexal MCL (57%) [10].

In this case report of a 70-year-old man presenting with an initial misdiagnosis of nasolacrimal duct obstruction the lymphoma was noticed. As it was unresponsive to standard medical treatment more thorough examinations were performed and trivial lesions were detected.

The case is a fine clinical example of how diagnostic pitfalls can occur and greatly impact the clinical management of a patient. Therefore, this case emphasizes the importance of a multidisciplinary approach starting with the clinical and radiological criteria and ending with histological, immunological, and genomic analyses [1]. Thus, rare type of malignant lymphomas such as MCL of the orbit and ocular adnexa can occur and are associated with advanced-stage disease and short overall survival than extranodal marginal zone lymphoma (EMZL), the most common lymphoma in the ocular adnexal region [25].

Hence, the accurate diagnosis of orbital and ocular adnexal lymphomas, as well as other hematopoietic entities, require close team

approach between clinicians, radiologists, and pathologists, due to the rarity of these lymphomas.

References

1. Coupland SE, Krause L, Delecluse HJ, Anagnostopoulos I, Foss HD, et al. (1998) Lymphoproliferative lesions of the ocular adnexa. Analysis of 112 cases. *Ophthalmology* 105: 1430-1441.
2. Ferry JA, Fung CY, Zukerberg L, Lucarelli MJ, Hasserjian RP et al. (2007) Lymphoma of the ocular adnexa: a study of 353 cases. *Am J Surg Pathol* 31: 170-184.
3. Rootman DB, Mavrikakis I, Connors JM, Rootman J (2011) Primary, unilateral ocular adnexal lymphoma: disease progression and long-term survival. *Ophthal Plast Reconstr Surg* 27: 405-409.
4. Moslehi R, Devesa SS, Schairer C, Fraumeni JF Jr (2006) Rapidly increasing incidence of ocular non-hodgkin lymphoma. *J Natl Cancer Inst* 98: 936-939.
5. Galieni P, Polito E, Leccisotti A, Marotta G, Lasi S, et al. (1997) Localized orbital lymphoma. *Haematologica* 82: 436-439.
6. Vali Khojeini E, Durham BH, Chen M (2013) Mantle cell lymphoma and involvement of the orbit and ocular adnexa. *Case Rep Pathol* 2013: 581856.
7. Cahill M, Barnes C, Moriarty P, Daly P, Kennedy S (1999) Ocular adnexal lymphoma-comparison of MALT lymphoma with other histological types. *Br J Ophthalmol* 83: 742-747.
8. Nola M, Lukenda A, Bollmann M, Kalauz M, Petroveckí M, et al. (2004) Outcome and prognostic factors in ocular adnexal lymphoma. *Croat Med J* 45: 328-332.
9. Coupland SE, Hellmich M, Auw-Haedrich C, Lee WR, Stein H (2004) Prognostic value of cell-cycle markers in ocular adnexal lymphoma: an assessment of 230 cases. *Graefes Arch Clin Exp Ophthalmol* 242: 130-145.
10. Rasmussen P, Sjö LD, Prause JU, Ralfkiaer E, Heegaard S (2009) Mantle cell lymphoma in the orbital and adnexal region. *Br J Ophthalmol* 93: 1047-1051.
11. Looi A, Gascoyne RD, Chhanabhai M, Connors JM, Rootman J et al. (2005) Mantle cell lymphoma in the ocular adnexal region. *Ophthalmology* 112: 114-119.
12. Shields CL, Shields JA, Carvalho C, Rundle P, Smith AF (2001) Conjunctival lymphoid tumors: clinical analysis of 117 cases and relationship to systemic lymphoma. *Ophthalmology* 108: 979-984.
13. Hatf E, Roberts D, McLaughlin P, Pro B, Esmali B (2007) Prevalence and nature of systemic involvement and stage at initial examination in patients with orbital and ocular. *Arch Ophthalmol* 125: 1663-1667.
14. Ferreri AJ, Govi S, Colucci A, Crotchiolo R, Modorati G (2011) Intralesional rituximab: a new therapeutic approach for patients with conjunctival lymphomas. *Ophthalmology* 118: 24-28.
15. Thieblemont C, Bertoni F, Copie-Bergman C, Ferreri AJ, Ponzoni M (2013) Chronic inflammation and extra-nodal marginal-zone lymphomas of MALT-type. *Semin Cancer Biol* 24: 33-42.
16. Swerdlow SH, Berger F, Isaacson PI, Muller-Hermelink HK (2008) Mantle cell lymphoma, in: Jaffe ES, Harris NL, Stein H, Vardiman J (Eds), *Pathology & Genetics Tumours of Haematopoietic and Lymphoid Tissues*, World Health Organization Classification of Tumours (WHO), IARC Press, Lyon.
17. Vandenbergh E, De Wolf-Peeters C, Vaughan Hudson G, Vaughan Hudson B, Pittaluga S, et al. (1997) The clinical outcome of 65 cases of mantle cell lymphoma initially treated with non-intensive therapy by the British National Lymphoma Investigation Group. *Br J Haematol* 99: 842-847.
18. Sander B (2011) Mantle cell lymphoma: recent insights into pathogenesis, clinical variability, and new diagnostic markers. *Semin Diagn Pathol* 28: 245-255.
19. Polito E, Galieni P, Leccisotti A (1996) Clinical and radiological presentation of 95 orbital lymphoid tumors. *Graefes Arch Clin Exp Ophthalmol* 234: 504-509.
20. Maksimovic O, Bethge WA, Pintoffl JP, Vogel M, Claussen CD, et al. (2008) Marginal zone B-cell non-Hodgkin's lymphoma of mucosa-associated lymphoid tissue type: imaging findings. *AJR Am J Roentgenol* 191: 921-30.
21. Wang JC, Netra R, Yuan W, Ma S, Li M, et al. (2010) CT and MRI features of Primary Orbital Lymphoma: review of 14 cases. *Asian J Med Sci* 1: 87-90.
22. Akansel G, Hendrix L, Erickson BA, Demirci A, Papke A, et al. (2005) MRI patterns in orbital malignant lymphoma and atypical lymphocytic infiltrates. *Eur J Radiol* 53: 175-181.
23. Lemke AJ, Hosten N, Neumann K, Grote A, Felix R (1995) Space-occupying lesions of the lacrimal gland in CT and MRI exemplified by 4 cases. *Aktuelle Radiol* 5: 363-366.
24. Valenzuela AA, Allen C, Grimes D, Wong D, Sullivan TJ (2006) Positron emission tomography in the detection and staging of ocular adnexal lymphoproliferative disease. *Ophthalmology* 113: 2331-2337.
25. Yoo SB, Kim YA, Jeon YK, Kim CW (2008) CD5-undetected by immunohistochemistry, t(11;14)(q13;q32)-positive conjunctival mantle cell lymphoma: a case report. *Pathol Res Pract* 204: 779-783.