

Bacterial Etiology of Necrotic Arachnidism in Black Widow Spider Bites

Bradley Ahrens^{1*} and Carlos Crocker^{1,2}

¹Western University of Health Sciences, College of Veterinary Medicine, Pomona, CA

²St. Matthew's University, College of Veterinary Medicine, Grand Cayman, Cayman Islands, BWI

Abstract

Spider bites are a common challenge for physicians and veterinarians worldwide. Envenomation by the Western Black Widow (*Latrodectus hesperus*) is frequently associated with a necrotic cutaneous reaction at the bite site; a condition known as necrotic arachnidism. Although the composition of venom is known to be almost entirely neurotoxic, and thus, presumably not damaging to skin, varying degrees of dermal necrosis are commonly encountered at the site of envenomation. The underlying mechanism is unknown, prompting our investigation of the possibility for a bacterial etiology of the local lesions associated with the bite.

This descriptive study reports the presence of 5 uncommon, highly pathogenic; multiple antibiotic resistant, bacterial species cultured from 220 pairs of sterilely extracted black widow spider fangs. This finding is consistent with the known unresponsiveness of cutaneous spider bite lesions to steroids and first-line antibiotic treatment; which has led to the misconception that the venom is the causative agent.

This discovery supports our hypothesis that bacterial strains have adapted to life on the fangs of certain spiders; providing them with an excellent mode of infection by not only being passed subcutaneously to the victim, but also protected from host defenses by the immunosuppressive effects of the venom.

Since current treatment protocols for spider envenomations concentrate almost solely on the local and systemic effects of the venom itself, our findings suggest that the current diagnostic algorithm and treatment standards for spider bites in both human and animal medicine may be inadequate and should be re-assessed.

Keywords: Black Widow; *Latrodectus*; Necrosis; Bacteria; Arachnidism; Antibiotics

Introduction

Spider bites meriting medical intervention on the west coast are surprisingly common. In 2008, there were over 12,500 reported bites on humans, with over 2,500 from widow spiders [1]. (The actual number of bites potentially being far greater because of lack of reporting) [2]. Spider bites are very difficult to treat for physicians, veterinarians, and patients. Diagnosis is also a challenge because the spider culprit is rarely found or caught, and the bite produces a number of nonspecific signs with a long list of differentials.

Spiders are arthropods of the class: *Arachnida*, order: *Araneae*. Black widows are members of the family Theridiidae (cobweb spiders). The genus *Latrodectus* contains 31 species inhabiting every continent except Antarctica [3]. All species in the genus are medically important and bites result in a potentially fatal clinical syndrome known as latrodectism. The widows are responsible for killing more people per year, worldwide, than any other spider. The venom is rapidly carried by the lymphatic system to the blood stream. Once in circulation, the toxins are deposited in neuronal synapses and neuromuscular junctions and death is most commonly due to cardiovascular collapse or respiratory paralysis.

Venom is produced in glands in the cephalothorax [4]. It is passed down through the chelicerae to a pair of hollow fangs which inject the venom into the prey [5]. In the United States, members of 7 spider families may be responsible for envenomation sufficiently severe to warrant treatment, and only 3 of those, including black widows, are associated with necrotic arachnidism (*Loxosceles reclusa* and *Tegenaria agrestis*) [6].

Compared to many other species of spiders, their chelicerae are not very large. In the case of a mature female, the hollow, needle shaped part of each chelicerae, (the part that penetrates the skin) is approximately 1

mm long which is sufficiently long to inject the venom to a dangerous depth. The males, being much smaller, can only inject a minute amount to a lesser depth, thus making them medically insignificant. The actual amount of venom injected per bite, even by a mature female, is very small in actual volume (.02-.03 mg) [7,8]. However, with an extremely high LD50 of 0.002 mg/kg, [7-9] even this tiny amount can be fatal.

The venom of *Latrodectus* contains a multitude of harmful proteinaceous and non-proteinaceous constituents which affect neuromuscular endplates and central nervous system synapses. It even contains 5-hydroxytryptamine (serotonin) [10,11]presumably for the sole purpose of inducing pain [12]. One of the especially harmful proteins in the venom is α -latrotoxin which binds to presynaptic cholinergic receptors of vertebrates and induces massive neurotransmitter exocytosis from central and peripheral nerve terminals [13]. Initially the venom causes small end-plate potentials, but soon results in a complete block in neurotransmission due to depletion of neurotransmitters from terminal synaptic vesicles. This complex action seems to result from glycoproteins and/or gangliosides on the neuromuscular synaptic membranes, thus allowing a channel to form for monovalent cation exchange that locks open. This depolarization promotes calcium-independent release of neurotransmitters down concentration gradients, then inhibits their subsequent reuptake.

***Corresponding author:** Bradley Ahrens, Western University of Health Sciences, College of Veterinary Medicine, Pomona, CA, E-mail: bahrens@westernu.edu

Received September 22, 2011; **Accepted** November 03, 2011; **Published** November 10, 2011

Citation: Ahrens B, Crocker C (2011) Bacterial Etiology of Necrotic Arachnidism in Black Widow Spider Bites. J Clin Toxicol 1:106. doi:10.4172/2161-0495.1000106

Copyright: © 2011 Ahrens B, et al. This is an open-access article distributed under the terms of the Creative Commons Attribution License, which permits unrestricted use, distribution, and reproduction in any medium, provided the original author and source are credited.

Acetylcholine, norepinephrine, dopamine, glutamate, and enkephalin systems are all susceptible to this toxin [9,11,13].

The systemic effects and symptoms of black widow envenomation include: severe pain, nausea, tachycardia, myocarditis, hypertension, pyrexia, dyspnea, vomiting, muscle weakness, rigidity, spasm, cramping and tetany, hyperreflexia, paresthesia, salivation, lacrimation, diaphoresis, seizures, anaphylaxis, shock, cardiac arrest, coma and death [9,14,15]. The venom also frequently causes priapism [16], and has a degree of affinity for the facial musculature which can cause extreme facial contortions; this is a condition known as *facies latrodectismi* [17]. Interestingly, the venom has also been found to have immunosuppressive effects which could potentiate complications such as infection [9,18].

At or near the site of envenomation, lesions can range from rash, erythema, and edema to severe inflammation, infection, and necrosis. Blanching and cyanosis slowly develop at the central core with spreading erythema and progression to dermonecrosis [9].

Common differentials for necrotic arachnidism are: pyoderma gangrenosum, staphylococcus and streptococcus infections, herpes, diabetic ulcers, fungal infections, chemical burns, toxicodendron dermatitis, squamous cell carcinomas, vasculitis, syphilis, toxic epidermal necrolysis, sporotrichosis, and lyme disease [2].

Necrotic arachnidism is the term for the cutaneous reaction from the spider bite and it is associated with vasodilation, ischemia, and thrombosis with occasional progressive necrotic lesions. While some of the local skin reactions which are manifested as a result of envenomation like edema and erythema are caused directly by constituents of the venom due to (among other things) the lytic action of various enzymes (such as hyaluronidase), it is currently assumed that the dermonecrosis is most likely due to an immune response to the venom, if not enzymes in the venom itself [18].

Our recent findings, however, suggest that the current understanding of necrotic arachnidism may be inaccurate and that several species of pathogenic, antibiotic resistant bacteria on the fangs of the spiders could potentially be inoculated during the spider bite and cause primary cutaneous lesions.

The objectives of this descriptive study were: (1) to determine if there are bacterial species living on the fangs of black widow spiders, (2) if these bacteria are medically significant and associated with disease, and (3) what antibiotics these bacteria are sensitive and resistant to.

Materials and Methods

Materials

220 adult female Western Black Widows spiders (*Latrodectus hesperus*) were collected from California State Polytechnic University, Pomona (34° 03' 17.66 N 117° 49' 42.85 W Elev. 829) during nighttime hours between 10:00 PM and 2:00 AM. Large specimens (above 100mg) with no overt signs of disease were collected into sterile specimen containers then taken back to the lab and examined for missing limbs, external parasites, fungal infections, malnourishment, and dehydration. Any spiders not meeting these criteria were returned to the locations where they were found.

The spiders were kept in our lab at Western University of Health Sciences College of Veterinary Medicine in individual, autoclaved sterile, 30cm³ screw top plastic containers. They were provided a 12 hour light/12 hour dark photoperiod, maintained at 24.0±2.0° C 24h/day, and provided water through holes in the lid of each container.

In preparation for the fang extraction procedure, we autoclaved surgical packs containing 8 towels, and 4 sets of: bridge forceps, Jacobson micro artery forceps, and Joseph rhinoplasty micro scissors.

The spiders were euthanized using an open drop technique with 100µl isoflurane in a 35ml container resulting in a 7% anesthetic concentration. The spiders were then left in their chambers for 30 minutes to ensure complete and humane euthanasia. Previous studies have shown that isoflurane does not affect bacterial growth [20].

Surgical procedure

Standard surgical aseptic technique was followed for the surgical extraction procedure which included proper scrubbing and gowning with autoclaved surgical robes, caps, masks, and sterile gloves.

To ensure a sterile surgical field, a sterile towel was placed over the microscope base. The sterile surgical pack was then placed over the towel and properly opened revealing the instruments and 8 folded sterile towels. The spiders were placed on the towel under the microscope field in dorsal recumbency. The towels were folded in a manner which provided us with 4 rectangular fields separated by creases. After the fangs were excised, each subsequent spider was placed in a new field to avoid contamination by the previous spider's body. Using the dissecting microscope (Tritech Stereo-Microscope System w/optics and Tritex fiber optic external illuminator) the spiders were carefully manipulated into position by the left fang using the sterile forceps and the fangs were removed using one cut with the microscissors at the level of the base of the chelicerae. This technique prevented any expulsion of endolymph which could contaminate the samples, as well as kept the instruments clean having only touched the fang. When accidental expulsion of endolymph or accidental contamination by the rest of the body occurred, forceps and scissors were exchanged for new sterile ones, and the fangs were discarded. Additionally, instruments were switched out every 10 spiders. After excising the fangs, they were dropped directly into sterile culture media tubes. Once 10 pairs of fangs were dropped into each tube, they were sealed and submitted to Antech Diagnostics (Irvine, CA) for aerobic and anaerobic bacterial cultures and sensitivity testing.

Results

Of the 22 culturettes (each containing 10 pairs of fangs) submitted to Antech Diagnostics over the 3 month period, we received 2 positives for *Morganella morganii*, 2 positive for *Capnocytophaga*, 1 positive for *Citrobacter amalonaticus*, 1 positive for *Pantoea agglomerans*, 1 positive for *Pseudomonas* spp., 7 Positive for *Enterococcus* spp., and 3 positive for *Bacillus* spp. (non *anthracis*). This gives us a total of 17 positives out of 22 samples for a prevalence of 77%.

(Figure 1) *Morganella morganii* sensitivity testing showed resistance to: amoxicillin, ampicillin, cephadroxil, cefazolin, cefoxitin, cefpodoxime, cephalixin and Clavamox. It showed intermediate resistance to: ceftiofur, and susceptibility to amikacin, difloxacin, enrofloxacin, gentamycin, marbofloxacin, and potentiated sulfonamides.

Capnocytophaga is anaerobic, so sensitivity testing was not performed.

Citrobacter amalonaticus sensitivity testing showed resistance to: cephadroxil, cefazolin, and cephalixin. It showed intermediate resistance to: ceftiofur, and susceptibility to amikacin, amoxicillin, ampicillin, aefoxitin, cefpodoxime, Clavamox, difloxacin, enrofloxacin, gentamycin, marbofloxacin, and potentiates sulfonamides.

Pantoea agglomerans sensitivity testing showed resistance to: cephadroxil, cefoxitin, and cephalixin. It showed intermediate resistance to: cefazolin, and ceftiofur, and susceptibility to: amikacin, amoxicillin, ampicillin, cefpodoxime, Clavamox, difloxacin, enrofloxacin, gentamycin, marbofloxacin, and potentiates sulfonamides.

Pseudomonas sensitivity testing showed resistance to: amoxicillin, ampicillin, cephadroxil, cefazolin, cefoxitin, cefpodoxime, ceftiofur, cephalixin, Clavamox, cefovicin, and potentiated sulfonamides. It showed susceptibility to: amikacin, enrofloxacin, gentamycin, and marbofloxacin.

All of the *Enterococcus* sensitivity testing showed susceptibility to all tested antibiotics (ampicillin, amoxicillin, azithromycin, chloramphenicol, clarithromycin, doxycycline, enrofloxacin, erythromycin, gentamycin (high conc.), marbofloxacin, and streptomycin (High conc.). However, Antech made a point to remark that cephalosporins, and potentiated sulfonamides, are not tested because they are always ineffective against enterococci, and aminoglycosides used alone are also ineffective.

One strain of isolated *Enterococcus* demonstrated intermediate resistance to chloramphenicol, clarithromycin, erythromycin, and marbofloxacin.

Figure 2 depicts a quantitative assessment of the efficacy of antibiotics against the isolated bacteria. As evidenced by the figure, enrofloxacin, marbofloxacin, amikacin, difloxacin, and gentamycin have shown to be overall the most effective antibiotics against these bacteria.

Discussion

The 5 medically significant bacteria isolated were: *Morganella morganii*, *Capnocytophaga*, *Citrobacter amalonaticus*, *Pantoea agglomerans* and *Pseudomonas* (Figure 1).

Morganella morganii is one of the most common isolates from snakebite infections, and has also been found in several forms of serious gangrenous skin infections including ecthyma gangrenosum. The necrotizing lesions secondary to bites are often attributed to *Morganella* [22-26].

Capnocytophaga is another highly pathogenic bacteria which is most frequently found in dog bite wounds. Even minor bites are known to cause serious disease, and infections from this bacteria can lead to several life threatening and fatal syndromes. *Capnocytophaga* is a common cause of septicemia, gangrene, purpura fulminans, and other necrotizing skin and eye diseases. It has also been shown to cause hemolytic uremic syndrome, and multisystem organ failure [27-34].

Citrobacter amalonaticus is yet another bacteria we isolated which causes potentially fatal bacteremias, and enteric fevers [35,36,37]. Similarly, the next bacteria, *Pantoea agglomerans*, is known to cause abscesses, bacteremia, bacterial synovitis, peritonitis, pleuritis, and urinary-tract infections [38].

Our final pathogenic bacterial isolate, *Pseudomonas*, is well known to the medical community for causing a wide range of serious conditions from urinary tract infections to meningitis. These include but are not limited to: septic shock, necrotizing skin lesions, and several types of fatal organ infections. *Pseudomonas* has also been cultured from infected bite wounds from other animal species [39-41].

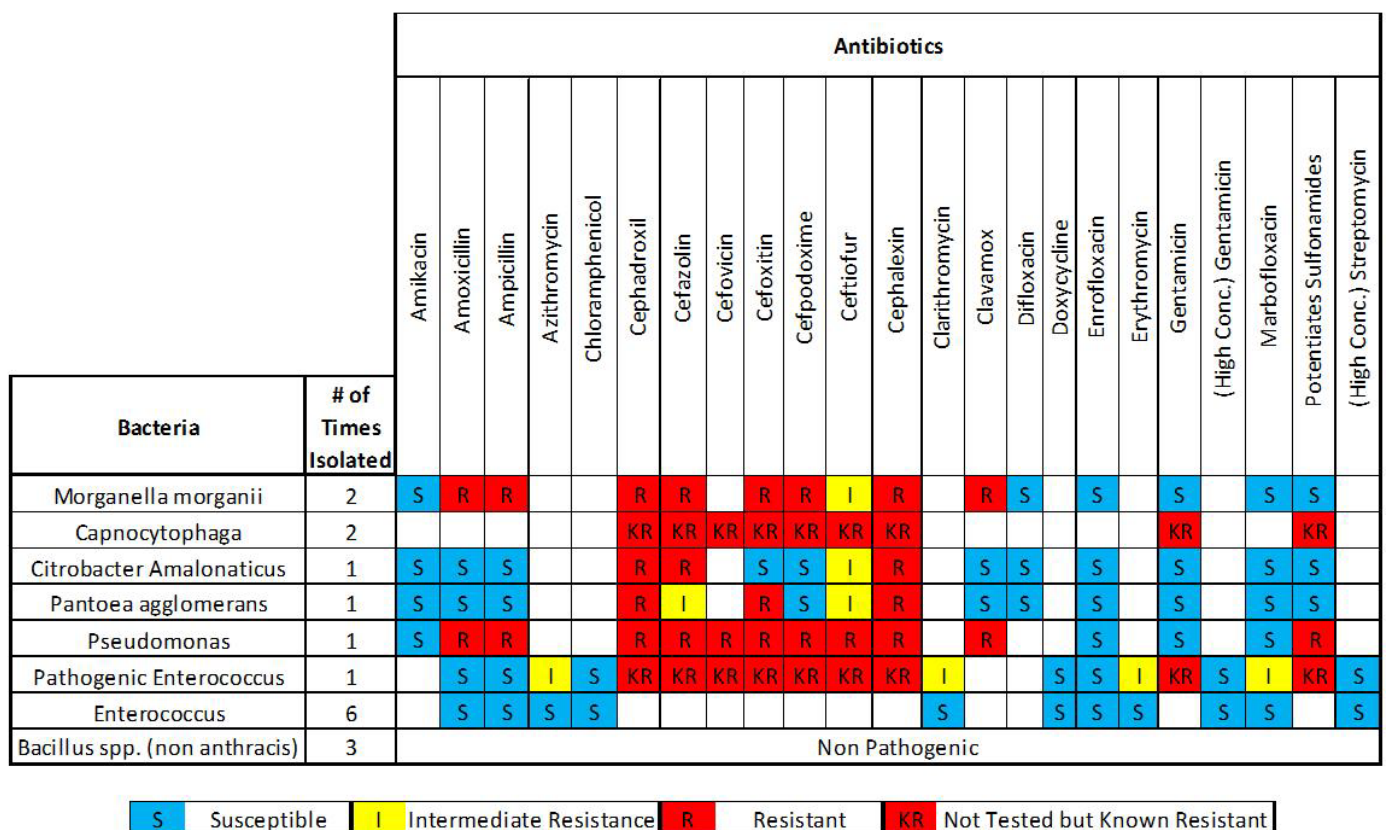


Figure 1: Antibiotic Sensitivities for 8 bacteria isolated from black widow fang cultures.

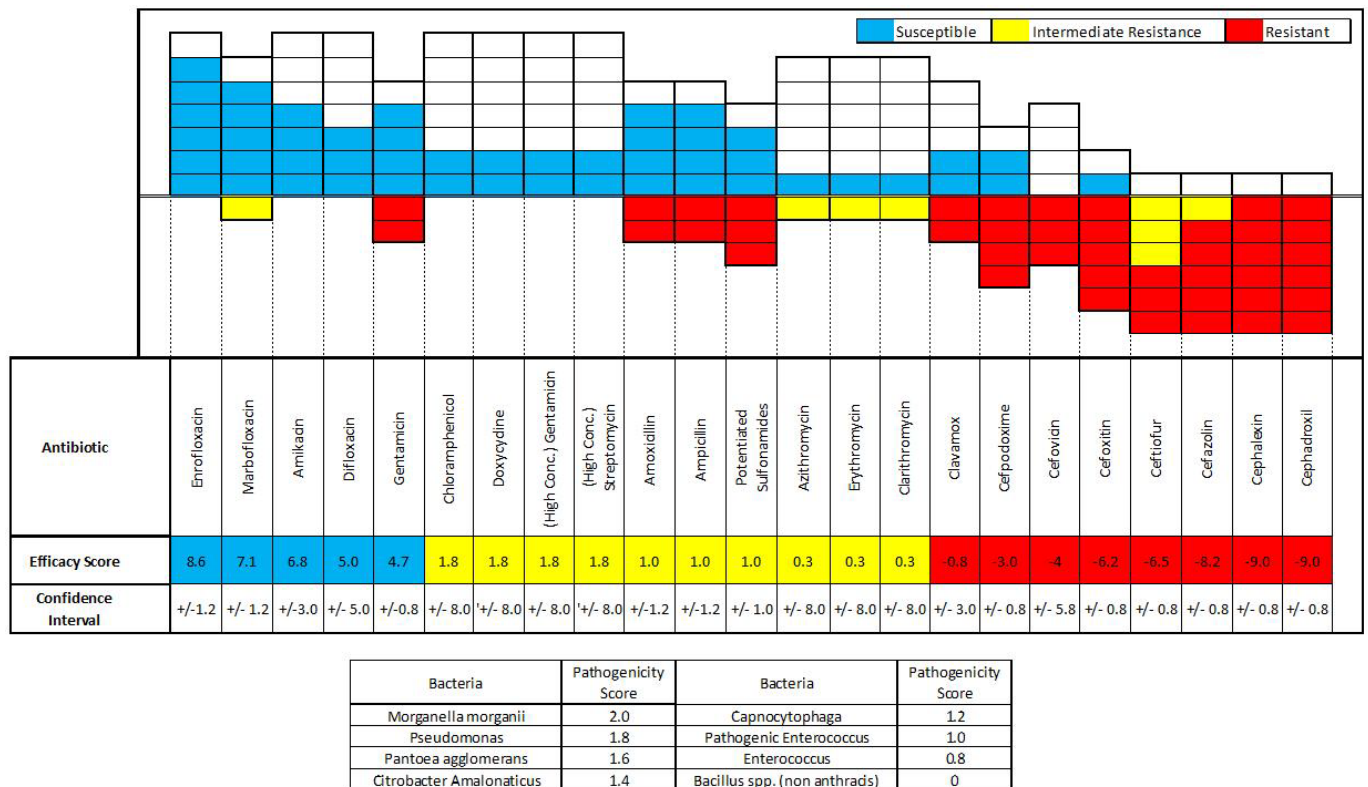


Figure 2: Graphical representation of antibiotic efficacy against Black Widow fang bacteria. The 8 isolated bacteria were ranked by pathogenicity and given an arbitrary numerical value starting with 2.0 (for the most pathogenic) and decreasing in increments of 0.2 for each subsequent species. An efficacy score was calculated for each antibiotic by summing the pathogenicity scores for all bacteria the antibiotic was efficacious against, then subtracting the score for any bacteria resistant to that antibiotic and subtracting half the score for any bacteria that showed intermediate resistance. Finally, a confidence interval was calculated by adding the pathogenicity scores for all the bacteria not tested against that particular antibiotic.

In the medical community, spiders are convenient scapegoats for a variety of symptoms; namely the idiopathic, inflammatory, skin lesion. Over half of all documented cases of necrotic arachnidism in the medical literature are concluded without any substantiating evidence and present from areas where the suspected spider isn't even found [1].

A great number of physicians and veterinarians alike are frustrated at the frequency that patients present with a skin lesion of unknown origin that they or their family physician hastily attributes to "a spider bite." The general consensus within the doctors and researchers that deal with the epidemiology of spider bites is that family physicians and the average public vastly over-diagnose spider bites for just about any idiopathic lesion of the skin [4]. In most cases, when the patient sees a specialist, it is determined that they have a skin or soft tissue infection [2,18].

However, our findings suggest that the primary etiology of spider bite-associated dermonecroses may in fact be bacterial, and these unsubstantiated conclusions are potentially correct. This means many of these "misdiagnosed" spider bite lesions, which turn out to be skin or soft tissue infections, may in fact be accurately diagnosed spider envenomations.

Our results also offer a potential explanation for the traditional unresponsiveness of spider bite lesions to antibiotics since some of the most commonly prescribed antibiotics for skin infections are cephalosporins and β -Lactams [21]– which our findings show have little to no effect on most of these bacteria. Amazingly, many current

treatment protocols do not even include antibiotics because their efficacy against spider bites was previously unsubstantiated [15,42,43].

Conclusion

Given our results we opine that fluoroquinolones and aminoglycosides appear to be the most efficacious antibiotics against the spectrum of bacteria found on Black Widow fangs. When possible, these antibiotics should be considered in the treatment protocol for spider envenomations, (especially those from black widows) to potentially help decrease the risk of necrotic arachnidism and secondary infections.

Acknowledgements

We would like to acknowledge and extend our gratitude to Morris Animal Foundation for their generous contribution to our research, Banfield Animal Hospital at Western University for donating all the surgical supplies, Cal Poly Pomona for allowing us to collect our specimens from their campus, and Antech Diagnostics (Irvine, CA) for performing all the cultures and sensitivities. We are especially grateful to Lauren Kriesberg, Kursten Roderick, and Sara Goetze for their time and assistance in the lab.

References

- Bronstein A, Spyker D, Cantilena L, Green J, Rumack B, Giffin S (2009) 2008 Annual Report of the American Association of Poison Control Centers' National Poison Data System (NPDS): 26th Annual Report. Clinical Toxicology 47: 911–1084.
- Vetter R, Swanson D (2007) Of Spiders and Zebras: Publication of Inadequately Documented Loxoscelism Case Reports. J Am Acad Dermatol 56: 1063-1064.
- Swanson D, Vetter R (2005) Bites of Brown Recluse Spiders and Suspected Necrotic Arachnidism. N Engl J Med 352:700-707.

4. Vetter R, Furbee R (2006) Caveats in Interpreting Poison Control Center Data in Spider Bite Epidemiology Studies. J Royal Institute of Public Health 120: 179-181.
5. Lewbart GA (2006) Invertebrate Medicine.(1ST edition), Blackwell Publishing, Ames, Iowa.
6. Farhat DW (2000) Topics in Emergency Medicine. Arachnidism 22-2: 1-15.
7. Bettini S (1964) Epidemiology of Latrodectism. Toxicol 104: 93-102.
8. Stewart, C (1998) Beyond the Road: Environmental Emergencies for Emergency Service Providers. Charles Stewart and Associates.
9. Bonnet MS (2004) The Toxicology of *Latrodectus tredecimguttatus*: The Mediterranean Black Widow Spider. Homeopathy 93: 27-33.
10. Bryant SM (2003) Dapsone Use in *Loxosceles reclusa* Envenomation: is there an Indication? Am J Emerg Med 21: 89-90.
11. Tu AT (1977) Spider venoms. In: Tu AT (ed) Venoms: Chemistry and Molecular Biology. John Wiley & Sons, New York.
12. Pansa M, Natalizi G, Bettini S (1972) 5-Hydroxytryptamine content of *Latrodectus mactans tredecimguttatus* venom from gland extracts. Toxicol 10: 85-86.
13. McCrone JD (1969) Spider venoms: biochemical aspects. Am Zool 9: 153-156.
14. Vetter R, Isbister G (2008) Medical Aspects of Spider Bites. Annu Rev Entomol 53: 409-429.
15. Peterson M (2006) Black Widow Spider Envenomation. J Clin Tech in Small Animal Practice 21 : 187-190.
16. Diaz J, Leblanc K (2007) Common Spider Bites. Am Fam Physician 75: 869-873.
17. Quan D, Ruha A(2009) Priapism associated with *Latrodectus mactans* envenomation. American Journal of Emergency Medicine. 27: 759 e1-e2.
18. (1996) Necrotic Arachnidism. Med Sci Bull 18 : 4.
19. Suchard JR(2009) "Spider Bite" Lesions are Usually Diagnosed as Skin and Soft-Tissue Infections. The Journal of Emergency Medicine 10: 1016.
20. Asehounne K, Cruaud P, Paries J, Gorce P, Pourriat J (2000) Effects of Isoflurane on Bacterial Growth. Eur J Anaesthesiol 17: 289-294.
21. Stulbery D, Penrod M, Blatny R (2002) Common Bacterial Skin Infections. Am Fam Physician 66:119-125.
22. Chen CM, Wu KG, Chen CJ, Wang CM (2011) Bacterial infection in association with snakebite: A 10-year experience in a northern Taiwan medical center. J Microbiol Immunol Infect.
23. Soleimani S, Gordon NC, Wareham DW (2011) Polymicrobial necrotizing fasciitis involving enterobacteria producing CTX-M-15 extended-spectrum β -lactamases. J Medical Microbiology 60: 135-137
24. Shek KC, Tsui KL, Lam KK, Crow P, Ng KH, et al. (2009) Oral bacterial flora of the Chinese cobra (*Naja atra*) and bamboo pit viper (*Trimeresurus albolabris*) in Hong Kong SAR, China. Hong Kong Med J 15: 183-190.
25. Ciszowski K, Hartwich A (2004) Envenoming by Malayan cobra (*Naja naja sputatrix*)--case report. Przegl Lek 61: 421-426.
26. Del Pozo J, García-Silva J, Almagro M, Martínez W, Nicolas R, et al. (1998) Ecthyma gangrenosum-like eruption associated with *Morganella morganii* infection. Br J Dermatol 139: 520-521.
27. Völl K, Haase G, Fritz H, Riebe J, Huszka C, et al. (2007) Septic Shock with Purpura Fulminans After a Dog Bite. Dtsch Med Wochenschr 132: 1321-1324.
28. Deshmukh PM, Camp CJ, Rose FB, Narayanan S (2004) Capnocytophaga canimorsus sepsis with purpura fulminans and symmetrical gangrene following a dog bite in a shelter employee. Am J Med Sci. 327: 369-372.
29. Tobé TJ, Franssen CF, Zijlstra JG, de Jong PE, Stegeman CA (1999) Hemolytic uremic syndrome due to *Capnocytophaga canimorsus* bacteremia after a dog bite. Am J Kidney Dis 33: e5.
30. Hermann CK, Hansen PB (1998) Multiorgan failure and peripheral gangrene following a superficial dog bite. Ugeskr Laeger 160: 4907-4908.
31. Mellor DJ, Bhandari S, Kerr K, Bodenham AR (1997) Man's best friend: life threatening sepsis after minor dog bite. BMJ 314: 129-130.
32. Quilichini R, Zanlucchi S, Baume D, Pichot de Champfleury M, Sansot D, et al. (1998) Beware of the dog! A syndrome resembling thrombotic thrombocytopenic purpura associated with *Capnocytophaga canimorsus* septicemia. Rev Med Interne 19: 451-2.
33. Kullberg BJ, Westendorp RG, Van T, Wout JW, Meinders AE (1991) Purpura fulminans and symmetrical peripheral gangrene caused by *Capnocytophaga canimorsus* (formerly DF-2) septicemia--a complication of dog bite. Medicine (Baltimore) 70: 287-92.
34. Heidemann DG, Pflugfelder SC, Kronish J, Alfonso EC, Dunn SP, et al. (1988) Necrotizing keratitis caused by *Capnocytophaga ochracea*. Am J Ophthalmol. 105: 655-660.
35. Lai CC, Tan CK, Lin SH, Liu WL, Liao CH, et al. (2010) Bacteraemia caused by non-freundii, non-koseri *Citrobacter* species in Taiwan. J Hosp Infect 76: 332-335.
36. Aschbacher R, Pagani L, Doumith M, Pike R, Woodford N, et al. (2011) Metallo- β -lactamases among Enterobacteriaceae from routine samples in an Italian tertiary-care hospital and long-term care facilities during 2008. Clin Microbiol Infect 17: 181-189.
37. Suwansrinon K, Wilde H, Sitprija V, Hanvesakul R (2005) Enteric fever-like illness caused by infection with *Citrobacter amalonaticus*. J Med Assoc Thai 88: 837-840.
38. Cruz AT, Cazacu AC, Allen CH (2007) *Pantoea agglomerans*, a Plant Pathogen Causing Human Disease. J Clinical Microbiology 45: 1989-1992.
39. Mazloomi E, Jazani NH, Sohrabpour M, Ilkhanizadeh B, Shahabi S (2011) Synergistic effects of glutamine and ciprofloxacin in reduction of *Pseudomonas aeruginosa*-induced septic shock severity. Int Immunopharmacol.
40. Ben Haj Khalifa A, Moissenet D, Vu Thien H, Khedher M (2011) Virulence factors in *Pseudomonas aeruginosa*: mechanisms and modes of regulation. Ann Biol Clin 69: 393-403.
41. Aigner BA, Ollert M, Seifert F, Ring J, Plötz SG (2011) *Pseudomonas oryzae* cutaneous ulceration from *Octopus vulgaris* bite: a case report and review of the literature. Arch Dermatol 147: 963-966.
42. Swanson D, Vetter R (2005) Bites of Brown Recluse Spiders and Suspected Necrotic Arachnidism. N Engl J Med 352: 700-707.
43. Maynor M, Abt J, Osborne P (1992) Brown Recluse Spider Bites: Beneficial Effects of Hyperbaric Oxygen. J Hyperbaric Med 7: 89-102.