

# Association of Lupus with Spinal Muscular Atrophy and Suspected Bronchial Cancer

Anna Bazso<sup>1\*</sup>, Maria Judit Molnar<sup>2</sup>, Gyula Poor<sup>1</sup> and Emese Kiss<sup>1</sup>

<sup>1</sup>National Institute of Rheumatology and Physiotherapy, Budapest, Hungary

<sup>2</sup>Molecular Neurology Clinic and Research Center, Semmelweis University, Budapest, Hungary

## Introduction

SLE is an autoimmune disease with multiple organ involvement. It may affect musculo-skeletal and nervous systems resulting in muscle weakness and atrophy. Classification criteria for the diagnosis of SLE were defined by the American College of Rheumatology. Spinal muscular atrophy (SMA) is characterised by degeneration of motor neurons of the spinal cord, which also may result in muscle weakness and hypotony. Earlier, the diagnosis was based on electromyography (EMG) and muscle biopsy findings. Electromyography characteristic of the disorder shows features of denervation with spontaneous activity of positive sharp waves, fibrillation, and occasional fasciculations. Motor unit action potential shows high amplitudes and long durations coupled with decreased recruitment. Histopathology of skeletal muscle usually shows atrophic fibres with islands of group hypertrophy, and severe loss of motor neuron in the spinal cord [1,2]. It is caused by homozygous disruption of the survival motor neuron 1 (SMN1) gene in form of deletion, conversion, or mutation. SMN1 is expressed in all tissues, but almost exclusively affects lower motor neurons. SMA divided into four clinical types: severe type I, intermediate type II, mild type III, and adult-onset type IV has been added to include very mild disease. Patients with type IV disease typically have onset of weakness in the second or third decades of life [3-5].

## Case Report

Hereby, we report the case of a female patient who had weakness of the flexor muscles of the pelvis at the age of 18. She was treated with high-dose corticosteroid at that time, as polymyositis was supposed. Due to the steroid therapy she became better and stronger, but was not symptom-free. Later the weakness progressed appearing in her lower and upper extremities, too. The EMG detected neurogenic failure; the electroneurography (ENG) showed axonal type of neuropathy. Based on these, SMA was suspected, but genetic examination could not be performed at that time.

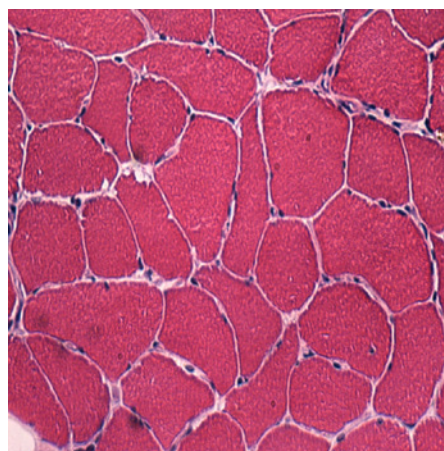
When she was 30 years of old symmetric polyarthritis involving the small joints of the hands, butterfly rash, leucopenia, lymphopenia, ANA (3+ positive with homogenous pattern in 1:400 dilution of serum) and anti-dsDNA (349 WHO U/mL) positivity referred to SLE. Later *grand mal* epilepsy, pleurisy, pericarditis, and autoimmune haemolytic anaemia developed. Associating sicca syndrome was also diagnosed based on glandular signs and aENA, a-SS-A, a-SS-B positivity. Antiphospholipid syndrome was suspected as she had livedo reticularis, IIIrd degree aortic valve insufficiency, pre-termed ischemic heart disease, acute myocardial infarction (with positive troponin I test result and inferior hypokinesis on echocardiography), and multiple vascular lesions by cranial MRI. However, she was more times negative for anti-phospholipid antibodies (PL Ab) including anti-cardiolipin, anti-beta2-glycoprotein I and lupus anticoagulant. She was treated with steroid and azathioprine, and required cyclophosphamide cycles to control haemolysis. Aspirin prophylaxis was given after MI. Besides all of these, oesophageal dysmotility and Raynaud's phenomenon was also present. Capillary microscopy picture was characteristic for SLE and not for systemic sclerosis.

At the second year with SLE thoracic CT was performed because

of effort dyspnoea and coughing. CT showed reticulo-nodular bunch and lymphadenopathy in the axillary regions. Mammography was negative. Findings were attributed to the consequence of smoking. Novel autoantibodies had not been detected.

At the age of 37 her muscle weakness worsened leading to muscle atrophy of the lower extremities with mild paraparesis. Activity of CPK was normal, but LDH was slightly elevated. To differentiate between myositis, steroid myopathy, SMA progression further investigations were performed. Muscle biopsy revealed a combination of discrete perivascular inflammation and neurogenic damage of muscle fibers (Figure 1 and Figure 2). The genetic testing detected the deletion of the SMN1 gene, confirming previous SMA diagnosis. Due to progressive muscle weakness, unusual in type IV SMA, and also weight-loss and anaemia appropriate examinations were performed to exclude paraneoplastic origin of symptoms.

Chest X-ray and pulmonary CT detected a round-shaped, spicular infiltration in the low lobe of the right lung. Broncho-fiberoscopy was negative. Biopsy with a video assisted thoracoscopy (VATS) has not confirmed bronchial cancer. Histopathology findings were characteristic for postinfectious residues.



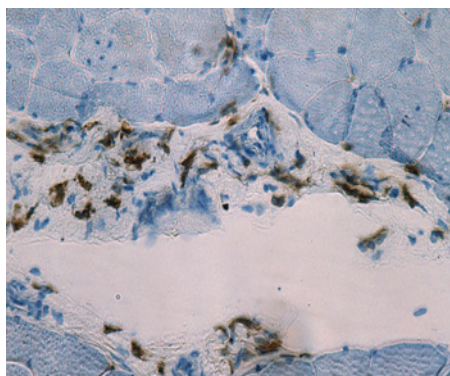
**Figure 1:** The variability of the fiber-diameter is more than as usual, there are some rounded, angulated fibers as well. This picture is not typical for spinal muscular atrophy.

**\*Corresponding author:** Dr. Anna Bazsó MD, Clinical Rheumatology, Adult- and Pediatric Rheumatology Department, National Institute of Rheumatology and Physiotherapy, H-1023 Budapest, Frankel L. str. 38-40, Hungary, E-mail: bazsoanna@yahoo.com

**Received** June 14, 2011; **Accepted** October 08, 2011; **Published** October 14, 2011

**Citation:** Bazso A, Molnar MJ, Poor G, Kiss E (2011) Association of Lupus with Spinal Muscular Atrophy and Suspected Bronchial Cancer. Rheumatology 1:101. doi:10.4172/2161-1149.1000101

**Copyright:** © 2011 Bazso A, et al. This is an open-access article distributed under the terms of the Creative Commons Attribution License, which permits unrestricted use, distribution, and reproduction in any medium, provided the original author and source are credited.



**Figure 2:** The CD4 Th-cells are the prominent subcells in the perimysial connective tissue.

## Discussion

SLE is an autoimmune disorder developing in genetically predisposed individuals. Lupus may affect any organs of the body. The great majority of lupus patients present different musculoskeletal symptoms, e.g. polyarthritis or mild focal myositis. Neuro-psychiatric manifestations are less frequent. Particular forms had been characterized and classified by ACR ad hoc Committee [6]. Polyneuropathy as a consequence of vasculitis of *vasa nervorum*, and transverse myelitis may lead to neurogenic muscle weakness and atrophy [7]. Inactivity caused by arthritis-induced pain, glucocorticoid or antimalarial therapy as well as other frequently used drugs, such as e.g. statins and also deficient vitamin D supplementation, that is common in lupus, may interfere with musculoskeletal symptoms [8]. Furthermore, other conditions have to be considered in the differential diagnosis both of muscle atrophy and paraparesis. Spinal muscular atrophy is a monogenic disorder caused by modifications of the survival motor neuron 1 (SMN1) gene. It is a rare autosomal recessive neurodegenerative disease manifesting in muscle weakness and atrophy. From the four types of the disease type IV is the less severe and starts at the second and third decades of life. In the present case both EMG and ENG findings were characteristic for SMA. The diagnosis was confirmed by genetic examination indicating homozygous mutation of the SMN1 gene. The rapid progression of symptoms, observed in our patient, and the histopathology findings of the muscle biopsy were characteristic neither for lupus, nor for SMA. These unusual events have drawn up the possibility of the presence of neoplastic process. The possibility of paraneoplasia was also indicated by the symptoms and the patient's history describing her as a heavy smoker (20 cigarettes./day for 10 years). It is known that malignant disorders may mimic rheumatologic diseases by different mechanisms [9]. Special types of malignancies, especially malignant non-Hodgkin lymphomas, Hodgkin's disease, uterine cervix cancer and bronchial cancer are more frequent in SLE than in the general population according to standardized incidence ratio (SIR) [10-12]. The presence of bronchial cancer was suspected in our patient according to a CT examination. As per literature data out of the 9547 lupus patients 62 suffered from bronchial cancer [13]. Smoking is a risk factor in provoking the development of lung cancer in lupus patients as well as in the general population. Furthermore, smoking is also a risk factor for lupus itself. The ratio of smokers was the highest within those lupus patients in whom lung cancer developed as compared to the entire SLE patient group or to the general population. Besides chronic inflammation and permanent DNA damage caused by smoking or shared genetic background predisposing to SLE and bronchial cancer may serve with an explanation [13]. However, histopathology findings didn't prove malignant disease in the bronchial tree and the lung.

## Conclusions

Lupus may cause a wide variety of organ manifestation, as in case of our patient. Although neuro-muscular symptoms were the most prominent in her case, those could be attributed mainly to an associated disease; spinal muscular atrophy. The co-existence of the two diseases is very rare and makes the differential diagnosis difficult because both may result in similar phenotype. Paraneoplastic syndrome may further complicate the differential diagnosis, as resulted in similar symptoms as well. However, the anti-Hu antibody, as antineuronal antibody could be as an indicating marker. In cases of anti-Hu related paraneoplastic syndromes usually associated with small cell lung cancer. About 20% have prominent lower motor neuron signs but almost always accompanying involvement of other areas of the nervous system [14,15]. Unusual clinical progression and non-specific histopathology as well as refractivity to adequate therapy suggested us to look for the third disease and focus on the regular exclusions of the malignancy. The most difficult is to find adequate intervention to treat such patients. Fortunately, malignancy was excluded by histology.

## References

- Buchthal F, Olsen PZ (1970) Electromyography and muscle biopsy in infantile spinal muscular atrophy. *Brain* 93: 15-30.
- Emery AE, Hausmanowa-Petrusewicz I, Davie AM, Holloway S, Skinner R, et al. (1976) International collaborative study of the spinal muscular atrophies. Part 1. Analysis of clinical and laboratory data. *J Neurol Sci* 29: 83-94.
- Russman BS (2007) Spinal muscular atrophy: clinical classification and disease heterogeneity. *J Child Neurol* 22: 946-951.
- Wang CH, Finkel RS, Bertini ES, Schroth M, Simonds A (2007) Consensus statement for standard of care in spinal muscular atrophy. *J Child Neurol* 22: 1027-1049.
- Iannaccone ST, Smith SA, Simard LR (2004) Spinal muscular atrophy. *Curr Neurol Neurosci Rep* 4: 74-80.
- Hochberg MC (1997) Updating the American College of Rheumatology revised criteria for the classification of systemic lupus erythematosus. *Arthritis Rheum* 40: 1725.
- The American College of Rheumatology nomenclature and case definitions for neuropsychiatric lupus syndromes (1999). *Arthritis Rheum* 42: 599-608.
- Arnsperger C, Amal H, Shoenfeld Y (2007) Vitamin D and autoimmunity: new aetiological and therapeutic considerations. *Ann Rheum Dis* 66: 1137-1142.
- Szekanecz E, Szucs G, Szekanecz Z, Tarr T, Antal-Szalmas P, et al. (2008) Tumor-associated antigens in systemic sclerosis and systemic lupus erythematosus: associations with organ manifestations, immunolaboratory markers and disease activity indices. *J Autoimmun* 31: 372-376.
- Bernatsky S, Joseph L, Boivin JF, Gordon C, Urowitz M, et al. (2008) The relationship between cancer and medication exposures in systemic lupus erythematosus: a case-cohort study. *Ann Rheum Dis* 67: 74-79.
- Bernatsky S, Ramsey-Goldman R, Lachance S, Pineau CA, Clarke AE (2006) Lymphoma in a patient with systemic lupus erythematosus. *Nat Clin Pract Rheumatol* 2: 570-574.
- Bernatsky S, Boivin JF, Joseph L, Manzi S, Ginzler E, et al. (2006) Mortality in systemic lupus erythematosus. *Arthritis Rheum* 54: 2550-2557.
- Tarr T, Gyorffy B, Szekanecz E, Bhattoa HP, Zeher M, et al. (2007) Occurrence of malignancies in Hungarian patients with systemic lupus erythematosus: results from a single center. *Ann N Y Acad Sci* 1108: 76-82.
- Tofaris KG, Farmer SF (2008) Focal Paraneoplastic Syndrome associated with small cell carcinoma of the lung. *J Neurol* 255: 123-124.
- Verma A, Berger JR, Snodgrass S, Petit C (1996) Motor neuron disease: a paraneoplastic process associated with anti-Hu antibody and small-cell lung carcinoma. *Ann Neurol* 40: 112-116.