

## Arthropathy of the Shoulder

Leonardo Roever<sup>\*</sup> and Rogério de Melo Costa Pinto

Universidade Federal de Uberlândia, Uberlândia, Minas Gerais, Brazil

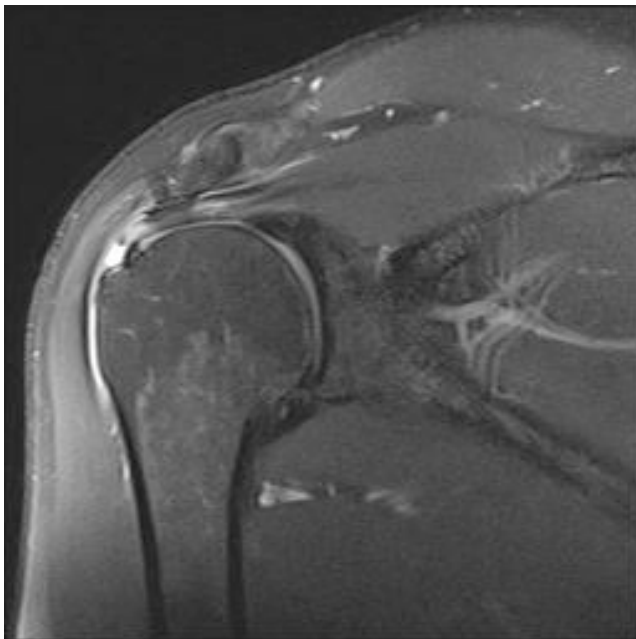
<sup>\*</sup>**Corresponding author:** Leonardo Roever, Universidade Federal de Uberlândia, Clinical Research, Rafael rinaldi 431, Uberlândia, Minas Gerais 38400-384, Brazil, E-mail: [leonardoroever@hotmail.com](mailto:leonardoroever@hotmail.com)

**Received date:** April 21, 2015; **Accepted date:** April 28, 2015; **Published date:** May 05, 2015

**Copyright:** © 2015 Roever L et al. This is an open-access article distributed under the terms of the Creative Commons Attribution License, which permits unrestricted use, distribution, and reproduction in any medium, provided the original author and source are credited.

### Description

Patient aged 45 years with chronic right shoulder pain after drug treatment (anti-inflammatory and corticosteroid), physiotherapy and acupuncture (Figure 1).



**Figure 1:** MRI of the shoulder.

### Diagnostic:

- Arthropathy of the acromioclavicular joint.
- Supraspinatus tendinopathy with partial tear of his anterior fiber.
- Bursopathy subacromial-subdeltoid.
- Osteochondral lesion of the lower tuberosity.