

## Aortic Dissection or MI? It could be both

Maria Dixon<sup>1\*</sup>

Biola University, La Mirada, USA

\*Corresponding author: Maria Dixon, MSN, Biola University, La Mirada, USA, Tel: 562 903-4850; E-mail: [maria.dixon@biola.edu](mailto:maria.dixon@biola.edu)

Received date: July 11, 2014, Accepted date: July 21, 2014, Published date: June 30, 2014

Copyright: © 2014 Dixon M. This is an open-access article distributed under the terms of the Creative Commons Attribution License, which permits unrestricted use, distribution, and reproduction in any medium, provided the original author and source are credited.

### Abstract

Acute aortic dissection is a potentially lethal vascular emergency that involves the rapid development of a false blood channel within the media of the aorta. If left untreated, approximately 50% of patients die in the first 48 hours, and the mortality rate increases by 1% to 3% per hour [1,2]. Despite recent advances in diagnostic methods, misdiagnosis occurs in 25%-50% of patients on initial evaluation with symptoms mimicking those of acute myocardial infarction and other cardiovascular disorders [3-5]. To further complicate an accurate diagnosis, ascending aortic dissections may involve the coronary and carotid arteries, resulting in myocardial infarction and stroke. With prompt diagnosis and treatment, one-year survival has been steadily improving and has been reported as high as 90% [6]. Therefore, timely diagnosis and rapid management of this disorder is imperative in the pre-hospital setting and in the Emergency Department. It is crucial that paramedics, emergency physicians and nurses maintain appropriate clinical suspicion for aortic dissection in patients presenting with sudden chest, back, or abdominal pain and asymmetrical pulses and blood pressures.

### Incidence

The true incidence of acute aortic dissection is difficult to define due to the fact that many patients die before reaching the hospital or prior to correct diagnosis [7]. The estimated incidence of aortic dissection is 3 to 4 per 100,000 people per year [8,9]. However, it is thought that for every correct diagnosis, there are two undiagnosed cases [2]. Many agree that the incidence is probably higher than expected and will continue to be one of the most lethal cardiovascular disorders [10-13]. Symptoms of aortic dissection may vary greatly resulting in a variety of presentations which may mimic other disorders. Aortic dissection is frequently confused with myocardial ischemia leading to a delayed or misdiagnosis, resulting in inappropriate treatment including the use of antithrombotic agents [5,7,14,15]. This tragedy was highly publicized in 2003 when the well-known actor, John Ritter, collapsed while filming a series. He was rushed to a local medical center where he died a few hours later. Assuming he was experiencing myocardial ischemia, he was treated with anticoagulants which were consistent with the protocol for acute coronary syndrome management. It was later determined that he had died of an acute aortic dissection.

Aortic dissection occurs two to three times more frequently in men between the ages of 60 and 70 than in women of the same age. Dissections occurring below the age of 40 are fairly equal among genders, with half the dissections in women occurring during pregnancy. Marfan's syndrome accounts for the majority of cases of aortic dissection in patients less than 40 years of age [7,14,16-18].

Despite recent progress in diagnostics and treatment of acute aortic dissection, the medical and nursing community needs further education, information, and experience in understanding aortic dissection and defining management pathways for prompt diagnosis and treatment. The establishment of the International Registry of Acute Aortic Dissection (IRAD) has contributed to a better understanding of the complexity of this disorder. The IRAD is a consortium of research centers that are evaluating the current

management and outcomes of acute aortic dissection. It was established in 1996 and currently has 24 large referral centers in 12 countries participating in the registry. The main purpose of IRAD is to assess the etiological factors, modes of presentation, clinical features, treatment, and hospital outcomes of patients with acute aortic dissection internationally. The factors being studied include dates and times of symptom onset, clinical presentation, diagnosis, initial and chronic medical therapy, diagnostic imaging, and surgical and medical management [19].

### Histology

The aorta contains three layers. The intima is the innermost layer that is in direct contact with the flow of blood and consists of endothelium and connective tissue. The middle layer, the thicker media, is composed of elastin, collagen, and smooth muscle cells. The outermost layer, the adventitia, is thin and composed of connective tissue which provides strength and stability as it anchors the vessel to surrounding structures. The blood supply to the aortic media is supplied via the vasa vasorum, a network of capillaries embedded in the adventitia [18].

### Pathophysiology

Diseases that weakened the aortic wall predispose the patient to aortic dissection. The distinctive underlying pathology of aortic dissection is medial degeneration, a decrease in aortic wall cohesiveness, and an increase in shear stress. Medial degeneration tends to be more extensive in older adults with chronic hypertension, in cystic medial necrosis associated connective tissue disorders such as Marfan's syndrome, and with atherosclerosis causing occlusion and injury of the vasa vasorum [11,20].

Aortic dissection is characterized by a longitudinal separation of the media in a course parallel to blood flow. It can result from an intimal tear and propagation of the dissection into the media or from intramural hemorrhage and hematoma formation. Most dissections

involve a transverse intimal tear that is frequently characterized by an intimal flap. Although the event that triggers medial dissection remains unclear, it is thought that the vasa vasorum ruptures, causing medial hemorrhage; or the intima tears as a result of flexion stresses and hemodynamic forces which allow blood to enter the media. The dissection can travel for varying distances throughout the aorta producing a false channel. The progressing dissection can result in disruption of flow to branch vessels, acute aortic valve regurgitation, and aortic rupture [11,17,20].

Etiology

A number of inherited and acquired conditions are thought to predispose the aorta to dissection, but medial degeneration is common to all dissections. When the diseased aortic wall is exposed to specific stresses, the aorta is at risk for dissection. In summary, all mechanisms weakening the media can lead to higher aortic wall stress which can result in dissection, aneurysm formation, and rupture. Acute aortic dissection requires a tear in the aortic lumen that is complicated by medial wall generation or cystic medial necrosis.

Increasing age and male gender are recognized risk factors for aortic dissection; however, systemic hypertension is the most common risk factor. According to a study by the International Registry of Acute Aortic Dissection of 464 patients who presented with dissection over a two-year period, hypertension was present in over 70% of patients [14].

The normal aorta, affected by aging, hypertension and degenerative changes, can result in the breakdown of the collagen, elastin, and smooth muscle. Chronic hypertension may exert significant stress on the media, resulting in eventual medial damage, intimal thickening, fibrosis, calcification, and degeneration. These changes result in poor oxygenation to the aortic wall causing vascular smooth muscle damage. The addition of smoking and hyperlipidemia may serve as additional stressors contributing to atherosclerotic changes to the aortic wall. The resulting weakness and increased wall stress act synergistically as common factors for aneurysm formation and aortic dissection [21].

Connective tissue disorders such as Marfan’s syndrome and Ehlers-Danlos syndrome are associated with medial degeneration making it

prone to dissection. Both of these disorders are characterized by increased elasticity of the aortic wall secondary to a deficiency of connective tissue and ineffective cross-linking of collagen in the aorta. Histology studies of Marfan’s have demonstrated an accumulation of mucoid material (cystic medial necrosis) in the aortic media that leads to structural faults and degeneration of the elastic tissue. Cardiovascular pathology is the leading cause of morbidity and mortality in Marfan’s syndrome, and 40% of patients with Ehlers-Danlos syndrome have aortic dissection by 40 years of age. Inflammatory diseases and autoimmune diseases can severely affect the vasa vasorum of the media resulting in decreased blood supply, medial necrosis and weakening of the aortic wall. Pulsatile flow and hypertension can contribute to the propagation of the dissection [22,23]. Drug abuse such as cocaine and methamphetamines has been recognized as a cause of acute dissection related to the profound elevation of blood pressure resulting in an intimal tear [29,30]. The risk of aortic dissection increases with pregnancy. Fifty percent of aortic dissections occur during pregnancy in women under the age of 40. During pregnancy the body produces hormones that act on smooth muscle and connective tissue for normal uterine expansion. The combination of these hormonal changes, accompanied by increased blood volume and hypertension may result in decreased cohesiveness of the media resulting in aortic dissection [7].

Although trauma rarely causes the classic dissection, it is occasionally cited as a risk factor for aortic dissection [13,26]. However, it should not be confused with the typical pathology associated with aortic dissection. Blunt chest trauma involving the sudden deceleration as seen in motor vehicle crashes or falls can result in a localized tear or rupture of the aorta. Most intimal tears occur at the aortic isthmus, distal to the left subclavian artery where the mobile aortic arch joins a relatively fixed thoracic aorta. Aortic disruption can be limited to the intima or include the entire wall resulting in rupture [18,21]. Iatrogenic dissections may occur from aortic trauma inflicted during diagnostic and therapeutic procedures such as angiography and cardiopulmonary bypass. A thorough assessment should be performed in patients with unexplained hemodynamic instability or malperfusion syndromes following invasive vascular procedures or surgery [6] (Table 1).

1	Aortic dissection is difficult to diagnose in the pre-hospital setting and may easily be misdiagnosed as acute coronary syndrome resulting in inappropriate treatment with thrombolytics.
2	There is a critical need for educating emergency care givers and primary care physicians in the diagnosis of acute aortic dissection
3	A high level of clinical suspicion combined with history, physical examination, and imaging studies is crucial for prompt and accurate diagnosis.
4	Checking blood pressure in both arms, listening for carotid bruits and aortic regurgitation, and obtaining a chest x-ray is crucial prior to administering thrombolytics.
5	The entire clinical picture must be taken into account and special attention given to presenting symptoms.

Table 1: Summary of Key Points.

Classification

Aortic dissections may be classified in three ways: according to the anatomical involvement, according to the time of onset, and according to the underlying pathology. There are two traditional classification systems for acute aortic dissection which are based on the site of the intimal tear and the extent of the aorta involved in the dissection.

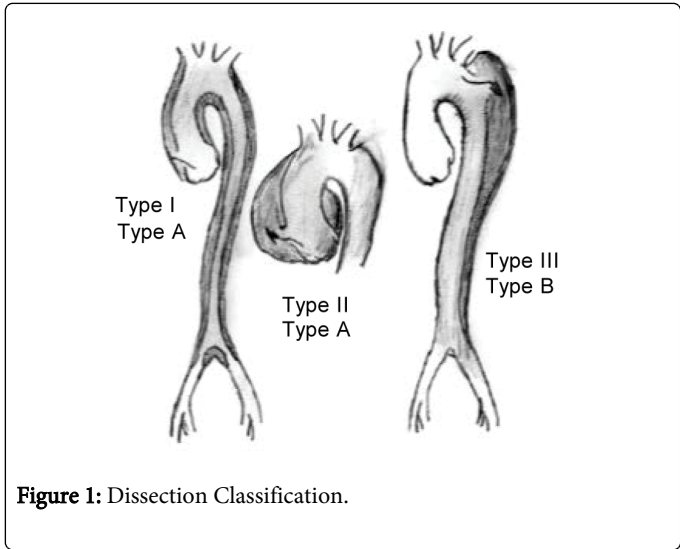
DeBakey’s classification subdivides the dissection into type I which is proximal to the arch vessels and may extend the length of the aorta, type II involves only the ascending aorta, and type III typically begins distal to the left subclavian artery and often extends distally to the bifurcation or beyond [24]. The Stanford classification describes ascending dissections as type A and descending dissections as type B [25]. Recent advances in imaging technology have led to the

identification of pathological changes during a dissection resulting in a new classification system by The European Society of Cardiologists of Class 1-5. Class 1 describes the classic aortic dissection with an intimal flap between the true and false lumen. Class 2 involves medial disruption with formation of intramural hematoma and hemorrhage. Class 3 consists of a discrete or subtle dissection without hematoma.

Class 4 contains plaque rupture leading to aortic ulceration, penetrating aortic atherosclerotic ulcer with surrounding hematoma and Class 5 includes iatrogenic and traumatic dissections [21]. All classes of dissection can be seen in their acute or chronic stages. By definition, acute aortic dissection occurs less than 14 days from onset of symptoms [26,27] (Table 2) (Figure 1).

Stanford	Type A: ascending aorta affected
	Type B: ascending aorta not affected
DeBakey	Type I: entire aorta affected
	Type II: ascending aorta affected
	Type III: descending aorta affected
Svensson	Class 1: classic dissection with an intimal flap between true and false lumen
	Class 2: intramural hematoma or hemorrhage
	Class 3: subtle dissection with an eccentric bulge at intimal tear site
	Class 4: penetrating atherosclerotic ulcer as a result of plaque rupture
	Class 5: iatrogenic or traumatic dissection

**Table 2:** Classification of acute aortic dissection.



**Figure 1:** Dissection Classification.

Clinical Presentation

The primary challenge in managing acute aortic dissection is to correctly diagnose and treat the event as early as possible. Therefore, the need for a high index of clinical suspicion is crucial in potentially improving early survival rate. The diagnosis should be suspected in any patient who has abrupt, sharp chest or back pain, pulse deficits, blood pressure differentials and mediastinal widening on chest radiography [28].

Chest pain is the most common presenting symptom and is described as sudden, severe, tearing or ripping pain. The description of the pain may indicate where the dissection originates. Patients with ascending dissections tend to have anterior chest pain due to the interruption of blood flow to the coronary arteries, resulting in

myocardial ischemia. The pain of aortic dissection typically is distinguished from the pain of acute myocardial infarction by its abrupt onset. Pain in the neck or jaw may indicate involvement of the aortic arch and extension into the great vessels. Patients with descending dissections complain of posterior interscapular pain or pain radiating to the back, abdomen or legs. Pain should be assessed in relation to quality, radiation, severity, and timing [12,14,18].

In addition, patients can present with features attributing to aortic branch occlusion such as syncope, stroke symptoms, neurological deficits, altered mental status, dyspnea, and dysphagia. Other symptoms may include paraplegia from spinal cord ischemia, abdominal pain related to mesenteric vascular occlusion, upper or lower limb ischemia symptoms, and acute renal failure or flank pain related to impaired flow to the renal arteries [12,14,17,21].

Hypertension is the most common factor in aortic dissection, however, patients presenting with type A dissection can present with hypotension or shock as a result of cardiac tamponade, acute aortic regurgitation, myocardial infarction, or aortic rupture. Examination of the major arterial branches, such as the carotid, subclavian, and femoral arteries may reveal systolic murmurs, bruits, unequal or absent pulses, duplication of pulses, and significant differences in limb blood pressure [11,14,17,21].

Diagnostic Tests

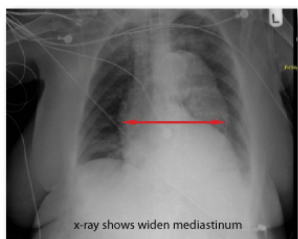
EKG

The electrocardiogram can help distinguish aortic dissection from acute coronary syndrome where treatment may include anticoagulation, but would be contraindicated in aortic dissection. Unfortunately, 20% of patients with type A dissection have EKG changes as a result of dissection involving the coronary arteries making it impossible to differentiate between the two conditions

without further tests. A normal EKG may also be seen but should not rule out the possibility of aortic dissection [14,21,26].

### Chest x-ray

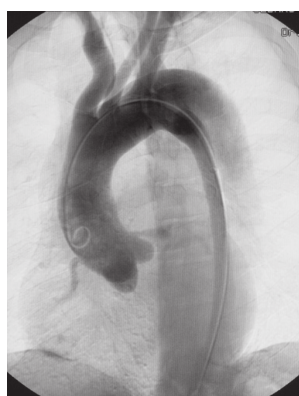The chest x-ray is not sufficient to rule out or diagnose aortic dissection, however, it has been reported abnormal in 60%-90% of patients including superior mediastinal widening, blunted distal aortic knob, increased aortic diameter, right deviation of the trachea, and hemothorax, and significant pleural effusions. Although these abnormalities are suggestive of aortic dissection, the condition may exist in the presence of a normal chest film [11,14,28,31] (Figure 2).



**Figure 2:** CXR wide mediastinum.

### Angiography

The aortogram reveals accurate diagnosis of aortic dissection in over 95% of patients and assists the surgeon in planning the repair. The benefits include visualization of the true and false lumens, intimal flap, aortic regurgitation, coronary arteries, arch vessels, and the extent of the dissection. The disadvantages include the need to transport the patient to radiology, the use of contrast dye in patients who may have renal insufficiency, and the invasiveness of the procedure. Although still considered by some as the diagnostic standard test, it is being replaced by newer imaging modalities [21] (Figure 3).



**Figure 3:** AD aortogram.

### Computed Tomography (CT)

CT scanning is readily available in larger emergency departments and is the modality commonly used for diagnosing aortic dissection. Visualization of an intimal flap separating the true lumen from the

false channel confirms the diagnosis; additional information regarding the extent of the dissection including aortic branch compromise can also be provided [20,21]. Advances in technology such as the multi-detector CT allow scanners to quickly obtain multiple images simultaneously with a higher rate of detection, better resolution and less artifact [21]. This advanced scanning ability is offering a positive alternative to angiography as the diagnostic test of choice in many institutions [1].

### Magnetic Resonance Imaging (MRI)

The MRI provides excellent images of the aorta; however, its use is limited in emergency situations due to the lack of immediate availability, patient instability and metal implants. It is useful in the evaluation of stable patients and in chronic aortic dissection [20,21].

### Echocardiography

Ultrasonography is becoming an accepted diagnostic tool in the Emergency Department. Both transthoracic echocardiography (TTE) and transesophageal echocardiography (TEE) can be performed quickly for the hemodynamically unstable patient. The TEE can identify the entry site of dissection, the presence of false lumen thrombus, the presence of an undulating intimal flap that differentiates the false lumen from the true lumen, the involvement of arch and coronary vessels, pericardial effusion, and severity of aortic valve regurgitation [6,21]. In addition, the Focused Assessment with Sonography for Trauma (FAST) is a quick, noninvasive ultrasound examination of the hemodynamically unstable patient in the emergency department directed solely at identifying the presence of free intraperitoneal or pericardial fluid. In the patient with traumatic injury or suspicion of aortic dissection, free fluid is usually due to hemorrhage and contributes to the assessment of the circulation and quick diagnosis of dissection and cardiac tamponade.

### Biochemical Markers

Aortic dissection causes extensive damage to the smooth muscle cells of the media, resulting in the release of myosin heavy chain proteins into the circulation. The highest levels are seen within the first three hours of symptoms (specificity 98%) and are higher in patients with proximal aortic dissections due to the dense concentration of smooth muscle in the thoracic aorta. Although more research is needed, the use of biomarkers for diagnosis of aortic dissection is rapid, noninvasive, and shows future promise in judging the need and urgency for further diagnostic procedures [32].

### Additional Laboratory Tests

Laboratory testing is not very helpful when assessing for aortic dissection. Unlike cardiac troponins in Acute Coronary Syndrome, there are no conclusive tests proven to be specific for dissection. Although the smooth muscle myosin heavy chains, D-dimer, and C-reactive protein have shown diagnostic promise. In cases of severe hemorrhage, the hemoglobin and hematocrit may be decreased and renal compromise may be reflected by an elevated blood urea nitrogen (BUN) and creatinine [17,21].



## Treatment

### Prehospital Care

Establishing the diagnosis of acute aortic dissection in the pre-hospital setting is challenging if not impossible. The typical patient with aortic dissection is a male in his 60's with a history of hypertension who presents with an abrupt onset of chest pain. Most pre-hospital providers are well trained in the management of patients with acute coronary syndrome (ACS) including the use of anti-coagulation; however, the consequences of misdiagnosis of aortic dissection with ACS may be disastrous. In the event that the diagnosis may be suspected, proper radio communication insures the appropriate direction of care and selection of a receiving facility to mobilize adequate resources [14,31]. Primary attention should be to optimize oxygenation, maintain hemodynamic stability, obtain a focused history and assessment and transport to the appropriate facility. Based on data from the International Registry of Acute Aortic Dissection, the median time from the emergency department presentation to definitive diagnosis is 4.3 hours, with an additional four hours between diagnosis and surgical intervention [14]. A contributor to this delay is often due to patients presenting to smaller community hospitals inadequately prepared to diagnose and manage these patients resulting in an emergent transfer to a specialized facility [33]. Further education of the pre-hospital provider regarding the potential presenting symptoms of aortic dissection is greatly needed.

### Emergency Department

Dr. DeBaakey once said, "No physician can diagnose a condition he never thinks about" [15]. He understood the importance of maintaining a high clinical suspicion in patients presenting with symptoms that might direct the astute practitioner toward the diagnosis of aortic dissection. Probable predictors of acute aortic dissection include abrupt onset of chest or back pain, pulse or blood pressure differentials, and mediastinal widening on chest x-ray. As previously stated, the pain is often described as sharp and changing location according to the extension of the dissection. Proximal dissections produce more retrosternal pain, whereas distal dissections are characterized by interscapular and back pain. In contrast, the pain associated with myocardial ischemia is usually gradual, dull, heavy, and gains in intensity over time. Differential diagnosis of aortic dissection should always be considered in patients with abrupt chest pain, unexplained syncope, stroke, and acute onset of congestive heart failure, acute ischemia of extremities or viscera, and hypertension [5].

Initial therapy should include obtaining sufficient intravenous access, administering oxygen, and monitoring the rhythm, vital signs, and urine output. In cases of severe hemodynamic deterioration, fluid resuscitation, continuous blood pressure monitoring, sedation, intubation and ventilation is indicated. Prompt reduction of systolic blood pressure and management of pain is necessary to limit extension of the dissection and decrease the risk of rupture. Parenteral beta-blockers are the most commonly used drugs to maintain target systolic blood pressure between 100-120 mm Hg. In patients with severe hypertension, vasodilators such as nitroprusside may be used in combination with beta-blockers. Pain relief is commonly controlled with morphine which also decreases the sympathetic responses and reduces aortic pressure. Once diagnosis is suspected or confirmed, the patient should be transferred to the operating room or intensive care unit for further monitoring and treatment [1,12,21].

## Surgical and Interventional Therapy

Urgent surgical intervention in type A (type I, II) dissections is required to prevent aortic rupture and related complications associated with the dissection process such as cardiac tamponade, aortic regurgitation, and ischemia to the myocardium, brain, intestine, kidneys, and limbs. Resection of the intimal tear and implantation of a composite graft in the ascending aorta and anastomosis of involved aortic branches is performed. The numerous surgical procedures, grafts, glue, and aortic prosthesis available has greatly enhanced the surgical repair of thoracic aorta dissections. The use of hypothermic circulatory arrest and retrograde cerebral perfusion may help to decreased morbidity and mortality rates [12,20,21].

Uncomplicated distal dissections may be managed medically to control the blood pressure (dP/dT) with long-term antihypertensive medications such as beta-blockers. Indications for operative treatment of type B (type III) dissections are limited to the prevention or relief of life-threatening complications such as impending aortic rupture or compromising perfusion to a vital organ. The onset of ischemia of limbs, kidneys, or gut may be treated with interventional therapy and endovascular stenting and balloon fenestration to repair the intimal tear and restore circulation to the true lumen. Interventional therapy and graft stenting provides new options to handle complicated challenges of managing decreased perfusion to vital organs [12,21,34]. The use of percutaneous fenestration and stent placement in the treatment of aortic dissection continues to evolve. Endovascular technology has advanced to allow a variety of alternatives to traditional surgical and medical treatments for complicated surgical cases as well as uncomplicated chronic dissection [27].

### Post-Procedure Nursing Care and Monitoring

Most facilities have specific, standardized protocols for postoperative care. In general, the immediate postoperative nursing interventions in the intensive care unit include continuous monitoring of hemodynamics, vital signs, neurological status, pain level, chest tube drainage, urine output, skin, and lab values. Systolic blood pressure should be maintained below 120 mm Hg or as ordered to decrease the risk of bleeding yet ensure adequate renal, cerebral, and cardiac perfusion. This is often done with intravenous fluids, morphine to control pain and a combination of beta-blocking agents and vasodilators. Peripheral pulses and capillary refill should be evaluated hourly to monitor distal perfusion. Proper pulmonary toilet and ventilator management should be done in collaboration with respiratory therapy to decrease or prevent pulmonary complications. Thorough nursing assessments assist in detecting potential complications such as myocardial infarction, stroke, renal and visceral ischemia, cardiac tamponade, aortic rupture, and re-dissection. Intra-abdominal bleeding should be suspected with increasing abdominal girth, decreased urine output, and hypotension. Signs and symptoms of ischemic bowel may include diarrhea, melena, abdominal tenderness, absent or decreased bowel sounds, and fever.

The emotional stress and anxiety experienced in the intensive care unit can be overwhelming for the patient and family. Approaching the patient calmly and confidently while providing appropriate explanations prior to interventions will help reduce anxiety. Providing regular multi-disciplinary patient care meetings with the family serve to enhance communication, clarify expectations, and incorporate the family into the plan of care. Appropriate resources such as the social

worker, chaplain, and case manager should be utilized to address specific concerns and needs as necessary.

## Prognosis

Despite improved diagnostics and therapeutic techniques, the overall in-hospital mortality rate for proximal dissections remains 27% and approximately 10% for patients with distal dissections. The predicting factors for in-hospital mortality include proximal dissection, age 65 or greater, and extension of the dissection associated with pain, shock, pulse and neurologic deficits. Approximately one-third of surviving patients will experience re-dissection, aortic rupture, or will require surgery for aortic aneurysm formation within five years. The long-term five-year survival rate of patients with surgical repair of proximal dissections ranges from 65% to 80%, however, the ten-year survival rate decreases to 40% to 50%. The most common cause of death in long-term survivors is rupture of the aorta due to aneurysm formation. No patient should be considered cured, therefore, the long-term management goal is blood pressure control and close follow-up of the patient with consistent monitoring of the aorta using CT or MRI scans [14,21,35].

## Case Study 1

Mr. R was a 65 year-old male with a history of hypertension who was preparing for work one morning, when he experienced acute onset of sub sternal chest pain radiating to his back, accompanied by upper extremity numbness. Thankfully, he was able to call 911. Initially, the first responders expected Mr. R. was having a heart attack, however, the experienced staff in the emergency department quickly realized his presenting symptoms indicated something more ominous. He was lethargic but responsive and also complained of abdominal pain accompanied with nausea and vomiting. Physical exam revealed a diminished pulse in the left carotid and left extremity, significant differences in arm blood pressures, and a 2/6 ejection systolic murmur at the aortic and left sternal border.

The EKG revealed minor ST elevation and Q-waves in lead III and a VF. The echocardiogram demonstrated mild aortic insufficiency with a slightly dilated aortic root. The CXR showed a wide mediastinum. The CT scan confirmed an intimal flap in the arch indicative of a type A aortic dissection extending from the aortic root to the abdominal aorta proximal to the renal arteries. A false lumen was compressing the true channel that provided perfusion to the left carotid and subclavian artery. A coronary angiogram was attempted prior to surgery but was aborted due to repeated cannulation of the false lumen.

Prior to surgery, the patient's blood pressure and heart rate were managed with Labetalol to keep heart rate below 60 and systolic blood pressure less than 110 mm Hg. With the coordination of the experienced cardiac surgery team, the use of intra-operative transesophageal echocardiography, induced hypothermia and the heart-lung machine, Mr. R. underwent extensive aortic graft surgery to repair the aortic tear and aortic valve, and to restore circulation to the carotid and coronary arteries. The operation went well, and Mr. R. returned to the intensive care unit for continuous monitoring and

management of his hemodynamic and respiratory status. The days and weeks that followed were plagued with numerous problems and challenges typical of aortic dissections including maintaining normal blood pressure with beta blockers and anti-hypertensives, control of bleeding, respiratory complications requiring a tracheostomy, gastrointestinal bleeding, deep venous thrombosis, atrial fibrillation, and altered level of consciousness.

Open visiting hours allowed his wife to provide support to Mr. R. which proved to be vital to his on-going recovery. As Mr. R was slowly weaned off the ventilator, he initially did not respond to commands and it was unclear if he was neurologically intact. His wife brought in his favorite music, performed range of motion exercises, and faithfully encouraged his progress. His neurological recovery was slow, but he eventually began to follow commands and show signs of normal functioning.

After 25 days in the intensive care unit and five days in a regular hospital room, Mr. R went home where his golden retriever had been waiting for him at the foot of the stairs each evening. Eventually, Mr. R regained his strength and was able to return to work.

## Case Study 2

Patient S was a 70 year old female with a history of hypertension and smoking who developed sudden anterior chest pain that was described as ripping in nature and radiating to the back; followed by left lower leg tingling. The patient thought she was having a heart attack and called 911. When the paramedics completed a quick history and assessment, they assumed the patient was experiencing acute coronary syndrome. Aspirin was administered per protocol and the patient was transported to a local receiving emergency department and anti-coagulation was initiated. The patient's blood pressure was 90/50, and she continued to complain of tingling and coldness in her left leg which was accompanied by decreased pulses. She remained in the emergency department for approximately 12 hours for further diagnostic studies. Her chest x-ray, echocardiogram, and EKG were considered within normal limits. The patient continued to complain of numbness in the left leg, and the physical exam revealed an absent pulse with significant mottling.

On day 2 the patient was transferred to another hospital and admitted to the intensive care unit. A repeat echo demonstrated a Type A dissection originating in the aortic arch and extending to left iliac artery. At this time the patient began to experience dyspnea, hypotension and altered level of consciousness. She was intubated, placed on a ventilator and started on sepsis protocol. This hospital was not equipped for operative intervention.

On day 3 the patient became less responsive, requiring maximum doses of vasopressors to maintain her blood pressure. On day 4 the patient was transferred to a hospital capable of appropriate operative intervention, however, the patient was considered too unstable for surgery and became unresponsive. After considerable discussion with the medical team, the family agreed to a DNR status. On day 5 the patient became bradycardic, hypotensive and expired (Table 3).

CASE 1	CASE 2
Symptoms of substernal chest pain radiating to back with upper extremity numbness	Symptoms of sudden, tearing, anterior chest pain radiating to back and complains of tingling in left lower extremity

911 called and transported to local ED with diagnosis of Acute Coronary Syndrome. Symptoms progressed to acute abdominal pain accompanied by nausea and vomiting	911 called, ASA given by EMS and transported to local ED where diagnosis was presumed to be Acute Coronary Syndrome. Anticoagulation was initiated and further diagnostic testing done
Physical findings included diminished L. carotid and radial pulses, BP differentials and 2/6 systolic murmur. Aortic dissection suspected.	Physical findings included numbness, mottling, and absent pulse in lower extremity. Patient remained in the ED
EKG revealed ST elevations and Q waves in Leads III and aVF. CXR demonstrated wide mediastinum. CT demonstrated intimal flap, type A dissection from aortic root to proximal renal arteries, and false lumen compressing L. carotid and subclavian artery.	CXR, ECHO, and EKG were considered within normal limits. Day 2: patient transferred to another facility and admitted to ICU. Repeat ECHO revealed type A dissection from aortic arch to L. iliac artery.
Treatment: management of SBP <110 and immediate surgical intervention	Treatment: Patient's condition worsens, placed on ventilator and sepsis protocol. Day 3: requires maximum vasopressors to maintain BP. Patient unresponsive Day 4: patient transferred to another hospital capable of surgical intervention but considered too unstable for operation and
Outcome: ICU for 25 days, Step down unit for 5 days. DC home with no deficits.	Outcome: Family conference resulted in decision for DNR status and patient expired on day 5.

**Table 3:** Case Outcome Comparison.

## Conclusion

Aortic dissection remains the most devastating cardiovascular disorder facing the most experienced clinician today. The mortality risk is 1%-3% per hour in untreated patients [1,11,14]. Although the classic presentation is sudden, severe pain in the chest or back, hypertension or hypotension, and asymmetrical pulses and blood pressures, many patients do not have all these characteristics. A high level of clinical suspicion is critical in the presence of abrupt, severe chest or back pain, pulse deficits, asymmetrical blood pressures, new aortic regurgitation, hypotension, shock, and genetic disorders associated with aortic dissection. Aortic dissection is often confused with acute coronary syndrome, leading to delayed diagnosis, inappropriate treatment with fibrinolytics and contributing to an increased mortality. In addition, patients frequently do not recognize the symptoms of aortic dissection, and many of these patients die before presenting to the emergency department. Optimal management includes controlling the blood pressure and pain, avoiding anticoagulation, and prompt surgical intervention as indicated. A multidisciplinary and systematic approach to the diagnosis and treatment of aortic dissection is crucial to provide life-saving interventions to improve the outcome of patients presenting with this vascular emergency.

## References

- Wiesenfarth J (2002) Aortic dissection. *eMedicine Journal* 3: 1.
- Anagnostopoulos CE (1975) *Acute Aortic Dissections*. Baltimore (MD): University Park.
- Spittell PC, Spittell JA Jr, Joyce JW, Tajik AJ, Edwards WD, et al. (1993) Clinical features and differential diagnosis of aortic dissection: experience with 236 cases (1980 through 1990). *Mayo Clin Proc* 68: 642-651.
- Klompas M (2002) Does this patient have an acute thoracic aortic dissection? *JAMA* 287: 2262-2272.
- Hansen MS, Nogareda GJ, Hutchison SJ (2007) Frequency of and inappropriate treatment of misdiagnosis of acute aortic dissection. *Am J Cardiol* 99: 852-856.
- Nienaber CA, Eagle KA (2003) Aortic dissection: new frontiers in diagnosis and management: Part II: therapeutic management and follow-up. *Circulation* 108: 772-778.
- Khan IA, Nair CK (2002) Clinical, diagnostic, and management perspectives of aortic dissection. *Chest* 122: 311-328.
- Mészáros I, Mórocz J, Szlávi J, Schmidt J, Tornóci L, et al. (2000) Epidemiology and clinicopathology of aortic dissection. *Chest* 117: 1271-1278.
- Clouse WD, Hallett JW Jr, Schaff HV, Spittell PC, Rowland CM, et al. (2004) Acute aortic dissection: population-based incidence compared with degenerative aortic aneurysm rupture. *Mayo Clin Proc* 79: 176-180.
- Kouchoukos NT, Dougenis D (1997) Surgery of the thoracic aorta. *N Engl J Med* 336: 1876-1888.
- Siegal EM (2006) Acute aortic dissection. *J Hosp Med* 1: 94-105.
- Crawford ES (1990) The diagnosis and management of aortic dissection. *JAMA* 264: 2537-2541.
- Coughlin R (2008) Recognizing aortic dissection: a race against time. *American Nurse Today* 31-35.
- Hagan PG, Nienaber CA, Isselbacher EM, Bruckman D, Karavite DJ, et al. (2000) The International Registry of Acute Aortic Dissection (IRAD): new insights into an old disease. *JAMA* 283: 897-903.
- Harris KM, Strauss CE, Duval S, Unger BT, Kroshus TJ, et al. (2010) Multidisciplinary standardized care for acute aortic dissection: design and initial outcomes of a regional care model. *Circ Cardiovasc Qual Outcomes* 3: 424-430.
- Nienaber CA, Fattori R, Mehta RH, Richartz BM, Evangelista A, et al. (2004) Gender-related differences in acute aortic dissection. *Circulation* 109: 3014-3021.
- Dixon MB (1987) Acute aortic dissection. *J Cardiovasc Nurs* 1: 24-35.
- Dixon M (1988) Patients with vascular emergencies. In: Fahey VA, editor. *Vascular Nursing*. 3rd ed. Philadelphia; WB Saunders.
- International Registry of Aortic Dissection. [www.iradonline.org](http://www.iradonline.org).
- Golledge J, Eagle KA (2008) Acute aortic dissection. *Lancet* 372: 55-66.
- Erbel R, Alfonso F, Boileau C, Dirsch O, Eber B, et al. (2001) Diagnosis and management of aortic dissection. *Eur Heart J* 22: 1642-1681.
- Roberts WC (1981) Aortic dissection: anatomy, consequences, and causes. *Am Heart J* 101: 195-214.
- Wheat MW Jr (1980) Acute dissecting aneurysms of the aorta: diagnosis and management--1979. *Am Heart J* 99: 373-387.
- DEBAKEY ME, HENLY WS, COOLEY DA, MORRIS GC Jr, CRAWFORD ES, et al. (1965) SURGICAL MANAGEMENT OF DISSECTING ANEURYSMS OF THE AORTA. *J Thorac Cardiovasc Surg* 49: 130-149.

- 
25. Daily PO, Trueblood HW, Stinson EB, Wuerflein RD, Shumway NE (1970) Management of acute aortic dissections. *Ann Thorac Surg* 10: 237-247.
  26. Assar AN, Zarins CK (2008) A killer at large: acute aortic dissection. *Br J Hosp Med (Lond)* 69: 626-631.
  27. Karthikesalingam A, Holt PJ, Hinchliffe RJ, Thompson MM, Loftus IM (2010) The diagnosis and management of aortic dissection. *Vasc Endovascular Surg* 44: 165-169.
  28. von Kodolitsch Y, Schwartz AG, Nienaber CA (2000) Clinical prediction of acute aortic dissection. *Arch Intern Med* 160: 2977-2982.
  29. Grannis FW, Bryant C, Caffaratti JD, Turner AF (1988) Acute aortic dissection associated with cocaine abuse. *Clin Cardiol* 11: 572-574.
  30. Rashid J, Eisenberg MJ, Topol EJ (1996) Cocaine-induced aortic dissection. *Am Heart J* 132: 1301-1304.
  31. Slater EE, DeSanctis RW (1976) The clinical recognition of dissecting aortic aneurysm. *Am J Med* 60: 625-633.
  32. Suzuki T, Katoh H, Watanabe M, Kurabayashi M, Hiramori K, et al. (1996) Novel biochemical diagnostic method for aortic dissection. Results of a prospective study using an immunoassay of smooth muscle myosin heavy chain. *Circulation* 93: 1244-1249.
  33. Trimarchi S, Nienaber CA, Rampoldi V, Myrmel T, Suzuki T, et al. (2005) Contemporary results of surgery in acute type A aortic dissection: The International Registry of Acute Aortic Dissection experience. *J Thorac Cardiovasc Surg* 129: 112-122.
  34. Svensson LG, Kouchoukos NT, Miller DC, Bavaria JE, Coselli JS, et al. (2008) Expert consensus document on the treatment of descending thoracic aortic disease using endovascular stent-grafts. *Ann Thorac Surg* 85: S1-41.
  35. Eagle KA, Bruckmann D, Isselbacher E (2000) Predictive of mortality in patients with type A acute aortic dissections-results from the International Registry of Acute Aortic Dissection. *J Am Coll Cardiol* 35: 323.