

Anti-eye Muscle IgG and IgM Antibodies are Associated with Eye Muscle Type 2 Deiodinase Activities in Hyperthyroid Graves' Ophthalmopathy

Ildikó Molnár* and Éva Somogyiné-Vári

Immunoendocrinology and Osteoporosis Centre, EndoMed, Bem tér 18/C., H-4026 Debrecen, Hungary

*Corresponding author: Ildikó Molnár, Immunoendocrinology and Osteoporosis Centre, EndoMed, Bem tér 18/C., H-4026 Debrecen, Hungary, E-mail: molil@endomed.hu

Received date: July 18, 2016; Accepted date: October 04, 2016; Published date: October 17, 2016

Copyright: © 2016 Molnár I, et al. This is an open-access article distributed under the terms of the Creative Commons Attribution License, which permits unrestricted use, distribution, and reproduction in any medium, provided the original author and source are credited.

Abstract

Objective: Antibodies to eye muscle tissue are demonstrated in hyperthyroid Graves' disease but their pathognomonic roles have not been clarified yet. We suggest that type 2 deiodinase (DIO2) enzyme can be a target between orbital and thyroid diseases in hyperthyroid Graves' ophthalmopathy. In this study, the relationship between anti-eye muscle membrane (EyeM) and cytosol (EyeC) IgG, IgA and IgM antibodies and eye muscle DIO2 activity was investigated in hyperthyroid Graves' disease.

Methods: Thirty-two patients with hyperthyroid Graves' disease (20 had ophthalmopathy), mean age 36 ± 13 years, 27 females and 5 males formed the patient group. Thyroid hormone levels were measured with chemiluminescence immunoassay, antithyroid antibody and anti-eye muscle antibody levels with enzyme-linked immunosorbent assay, but TSH receptor antibodies with radioimmunoassay. Eye muscle DIO2 activity was measured using $^{125}\text{I-T}_4$.

Results: EyeM and EyeC IgG antibodies were associated with increased eye muscle DIO2 activity compared to those who were negative for these antibodies (2.79 ± 2.53 vs 17.88 ± 20.06 pmol/mg/min, $P < 0.015$ for EyeM-IgG and 6.88 ± 9.62 vs 26.76 ± 23.86 pmol/mg/min, $P < 0.008$ for EyeC-IgG). The difference in EyeC-IgM antibodies was significant between patients with and without ophthalmopathy (10.1 ± 4.73 vs 3.46 ± 3.18 pmol/mg/min, $P < 0.023$). The presence of EyeM-IgM antibodies was associated with lower eye muscle DIO2 activities with significantly decreased eye muscle thicknesses (8.51 ± 15.38 vs 2.6 ± 0.1 pmol/mg/min and 4.71 ± 1.23 vs 3.9 ± 0.14 mm, $P < 0.04$).

Conclusion: Anti-eye muscle antibodies were associated with increased or decreased eye muscle DIO2 activities affecting eye muscle thicknesses in hyperthyroid Graves' ophthalmopathy. DIO2 enzyme can be a new target between orbital and thyroid diseases in hyperthyroid Graves' ophthalmopathy.

Keywords: Anti-eye muscle antibodies; Type 2 deiodinase; Hyperthyroid Graves' disease; Graves' ophthalmopathy

Introduction

Graves' ophthalmopathy is an organ-specific autoimmune disease with the metabolic feature of hyperthyroidism, diffuse goitre, and asymmetrical increased volume of orbital tissues due to local inflammatory and immune processes [1]. Several antibodies to orbital tissues were demonstrated highlighting their clinical importance but their pathognomonic roles have not been confirmed [2-4]. We demonstrated the binding features of IgG, IgA and IgM isotype anti-eye muscle membrane and cytosol antibodies to different molecular weights of eye muscle proteins [5]. A clinical relevance was found between proptosis and the presence of anti-eye muscle membrane IgA antibodies [6]. The increase of retrobulbar fat volume and eye muscle enlargements lead to proptosis, diplopia and rarely sight loss due to optic nerve compression [7]. Eye muscle enlargements are very frequent symptom of Graves' ophthalmopathy and affect differently extraocular muscles, such as medial, lateral, superior and inferior muscles [8].

Type 2 deiodinase enzyme (DIO2) is responsible for the maintenance of the intracellular T_3 pool and implicates in the development, growing and restitution of skeletal muscles [9]. Muscle fiber hypertrophy can also connect to increased DIO2 activity [10]. Three types of deiodinase enzymes are involved in thyroid hormone metabolism. DIO1 and DIO2 convert thyroxine to active triiodothyronine (T_3). DIO1 and DIO3 inactivate thyroxine converting that to reverse T_3 hormone [11]. Skeletal muscle tissue similar to eye muscle tissue contains DIO2 and DIO3 deiodinases. DIO2 locates in the endoplasmic reticulum with the active center in the cytosol, and DIO3 in the plasma membrane [12].

In this study, the relationship between eye muscle DIO2 activities of patients and antibodies to eye muscle membrane (EyeM) and cytosol (EyeC) fractions were investigated in hyperthyroid Graves' disease, particularly in ophthalmopathy.

Patients and Methods

Patients

Thirty two hyperthyroid patients with Graves' disease, 20 of whom had ophthalmopathy, mean age of 36 ± 13 years, 27 females and 5 males formed the patient group. The disease duration was 1 ± 2 months. Thyroid hormone serum levels were as follows: 0.047 ± 0.07 mIU/l for TSH, 44.38 ± 42.77 pmol/l for FT₄, 11.07 ± 6.74 pg/ml for FT₃. Antithyroid antibody serum levels were as follows: 58.9 ± 95.2 IU/l for TSH receptor antibodies, 1.95 ± 1.3 in ELISA index for thyroid peroxidase antibodies, 1.26 ± 0.44 in ELISA index for thyroglobulin antibodies. Hyperthyroidism was diagnosed by suppressed TSH levels with increased FT₄ and FT₃ levels. Ultrasonography was carried out by radiologist in all cases to measure extraocular muscle thicknesses. Toxic goitre was excluded using thyroid Technetium-99m scintigraphy and ultrasonography. NOSPECS evaluation was applied for the classification of ophthalmopathy [13]. All patients were active for ophthalmopathy, 18 patients had soft tissue involvement, 14 patients had proptosis and 10 patients had eye muscle enlargements.

None of the patients had corneal ulcer and/or optic nerve compression. Twenty-seven patients were untreated in the time of the study, and only 5 patients with Graves' ophthalmopathy received methimazole (15-30 mg/day) treatment with propranolol (20-40 mg/day).

Methods

Detection of anti-eye muscle membrane (EyeM) and cytosol (EyeC) antibodies: Antibodies against eye muscle membrane (EyeM) and cytosol (EyeC) fractions were measured by enzyme-linked immunosorbent assay (ELISA) detailed in our previous paper [14]. EyeM and EyeC fractions were prepared by centrifugations. The pellet of $100,000 \times g$ was served as membrane fraction and the supernatant as cytosol fraction. Eye muscle tissue were removed within 4-6 h after death from patients who did not suffer from tumor, endocrine and infectious diseases. The 96-well plates were pretreated with $50 \mu\text{g/ml}$ EyeM or EyeC fraction per wells and incubated overnight at 4°C . Patient sera of $100 \mu\text{l}$ (in dilution of 1:100) were added to each well for 2 h at room temperature. Goat antihuman IgG, IgA and IgM antibodies conjugated with horseradish peroxidase (in dilution of 1:2000) (SIGMA, USA) were applied for detector antibodies. The plates were measured in ELISA Reader at 492 nm and the results were given in ELISA index: the ratio of patient sample O.D. and the mean O.D. value of controls. The samples were used in duplicates. The mean value of ELISA indices ± 2 SD for controls (healthy subjects, $n=30$) was regarded as cut-off values for antibody positivity, which were as follows: 1.46 for EyeC-IgG, 2.16 for EyeC-IgA, 2 for EyeC-IgM, 1.52 for EyeM-IgG, 1.84 for EyeM-IgA and 1.9 for EyeM-IgM.

Measurement of eye muscle DIO2 activity: Human eye muscle tissue was obtained from strabismus surgery. Eye muscle cytosol of $100,000 \times g$ was prepared after centrifugations and used for source of eye muscle DIO2 enzyme. The measurement of eye muscle DIO2 activity was carried out similar to the detection of thyroid DIO2 activity described in detail in our previous paper [15]. Eye muscle DIO2 activity was investigated using radioiodine labeled $^{125}\text{I-T}_4$ after blocking DIO1 activity with propylthiouracil (PTU). The mixture containing $50 \mu\text{l}$ of dithiothreitol (20 mM, DDT, Reanal, Hungary), $2 \mu\text{M}$ PTU, $12.5 \mu\text{g}$ protein/ $50 \mu\text{l}$ of eye tissue fractions, $20 \mu\text{l}$ undiluted and non-complemented patient sera, $1 \text{ kB}/50 \mu\text{l}$ of $^{125}\text{I-T}_4$ substrate

(Isotope Institute, Budapest, Hungary) and 1 mM ethylenediaminetetraacetic acid (EDTA, Sigma, USA) in a final volume of $250 \mu\text{l}$ was prepared at ice-cold temperature. The reaction was induced by putting the mixture at 37°C for 90 min. The reaction was stopped by adding $100 \mu\text{l}$ 5% ice-cold bovin serum albumin (BSA, Sigma, USA) and the proteins were precipitated by adding $500 \mu\text{l}$ 20% trichloroacetic acid (Reanal, Hungary). The radioactivity of acid-soluble radioiodine samples and the blank (saline instead of serum, represented the total activity) were measured in gamma counter (Gamma NZ 322, Hungary). The samples were used in duplicates. DIO2 activity was expressed as pmol of T₄ converted per mg/min protein. Elevated T₃ serum levels in hyperthyroid patient sera may have a substrate inhibitory effect on DIO3 activities. The results were extrapolated at 1 pmol/l of T₄.

Detection of thyroid hormone and anti-thyroid autoantibody levels

Thyroid hormone levels (TSH, FT₄, FT₃) were measured with chemiluminescence immunoassay (LIA-MAT, Byk Sangtec, Germany) and antithyroid antibodies to thyroid peroxidase (TPO) and thyroglobulin (Htg) with ELISA method. TSH receptor antibodies were tested with radioimmunoassay (Brahms, Germany). The normal values of thyroid hormones were as follows: $7.72\text{-}23.18$ pmol/l for FT₄, $2.5\text{-}4.5$ pg/ml for FT₃ and $0.3\text{-}3$ mIU/l for TSH. Thyroid peroxidase and thyroglobulin were used in concentrations of $50 \mu\text{g/ml}$ after the preparation procedure described in detail in our previous paper [16]. ELISA tests for the detection of anti-TPO and anti-Htg antibodies were similar to the detection procedure of anti-eye muscle antibodies made by hospital laboratory and the results were also displayed in ELISA index: the ratio of patient sample O.D. and mean O.D. of controls (healthy subjects, $n=20$). The cut-off values were as follows: 1.86 for anti-Htg antibodies and 1.9 for anti-TPO antibodies. TSH receptor antibody values above 14 IU/l were regarded as positivity.

Statistical analysis

The data were displayed as mean \pm SD, but the results were exhibited as mean \pm standard error (SE) in Figures. Chi-squared statistical test with Yates's correction and Student's t-test were applied for comparison of two groups. Pearson's correlation was carried out to demonstrate any association between anti-eye muscle antibodies and eye muscle DIO2 activities.

Results

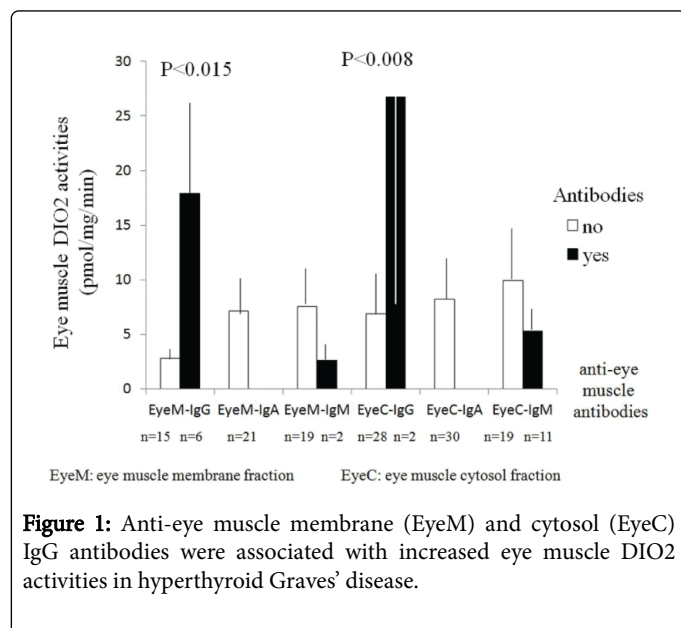
Occurrence of anti-eye muscle membrane (EyeM) and cytosol (EyeC) antibodies in hyperthyroid Graves' disease

The presence of EyeM and EyeC IgG, IgM, but not IgA antibodies could be demonstrated in hyperthyroid patients with Graves' disease (Table 1). In hyperthyroid Graves' ophthalmopathy, EyeM-IgG antibodies were found in 4 out of 15 cases, EyeM-IgM in 2 out of 14 cases, EyeC-IgG in 1 out of 19 cases and EyeC-IgM in 8 out of 19 cases. In hyperthyroid Graves' disease without ophthalmopathy, EyeM-IgG antibodies were found in 2 out of 6 cases, EyeC-IgG in 1 out of 11 cases and EyeC-IgM in 3 out of 11 cases. EyeM-IgM antibodies were detected only in Graves' ophthalmopathy and the difference was significant between the patients with and without ophthalmopathy ($P<0.005$).

Anti-eye muscle antibodies	Occurrence of anti-eye muscle antibodies				N	P
	Graves' disease without ophthalmopathy (n=12)		Graves' disease with ophthalmopathy (n=20)			
	No	Yes	No	Yes		
EyeM-IgG	4	2	11	4	6	0.005*
EyeM-IgA	0	0	0	0	0	
EyeM-IgM	6	0	13	2	2	
EyeC-IgG	10	1	18	1	2	
EyeC-IgA	0	0	0	0	0	
EyeC-IgM	8	3	11	8	11	

EyeM: Eye membrane fraction; EyeC: Eye muscle cortisol fraction; *Chi-squared statistical test with Yates's correction

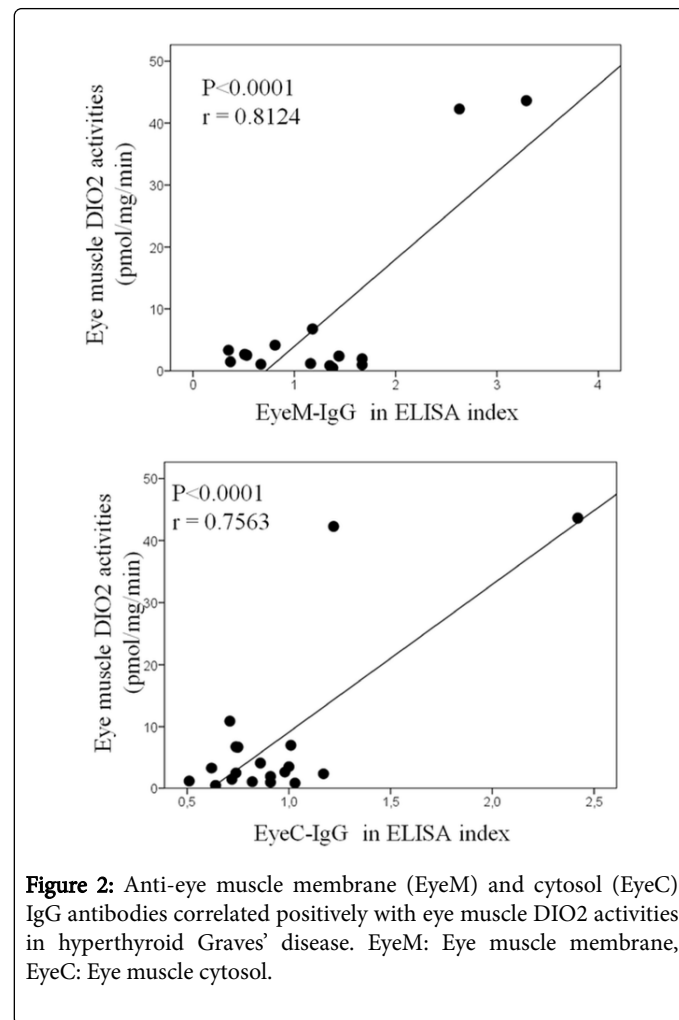
Table 1: Occurrence of anti-eye muscle membrane (EyeM) and cytosol (EyeC) IgG, IgA and IgM antibodies in hyperthyroid Graves' disease.



Anti-eye muscle antibodies were associated with increased or decreased eye muscle DIO2 activities in hyperthyroid Graves' disease

The presence of EyeM-IgG and EyeC-IgG antibodies was associated with significantly increased eye muscle DIO2 activities compared to those who were negative for these antibodies in hyperthyroid Graves' patients (2.79 ± 2.53 vs 17.88 ± 20.06 pmol/mg/min, $P<0.015$ for EyeM-IgG and 6.88 ± 9.62 vs 26.76 ± 23.86 pmol/mg/min, $P<0.008$ for EyeC-IgG) (Figure 1). EyeM-IgG and EyeC-IgG antibodies correlated positively with eye muscle DIO2 activities ($r=0.8124$, $P<0.0001$ for EyeM-IgG and $r=0.7563$, $P<0.0001$ for EyeC-IgG) (Figure 2). However, the presence of EyeM-IgM and EyeC-IgM antibodies was associated with decreased eye muscle DIO2 activities. The differences in eye muscle DIO2 activities between the presence and absence of EyeM-

IgM and EyeC-IgM antibodies were not significant (7.57 ± 12.98 vs 2.6 ± 0.99 pmol/mg/min for EyeM-IgM and 9.8 ± 13.83 vs 5.27 ± 4.6 pmol/mg/min for EyeC-IgM).



Relationship among eye muscle DIO2 activities, eye muscle DIO2 activities and eye muscle thicknesses in hyperthyroid Graves' ophthalmopathy

In hyperthyroid Graves' ophthalmopathy, the presence of EyeM-IgG antibodies was associated with significantly increased eye muscle DIO2 activities but only relevant eye muscle enlargements in comparison with those who were negative for these antibodies (2.45 ± 1.83 vs 22.21 ± 23.96 pmol/mg/min, $P<0.012$ and 4.32 ± 0.53 vs 5.6 ± 2.35 mm) (Figure 3). However, the presence of EyeM-IgM antibodies was associated with relevant decreased eye muscle DIO2 activities with significantly decreased eye muscle thicknesses (8.51 ± 15.38 vs 2.6 ± 0.1 pmol/mg/min and 4.71 ± 1.23 vs 3.9 ± 0.14 mm, $P<0.04$). The difference in EyeC-IgM antibodies was significant between patients with and without ophthalmopathy. The presence of EyeC-IgM antibodies was associated with significantly lower eye muscle DIO2 activities in hyperthyroid Graves' patients with ophthalmopathy compared to those who did not have ophthalmopathy (10.1 ± 4.73 vs 3.46 ± 3.18 pmol/mg/min, $P<0.023$) (Figure 4).

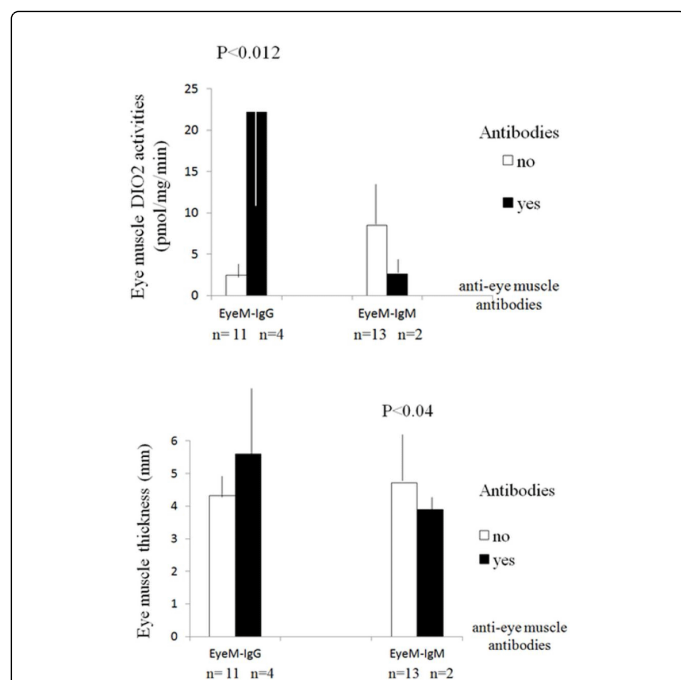


Figure 3: Anti-eye muscle membrane (EyeM) IgG antibodies were associated with increased, but IgM antibodies with decreased eye muscle DIO2 activities and eye muscle thicknesses in hyperthyroid Graves' ophthalmopathy. EyeM: Eye muscle membrane.

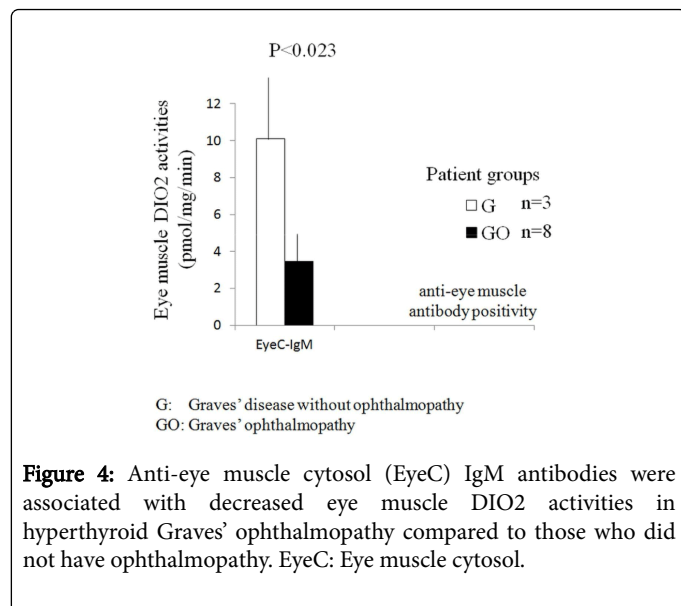


Figure 4: Anti-eye muscle cytosol (EyeC) IgM antibodies were associated with decreased eye muscle DIO2 activities in hyperthyroid Graves' ophthalmopathy compared to those who did not have ophthalmopathy. EyeC: Eye muscle cytosol.

Discussion

In hyperthyroid Graves' disease several autoantibodies are present with distinct binding reactivities. The pathognomonic role of anti-eye muscle antibodies in the development of Graves' ophthalmopathy has not been clarified yet, although their perimysial or endomysial bindings to myofibers or connective tissue, such as fibroblast or adipose tissue were demonstrated. The bindings of anti-eye muscle antibodies did not result in any damage cellularly or intracellularly in

eye muscle tissue. Therefore, the question comes always up whether these autoantibodies have any pathognomonic roles in the development of ophthalmopathy or they have only diagnostic roles. The fact, that sera of hyperthyroid Graves' ophthalmopathy have a stimulating effect on orbital fibroblasts driving them to express chemoattractants, IGF-1 and stimulate hyaluronan synthesis [17-19].

Our findings highlighted that the role of DIO2 enzyme can play also as a target between orbital and thyroid diseases in hyperthyroidism, which is mainly present in the onset of Graves' ophthalmopathy. Both, orbital and thyroid tissues contain DIO2 enzyme, which is essential for the maintenance of intracellular T_3 pool. Besides DIO2, extraocular eye muscles contain also DIO3, while thyroid tissue DIO1 enzymes.

Deiodinases, DIO2 and DIO3 are involved in myogenesis, therefore in skeletal muscle like eye muscle physiology influencing the myofiber type composition and their capacity for regeneration [20].

In this study, the association of anti-eye muscle membrane and cytosol isotype antibodies with eye muscle DIO2 activities was investigated in hyperthyroidism. Our findings confirmed that EyeM-IgG and EyeC-IgG antibodies were associated with increased eye muscle DIO2 activities, while EyeM-IgM antibodies decreased them. The decreased eye muscle DIO2 activities were connected to smaller and the increased DIO2 activities to greater eye muscle thicknesses highlighting the role of DIO2 in eye muscle enlargements in hyperthyroid Graves' ophthalmopathy. In thyroid autoimmunity, the occurrence of antibodies to DIO2 enzyme was demonstrated in a linkage with anti-pituitary antibodies [21].

In conclusion, anti-eye muscle isotype antibodies were associated with increased or decreased eye muscle DIO2 activities affecting eye muscle thicknesses in hyperthyroid Graves' ophthalmopathy. Our results confirmed that DIO2 enzyme can be a new target between orbital and thyroid diseases in hyperthyroid Graves' ophthalmopathy.

Acknowledgement

We thank Viktória Kaczur for the preparations of thyroid peroxidase and thyroglobulin proteins, as well as the Laboratorium and Radionuclear Department of Kenézy County Hospital for the measurements of thyroid hormone and antithyroid antibody levels, as well as ^{125}I - T_4 radioactive substances in gamma counter.

References

1. Bahn RS (2010) Graves' ophthalmopathy. N Engl J Med 362: 726-738.
2. Gunji K, De Bellis A, Kubota S, Swanson J, Wengrowicz S, et al. (1999) Serum antibodies against the flavoprotein subunit of succinate dehydrogenase are sensitive markers of eye muscle autoimmunity in patients with Graves' hyperthyroidism. J Clin Endocrinol Metab 84: 1255-1262.
3. Gopinath B, Musselman R, Beard N, El-Kaissi S, Tani J, et al. (2006) Antibodies targeting the calcium binding skeletal muscle protein calsequestrin are specific markers of ophthalmopathy and sensitive indicators of ocular myopathy in patients with Graves' disease. Clin Exp Immunol 145: 56-62.
4. Smith TJ, Tsai CC, Shih MJ, Tsui S, Chen B, et al. (2008) Unique attributes of orbital fibroblasts and global alterations in IGF-1 receptor signaling could explain thyroid-associated ophthalmopathy. Thyroid 2008; 18: 983-988.
5. Molnár I, Kaczur V, Boros A, Krajczár G, Balázs C (1995) IgA autoantibodies against human eye muscle antigen detected by western blotting and immunohistochemical methods in Graves' disease. J Endocrinol Invest 18: 408-414.

6. Molnár I, Balázs C (1994) IgA anti-eye muscle cytosol autoantibodies and the clinical stage in Graves' disease. *J Endocrinol Invest* 17: 671.
7. El-Kaissi S, Wall JR (2012) Determinants of extraocular muscle volume in patients with graves' disease. *J Thyroid Res* 2012: 368536.
8. Wiersinga WM, Regensburg NI, Mourits MP (2013) Differential involvement of orbital fat and extraocular muscles in graves' ophthalmopathy. *Eur Thyroid J* 2: 14-21.
9. Salvatore D, Simonides WS, Dentice M, Zavacki AM, Larsen PR (2014) Thyroid hormones and skeletal muscle--new insights and potential implications. *Nat Rev Endocrinol* 10: 206-214.
10. Wang YY, Morimoto S, Du CK, Lu QW, Zhan DY, et al. (2010) Up-regulation of type 2 iodothyronine deiodinase in dilated cardiomyopathy. *Cardiovasc Res* 87: 636-646.
11. Bianco AC, Kim BW (2006) Deiodinases: implications of the local control of thyroid hormone action. *J Clin Invest* 116: 2571-2579.
12. Baqui MM, Gereben B, Harney JW, Larsen PR, Bianco AC (2000) Distinct subcellular localization of transiently expressed types 1 and 2 iodothyronine deiodinases as determined by immunofluorescence confocal microscopy. *Endocrinol* 141: 4309-4312.
13. Barrio-Barrio J, Sabater AL, Bonet-Farriol E, Velázquez-Villoria Á, Galofré JC (2015) Graves' ophthalmopathy: VISA versus EUGOGO classification, assessment, and management. *J Ophthalmol* 249125: 1-16.
14. Molnár I, Balázs C (1991) Comparative study on IgG and IgA antibodies against human thyroid and eye-muscle antigens in Graves' ophthalmopathy. *Acta Med Hung* 48: 13-21.
15. Molnár I, Czirják L (2000) Euthyroid sick syndrome and inhibitory effect of sera on the activity of thyroid 5'-deiodinase in systemic sclerosis. *Clin Exp Rheumatol* 18: 719-724.
16. Kaczur V, Vereb G, Molnár I, Krajczár G, Balázs C (1995) Kinetic characterization of thyroid peroxidase enzyme and its inhibition by autoantibodies. *Acta Microbiol Immunol Hung* 42: 345-350.
17. Pritchard J, Horst N, Cruikshank W, Smith TJ (2002) Igs from patients with Graves' disease induce the expression of T cell chemoattractants in their fibroblasts. *J Immunol* 168: 942-950.
18. Smith TJ, Hoa N (2004) Immunoglobulins from patients with Graves' disease induce hyaluronan synthesis in their orbital fibroblasts through the self-antigen, insulin-like growth factor-I receptor. *J Clin Endocrinol Metab* 89: 5076-5080.
19. Krieger CC, Neumann S, Place RF, Marcus-Samuels B, Gershengorn MC (2014) Bidirectional TSH and IGF-1 receptor cross-talk mediates stimulation of hyaluronan secretion by Graves'disease immunoglobulins. *J Clin Endocrinol Metab* 100: 1071-1077.
20. Dentice M, Marsili A, Zavacki A, Larsen PR, Salvatore D (2013) The deiodinases and the control of intracellular thyroid hormone signaling during cellular differentiation. *Biochim Biophys Acta* 1830: 3937-3945.
21. Nakahara R, Tsunekawa K, Yabe S, Nara M, Seki K, et al. (2005) Association of antipituitary antibody and type 2 iodothyronine deiodinase antibody in patients with autoimmune thyroid disease. *Endocr J* 52: 691-699.