

Anterior Segment Manifestations of Microscopic Polyangiitis

Tayyeba K. Ali¹, Zaina N. Al-Mohtaseb¹, Hilal E. Ozturk¹, Guillermo Amescua¹, Carolina Betancurt¹ and Victor L. Perez^{1,2*}

¹Ocular Surface Center, Bascom Palmer Eye Institute, University of Miami Miller School of Medicine, Miami, USA

²Microbiology and Immunology Department, University of Miami Miller School of Medicine, Miami, USA

*Corresponding Author: Victor L. Perez, Director, Ocular Surface Center, Walter Ross, Distinguished Chair Ophthalmic Research, Bascom Palmer Eye Institute, University of Miami Miller School of Medicine, USA, Tel: 3054824853; Email: vperez4@med.miami.edu

Received date: September 29, 2014; Accepted date: October 7, 2014; Published date: October 14, 2014

Copyright: © 2014 Ali TK, et al. This is an open-access article distributed under the terms of the Creative Commons Attribution License, which permits unrestricted use, distribution, and reproduction in any medium, provided the original author and source are credited.

Abstract

In this retrospective, non-comparative case series, the medical records of three patients diagnosed with microscopic polyangiitis (MPA) at the Bascom Palmer Eye Institute, Ocular Surface/Uveitis service were analyzed: an 80-year-old female with episcleritis, peripheral ulcerative keratitis, and lung involvement (patient 1); an 83-year-old female with nodular non-necrotizing scleritis (patient 2); and a 19-year-old female with chronic conjunctivitis and nasal inflammation (patient 3).

Patient 1 had a diagnosis of MPA on presentation to our service; despite steroid-sparing therapy, she required steroids to treat the ocular flare-up of MPA. Patient 2 was given an MPA diagnosis with the help of rheumatology, based on clinical signs, symptoms and a positive p-ANCA; she was treated with corticosteroids and methotrexate. Patient 3 was diagnosed with MPA based on a second biopsy performed by ENT and a positive p-ANCA; treatment with corticosteroids and methotrexate was initiated.

MPA can have conjunctival, episcleral, scleral, and corneal manifestations. Even if lung or renal involvement is not noted clinically, a patient in whom there is a high suspicion for MPA should undergo a thorough systemic workup, including a biopsy. Furthermore, a multi-disciplinary approach should be taken when managing these patients in order to avoid vision and life-threatening complications.

Microscopic polyangiitis (MPA) is a necrotizing small-vessel vasculitis. Patients are typically male, middle-aged, and develop nonspecific, constitutional signs and symptoms of inflammation. Characteristic features include glomerulonephritis, pulmonary vasculitis, and circulating perinuclear antineutrophil cytoplasmic antibodies (p-ANCA) with myeloperoxidase specificity (MPO).

While MPA can affect various parts of the peripheral and central nervous systems, and ophthalmic involvement has been previously reported in scattered reports, ocular findings have not been well documented. MPA is a severe disease with the mortality as high as 27.5%; thus, treatment with immunosuppressant is generally necessary. In this article, we report our experience with three MPA patients who presented with atypical demographics and various ophthalmic findings.

Keywords: Microscopic Polyangiitis; p-ANCA positive vasculitis; Ocular surface involvement; Scleritis; Conjunctivitis

Report of Cases

Case 1

An 80-year old white female presented with a 2-year history of weakness, shortness of breath, hemoptysis, and weight loss; labs showed negative c-ANCA, positive p-ANCA, and elevated CRP. Chest CT reported a cavitary lesion and emphysematous changes; the lung biopsy showed vasculitis. The patient was diagnosed with MPA by rheumatology and started on intravenous methylprednisolone and mycophenolate mofetil 1000 mg/day. She also received two infusions of rituximab before our evaluation.

She was referred to ophthalmology for bilateral foreign body sensation and conjunctival hyperemia. Slit lamp examination demonstrated an area of sectoral conjunctival and episcleral injection

in both eyes that blanched. The infero-temporal limbal area of the right eye and inferior limbal area of the left suggested prior peripheral ulcerative keratitis (PUK) without active disease (Figure 1). Her p-ANCA antibodies were elevated. The patient was diagnosed with bilateral episcleritis with evidence of prior PUK. Prednisone 40 mg/day was added to her immunosuppressive regimen, with resolution of episcleritis after 10 days; the steroids were tapered slowly. The patient completed 2 cycles of rituximab and continued with mycophenolate mofetil 1000 mg/day for 6 months, then 500 mg/day for another 6 months. Her MPA remains quiescent.

Case 2

An 83-year old woman with cicatrizing conjunctivitis of her right eye noted a 3-month history of pain, redness, and yellowish discharge. She also complained of temporal headaches, shoulder pain, and muscle weakness in the hip and neck flexors. The patient had a diagnosis of dermatomyositis that was treated 15 years prior with oral prednisone. She was maintained on prednisone 5 mg for 10 years, but

had done well off steroids for the past 5 years. Slit-lamp examination of the right showed nodular non-necrotizing scleritis and a supero-temporal symblepharon. Conjunctival biopsy did not show active vasculitis, and the pathology report was consistent with episcleritis. Systemic workup showed an elevated ESR, CRP, and positive p-ANCA/MPO titer.

The patient was diagnosed with MPA by rheumatology and started on methotrexate 20 mg/week and prednisone 50 mg/day. After 1 month her eye was quiet, and prednisone was tapered slowly over 9 months. Her disease has been quiescent on methotrexate 15-20 mg/week.

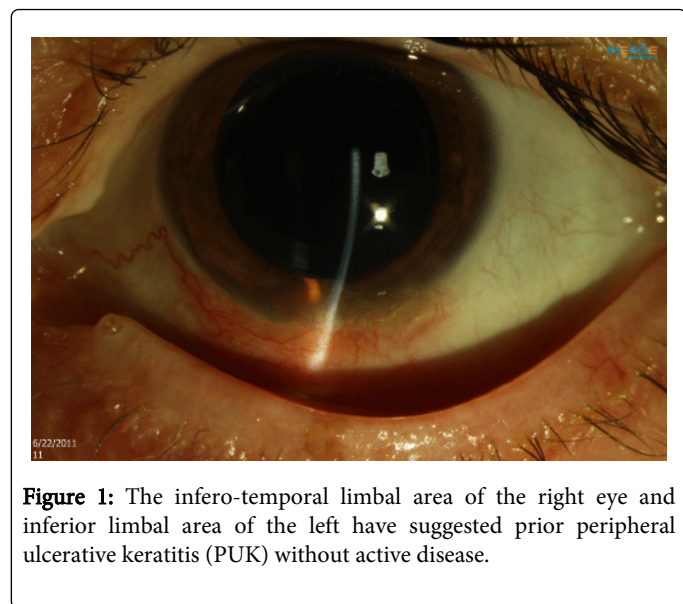


Figure 1: The infero-temporal limbal area of the right eye and inferior limbal area of the left have suggested prior peripheral ulcerative keratitis (PUK) without active disease.

Case 3

A 19-year-old female presented with chronic conjunctivitis. She had been treated with topical corticosteroids and topical cyclosporine 0.05%, which improved her symptoms; discontinuing the drops led to recurrence. She also complained of sinus congestion with occasional epistaxis. On exam, her nasal mucosa was significantly inflamed.

Case	Sex	Age	Systemic involvement	Ocular involvement	ANCA	Pathology	Initial therapy	Maintenance therapy	Last examination
1	F	80	Lung	PUK, Episcleritis	p-ANCA	Vasculitis (lung)	RXB, MFM	MFM	Quiet
2	F	83		Scleritis	p-ANCA	Negative (conjunctiva)	MTX, STD	MTX, LD-STD	Quiet
3	F	19	Nasal mucosa	Chronic conjunctivitis	p-ANCA	MPA (nasal mucosa)	MTX, STD	MTX, LD-STD	Quiet

P-ANCA: Perinuclear-Antineutrophil Cytoplasmic Antibody; RXB: Rituximab; MFM: Mycophenolate Mofetil; MTX: Metotrexate, STD: Steroid; LD-STD: Low dose steroid.

Table 1: Summary of Patient Information.

Discussion

Microscopic polyangiitis (MPA) is one of the ANCA-associated vasculitides that most commonly affects the kidneys and lungs. Although it shares clinical features with polyarteritis nodosa and Wegener’s granulomatosis, histological and serologic findings

Slit lamp examination demonstrated 2+ diffuse bulbar conjunctival injection that blanched and mild papillary reaction in the tarsal conjunctiva, without cicatricial changes (Figure 2).

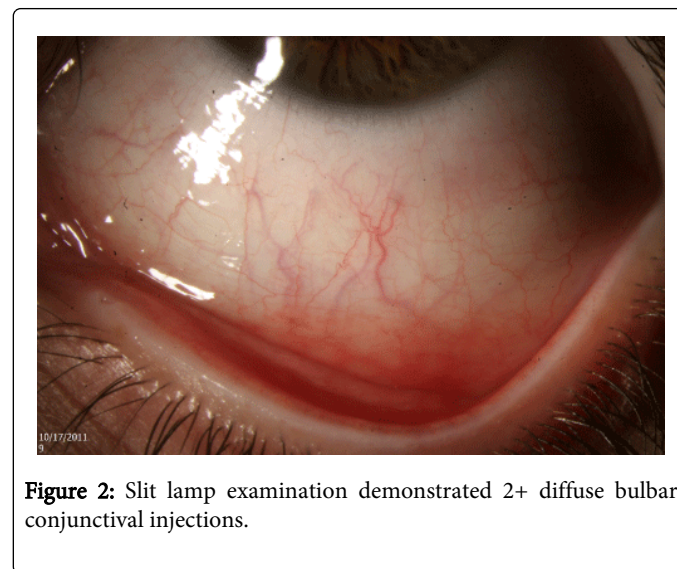


Figure 2: Slit lamp examination demonstrated 2+ diffuse bulbar conjunctival injections.

Serology for p-ANCA/MPO titer was positive. Conjunctival biopsy showed mild submucosal perivascular lymphocytic infiltrate, but no histologic evidence of vasculitis or connective tissue disease. Maxillofacial CT demonstrated maxillary sinus mucosal thickening. Given the high suspicion for MPA, the patient was referred to Otolaryngology for a nasal mucosal biopsy, which was positive for MPA. Systemic workup showed no renal or lung involvement. The patient was started on oral methotrexate 15 mg/week and prednisone 40 mg/day. After 1 month of treatment her sinusitis and episcleritis resolved and the p-ANCA level decreased. Oral prednisone was tapered slowly. Patient had a flare-up consisting of bilateral episcleritis and epistaxis after discontinuing prednisone. Methotrexate was increased to 25 mg/day and she was restarted on prednisone 10 mg/day. Over the course of 8 months, her p-ANCA levels normalized. She remains on methotrexate 2 mg/day and prednisone 5 mg/day, without further flares (Table 1).

differentiate the three. MPA is characterized by pauci-immune small-vessel vasculitis with the presence of perinuclear antineutrophil cytoplasmic antibodies (p-ANCA) [1]. Although biopsy is the gold standard, neither a negative biopsy nor negative serologies exclude the diagnosis of MPA, as only 50% of patients are positive for p-ANCA with MPO specificity [2].

Early diagnosis of vasculitic syndromes with proper management may prevent vision and life-threatening complications. In a retrospective review, Rothschild demonstrated that 8.9% (25/280) of patients with MPA developed ocular signs included episcleritis, scleritis, conjunctivitis, keratitis and uveitis [3]. We believe this is the first report of MPA presenting with PUK. Given the rarity of ocular manifestations in MPA, it is interesting that two of our three patients had ocular symptoms as the first presentation of disease. Although a study across practices would be required to determine the actual prevalence of eye symptoms amongst all MPA patients. Additionally, all three of our patients were female and one was in her teens, which is not the typical demographic.

Active vasculitis should be treated with immunosuppressive agents in two parts: initial and maintenance therapy. Combining a steroid and steroid-sparing agent is recommended; with cyclophosphamide used most frequently for induction of remission [4]. Due to its side effects, patients are often switched to azathioprine or methotrexate for maintenance therapy. In cases of resistance or intolerance, alternative therapies such as mycophenolate mofetil, cyclosporine, etanercept and rituximab may be used. According to the results of the NORAM study, methotrexate can be used for both initial and maintenance therapy of ANCA-associated vasculitis without life-threatening disease [5]. Two of our patients have remained quiescent on maintenance methotrexate, after an initial slow steroid taper.

Our experience has shown that MPA can first present with ocular signs before extensive systemic findings. Thus, this diagnosis should be considered in individuals with recurrent ocular inflammation, even with a negative biopsy. In cases, where clinical suspicion remains high, one should perform a detailed history, and ophthalmic and systemic

exam, which may include multiple biopsies. Furthermore, a multi-disciplinary approach is critical for definitive diagnosis and proper systemic management of these patients.

Acknowledgement

Dr. Victor Perez is a consultant for Allergan, Bausch and Lomb, Eleven, Parion, Rigel and Genentech. He also has speaking appointments with Bausch and Lomb. All other authors have no conflicts of interest, relevant financial interests, activities, relationships, and/or any other affiliations.

References

1. Villiger PM, Guillemin L (2010) Microscopic polyangiitis: Clinical presentation. *Autoimmun Rev* 9: 812-819.
2. Rothschild PR, Pagnoux C, Seror R, Brézin AP, Delair E, et al. (2013) Ophthalmologic manifestations of systemic necrotizing vasculitides at diagnosis: a retrospective study of 1286 patients and review of the literature. *Semin Arthritis Rheum* 42: 507-514.
3. Hara A, Ohta S, Takata M, Saito K, Torisaki M, et al. (2007) Microscopic polyangiitis with ocular manifestations as the initial presenting sign. *Am J Med Sci* 334: 308-310.
4. Jayne D, Rasmussen N, Andrassy K, Bacon P, Tervaert JW, et al. (2003) A randomized trial of maintenance therapy for vasculitis associated with antineutrophil cytoplasmic autoantibodies. *N Engl J Med* 349: 36-44.
5. De Groot K, Rasmussen N, Bacon PA, Tervaert JW, Feighery C, et al. (2005) Randomized trial of cyclophosphamide versus methotrexate for induction of remission in early systemic antineutrophil cytoplasmic antibody-associated vasculitis. *Arthritis Rheum* 52: 2461-2469.

This article was originally published in a special issue, entitled:
"Atherosclerosis and Rheumatic Diseases", Edited by Ihsane hmamouchi