

Anterior Capsule Configuration and Surgical Technique in Cases of Intraocular Lens–Capsular Tension Ring Complex Dislocation

Yuichiro Tanaka¹, Shigeo Yaguchi^{1*}, Tadahiko Kozawa¹, Mikihiro Ando¹, Tsukasa Hanemoto¹, Shinichi Kihara¹, Mitutaka Souda² and Eiichi Nishimura²

¹Kozawa Eye Hospital and Diabetes Center, 246-6 Yoshizawa-cho, Mito-shi, Ibaraki, Japan

²Department of Ophthalmology, School of Medicine, Showa University, Fujigaoka Hospital, 1-30 Fujigaoka, Aoba-ku, Yokohama, Japan

*Corresponding author: Shigeo Yaguchi, Kozawa Eye Hospital and Diabetes Center, 246-6 Yoshizawa-cho, Mito-shi, Ibaraki 310-0845, Japan, Tel: +81-29-246-2111; E-mail: yaguchi@kozawa-ganka.or.jp, yaguchis@hotmail.co.jp

Received date: February 08, 2016; Accepted date: April 26, 2016; Published date: April 29, 2016

Copyright: © 2016 Tanaka Y, et al. This is an open-access article distributed under the terms of the Creative Commons Attribution License, which permits unrestricted use, distribution, and reproduction in any medium, provided the original author and source are credited.

Abstract

Purpose: To report the formation of the continuous curvilinear capsulorhexis (CCC) window in cases of intraocular lens (IOL)–Capsular Tension Ring (CTR) complex dislocation, determine appropriate indications for using CTRs, and evaluate surgical techniques for repositioning of the dislocated IOL–CTR complex.

Methods: Four consecutive patients who underwent IOL repositioning surgery for IOL–CTR complex dislocation were followed-up postoperatively. CCC formation was analyzed using images captured during surgery and calculating software available for free.

Results: IOL–CTR complex dislocation had occurred from 2 to 120 months after initial cataract surgery. Repositioning surgery was completely performed with modified capsule expander (Yaguchi hook). The mean oblateness was 0.056 ± 0.053 (range, 0.002–0.14), indicating that CCC contours of dislocated IOL–CTR complex is approximately similar to circle formation.

Conclusions: CTR implantation is effective in maintaining the capsular formation postoperatively. The use of T-shaped capsule stabilization hook (Yaguchi hook) provided good centralization and stabilization of the IOL–CTR complex in eyes with severely weak zonular fibers providing a simple technique for repositioning of the dislocated complex via a corneal side port without IOL extraction.

Keywords: Intraocular lens dislocation; Capsular tension ring; Capsule expander; Continuous curvilinear capsulorhexis

Introduction

Cataract surgery comprises continuous curvilinear capsulorhexis (CCC), phacoemulsification and aspiration (PEA), and intraocular lens (IOL) implantation, and is considered one of the safest ophthalmological surgical interventions. However, there is serious risk of vitreous hernia and lens dislocation due to expansion during zonular dialysis in patients with weak zonules, making PEA challenging in such cases. Even in cases where lens removal is performed perfectly with stable IOL implantation into the lens capsule, adverse events such as capsule contraction syndrome (CCS) [1], anterior capsular phimosis [2], and in-the-bag intraocular lens dislocation [3-5] may postoperatively develop. Capsular tension rings (CTR) are widely used for the prevention of intraoperative and postoperative complications [6]. The insertion of a ring into the capsular bag fornix to support the zonular apparatus was first described by Hara in 1991 [7] who introduced the concept of CTRs also known as “equator rings” or “endocapsular rings”. Nagamoto and Bissen-Miyajima suggested the use of an open PMMA ring to provide adaptability in 1994 [8]. CTR devices may allow extension of capsular equator and stabilization of the circular contour of the capsular bag in patients with weak zonules by increasing in-the-bag stabilization and preventing intraoperative zonular dialysis [9]. Jacob et al. reported that using CTRs in preventing IOL dislocation in patients with weak

zonules is considered to be effective [10]. Conversely, Werner et al. recently reported dislocation of inserted CTR and IOL devices several months or years postoperatively in cases with partial zonular dialysis [11]. The efficacy and indications for use of CTRs remain contentious. Zonular weakness and contraction of the capsular bag, either individually or in combination, are considered to contribute to IOL–CTR complex dislocation. To the best of our knowledge, there have been no quantitative reports regarding formation of the anterior capsule. The purpose of this study is to report the formation of the CCC window in cases of IOL–CTR complex dislocation, determine appropriate indications for the use of CTRs, and evaluate surgical techniques for repositioning dislocated IOL–CTR complex.

Subjects and Methods

We enrolled 4 consecutive patients (4 eyes) who underwent IOL repositioning surgery for IOL–CTR complex dislocation at the University of Showa Fujigaoka Rehabilitation Hospital and Kozawa Eye Hospital and Diabetes Center from August 2009 to November 2014. The Institutional Review Board of both hospitals approved the study, and patients provided informed consent. The mean age at enrollment of included patients was 59.2 ± 3.1 years (range, 56–64 years).

CCC formation analysis was performed by replaying recorded videos of repositioning surgery and capturing static images at the time when dislocated IOL–CTR complex was shifted back into the pupil using IOL forceps (Figure 1). In one case with IOL–CTR complex

dislocation into the vitreous cavity, an image of the complex located on the retina following pars plana vitrectomy was captured and analyzed. CCC area was calculated using freely available area calculator software compatible with EXCEL(R Microsoft) (Figure 2). We assumed CCC window deformation was similar to circle formation. The long axial of an oval figure was defined as 'A' and the short axial as 'B'. Oblateness,

the ratio of flatness, was then calculated. The oblateness of the CCC window was calculated for short and long axial measurements (Figure 3). Clinical data of patients undergoing cataract surgery were obtained from medical records. The mean follow-up period from repositioning surgery for IOL–CTR complex dislocation was 31 months (range, 5–56 months). No cases of relapse were observed during this period.

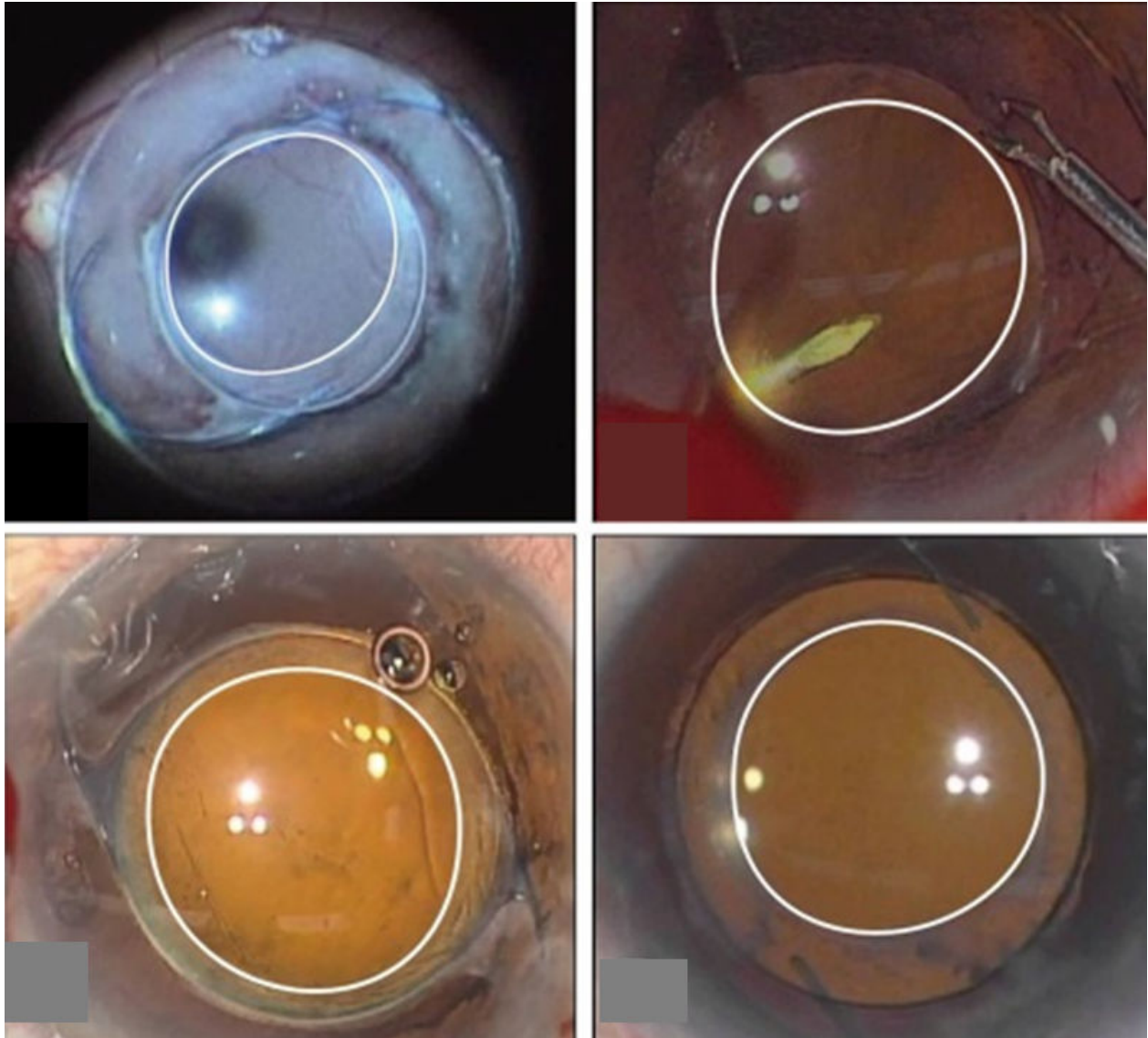


Figure 1: In-the-bag dislocation of intraocular lens (IOL) and capsular tension ring (CTR). **a)** The complex is dislocated within the vitreous cavity (case 1). **b)** The complex of case 2 is replaced to the central pupil during surgery. The continuous curvilinear capsulorhexis (CCC) window is demarcated (white line). **c)** Capture image of case 3. **d)** Capture image of case 4.

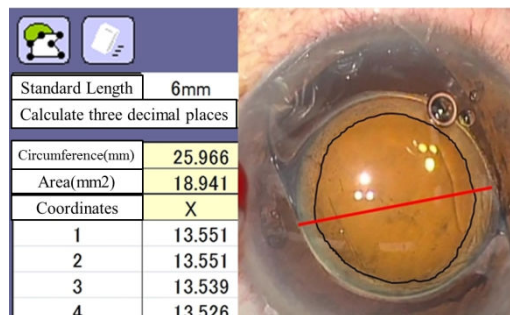


Figure 2: CCC size calculation method. The optical zone is measured at a diameter of 6mm with the use of a standard line set to the optics (red-line, case 3). The black line is subsequently drawn around the CCC edge for manual demarcation and the size of CCC is automatically calculated (18.941 mm² in this case).

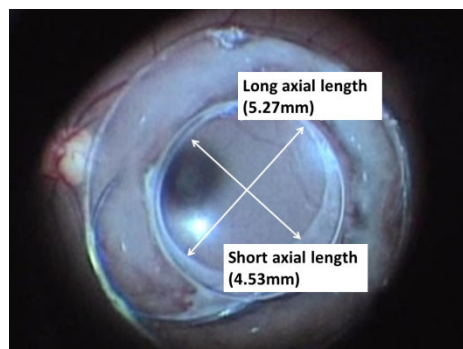


Figure 3: Image demonstrating the method of CCC window oblateness measurement. The CCC long and short axes are measured as 5.27 mm and 4.53 mm, respectively. Oblateness is calculated using the following formula; $(5.27-4.53)/5.27=0.14$.

Results

All four cases had CTR devices inserted at the time of the first cataract surgery to facilitate safe PEA and IOL insertion, particularly during partial breakdown of zonular support. Patient demographics and intraoperative variables are shown in Table 1. CTR insertion into the capsule was performed before PEA after complete CCC (cases 1, 2, and 3). In case 4, CTR insertion was performed before IOL insertion following PEA and irrigation and aspiration (IA) with a T-shaped capsule stabilization hook (capsule expander, Handaya Co., Ltd.) (Figure 4). The extent of zonular dialysis was no more than 180 degrees in any case. Ocular traumatic episodes were responsible for cases 2, and 4. Retinitis pigmentosa was the underlying etiology in case 3. The mean period between initial cataract surgery and IOL dislocation ranged from 2 to 120 months. Three-piece acrylic IOLs were implanted in cases 3, and 4, and a 1-piece acrylic IOL was implanted in case 2.

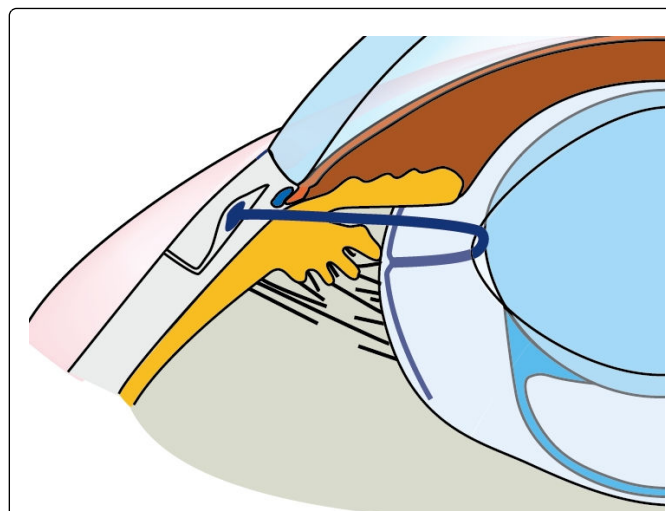


Figure 4: This capsule stabilization hook (Yaguchi hook) consists of a 15.0 mm curved needle attached to 5-0 polypropylene thread (50.0 mm long). It is bent at the anterior end and bifurcates at the posterior end to form a T shape. The T-shaped pad portion is 2.00 mm long for the expander and 3.75 mm long for the hook.

The mean CCC window size was 17.56 ± 1.51 mm² (range, 15.61–19.13 mm²). The mean short and long axial lengths were 4.55 ± 0.17 mm (range, 4.29–4.74 mm) and 4.86 ± 0.33 mm (range, 4.42–5.27 mm), respectively. The mean oblateness was 0.056 ± 0.053 (range, 0.002–0.14), indicating that the CCC contours of dislocated IOL–CTR complex is approximately similar to circle formation. Satisfactory CCC formation was not found to be associated with patient age, period from first surgery to dislocation, and IOL type. Dislocated IOL–CTR complex was resolved by IOL repositioning using the Modified capsule expander (Yaguchi hook) (Handaya Co., Ltd.) (Figure 4), which was developed as a capsular stabilization hook for scleral fixation of the capsule bag [12,13]. The Yaguchi hook is flexible, made of 5-0 polypropylene with 150 mm diameter, and attached to a curved needle. The contact portion is bent at 1.25 mm with the end bifurcated in a ‘T’ configuration to form a 3.75 mm footpad. Three Yaguchi hooks were implanted to fixate the capsule to the sclera in 2 cases (cases 1 and 2) and scleral-sutured IOL implantation with complex removal was performed in the remaining cases (cases 3 and 4). The postoperative observation duration ranged from 5 to 31 months. No dislocation recurrences were identified during this period.

	Case1	Case2	Case3	Case4
Age(years)	60	57	64	56
Ocular comorbidity	trauma	trauma	retinitis pigmentosa	trauma
Time of surgical IOL repositioning (months)	120	48	36	2
Type of IOL	3-piece acrylic	1-piece acrylic	3-piece acrylic	3-piece acrylic
CCC size (mm ²)	19.13	16.59	18.94	15.61

Long axial length (mm)	5.27	4.69	5.06	4.42
Short axial length (mm)	4.53	4.65	4.74	4.29
Oblateness	0.14	0.06	0.002	0.02
Repositioning method	M-CE	M-CE	IOL suture to sclera	IOL suture to sclera
M-CE=Modified capsule expander				

Table 1: Patient Characteristics.

Discussion

There has been a gradual increase in the incidences of IOL dislocation within the capsular bag since CCC was demonstrated as a more effective method for capsulorhexis than the previously used can-opener method [5]. IOL dislocation generally occurs because of progressive zonular weakening and dehiscence leading to loss of in-the-bag IOLs. Known risk factors for IOL dislocation include pseudoexfoliation syndrome, laser iridotomy, uveitis, retinitis pigmentosa, and ocular trauma. CTRs can facilitate safe phacoemulsification and IOL insertion, particularly during partial breakdown of zonular support, by stabilizing zonular stress. Because CTRs do not fix the capsule to the eyeball, they are not suitable in cases with severe zonular weakness, including phacodonesis and extensive zonular dialysis over 180 degrees. In cases where zonular dialysis is under 90 degrees, PEA may be performed without the use of CTRs. In cases where zonular dialysis is greater than 90 degrees and less than 180 degrees, PEA may be performed effectively with the use of CTRs. However, this approach hinders the use of IA because of severe concussion of lens capsule during insertion of the CTR. The extent of dialysis often increases in cases of hard lens nucleus, pseudoexfoliation syndrome, and thick epinucleus because rotation of lens nuclei may be impaired even when hydrodissection is perfectly performed. Jacob reported a success rate of 90.47% for PEA with in-the-bag IOL and CTR implantation in eyes with zonular dialysis of up to approximately 150 degrees; however, intraoperative dialysis extension occurred in 2 eyes (9.52%) [10]. Further studies to determine appropriate indications for the use of CTRs are required.

In the present study, we reviewed cases of IOL–CTR complex dislocation with zonular dialysis due to ocular trauma and retinitis pigmentosa. Three patients had CTRs inserted prior to PEA. In the remaining case (case 4), which had dehiscence of the zonules up to approximately 180 degrees, PEA had been performed with a capsule expander and CTR installation prior to IOL insertion [14]. We believe the approach of PEA and IA with the use of devices to stabilize the capsule, including iris retractors and capsule expanders, and subsequent injection of a CTR following IOL insertion is both safe and effective so long as risk factors such as nucleus hardness and zonular dialysis extent for poor outcomes are considered. Capsule expanders are T-shaped stabilization hooks with contours that maintain contact between the capsule equator and the pad in proximity to the CCC edge that have particular utility in facilitating fixation of the lens capsule to the sclera [14].

There remains a lack of consensus regarding the duration in which IOL–CTR complex is able to maintain the intended configuration in cases of zonular weakness and dialysis. As recently reported, late spontaneous IOL and CTR dislocation within the intact capsular bag

may occur several years after CTR insertion in cases of zonular weakness [15]. However, the frequency of IOL dislocation during long term follow-up studies is yet to be fully elucidated. CTRs are used to stabilize the capsular bag with the extent of zonular dialysis in addition to the integrity of the other zonule, a major factor when considering their use. In general, CTR insertion may be adapted to cases of zonular dialysis due to ocular trauma or iatrogenic injury during cataract surgery with zonular defects of less than 180 degrees. Despite the dehiscence of the zonules in cases 2, and 4 due to ocular trauma and the zonular remnants considered normal preoperatively, IOL–CTR complex dislocation occurred several months postoperatively that could not be anticipated according to preoperative examination. Case 4 had an ocular traumatic episode and zonular dialysis over 180 degrees during surgery; therefore, the IOL and CTR were inserted to prevent in-the-bag IOL dislocation. Best corrected visual acuity improved to 1.2 postoperatively in this case; however, the patient developed gradual worsening of vision. The major cause of visual disturbance was astigmatism due to increasing IOL–CTR complex dislocation. In this case, the remaining zonular fibers were considered normal preoperatively and the dislocation was repaired by manipulating the CCC edge using a Yaguchi hook [12,13]. Postoperative visual acuity improved; however, the extent of zonular dialysis expanded and the IOL–CTR complex dislocated into the vitreous cavity. Consequently, the complex was extracted and pars plana vitrectomy with suturing of the IOL to the sclera was performed. There are some surgical methods for repositioning the IOL–CTR complex without extraction. Ahmed reported that postoperative CTR subluxation or dislocation could be managed with scleral suture fixation of the CTR through the capsular bag or the use of the capsular tension segment (CTS) with an anteriorly positioned central fixation eyelet that fits anterior to the capsule for scleral suture fixation [15].

Other devices such as capsule anchors, hemi-ring segments [16], and Yaguchi hooks have been used to reposition and suture the complex to the sclera. In cases with IOL–CTR complex and normal remnant zonular fibers (case 4), the use of Yaguchi hooks from 2 to 4 directions for fixation of the capsule is considered superior to a single direction, regardless of the method used. Stabilization was obtained with the use of Yaguchi hooks from three directions in cases 1 and 2, which had circumferential zonular disruption prior to repositioning surgery.

The effectiveness of surgical approaches in maintaining capsular formation should also be considered. Eyes with pseudoexfoliation syndrome often exhibit insufficient mydriasis, zonular weakness, and pronounced fibrotic capsular shrinkage resulting in IOL dislocation [17]. Large CCC formation, CTR insertion, and neodymium:yttrium–aluminum–garnet (Nd:YAG) anterior capsulotomy have demonstrated efficacy in preventing capsular tension segments in early postoperative periods. Kurz reported that CTR has limited efficacy in preventing capsular tension segments; however, reduced capsular bag shrinkage following CTR implantation may reduce the risk of IOL dislocation and help maintain postoperative visual acuity [18].

In the present study, we analyzed the CCC windows of IOL–CTR complex. During repositioning surgery, dislocated IOL was shifted back into the central pupil and static images were captured, allowing the complete view of the entire CCC formation. Careful surgery allowed analysis of the CCC without the original deformation. The present study comprised three cases with traumatic zonular dialysis and one retinitis pigmentosa. The mean CCC, long axis, and short axis sizes of included eyes were 17.5 mm, 4.86 mm, and 4.55 mm,

respectively, with a mean oblateness of 0.05. If the CCC window diameter performed in the first cataract surgery is presumed to measure approximately 5 mm, the CCC area can be calculated as 19.63 mm². When comparing this to the previously calculated CCC size of 17.56 mm², these results indicate slight reductions in CCC areas and that CCC formations maintain a relatively wide circular size. Capsule contraction syndrome may result from CTR insertion in cases of pseudoexfoliation syndrome. Further studies evaluating the efficacy of CTR implantation in maintaining the CCC formation are required.

The present study had a number of limitations. IOL–CTR complex dislocation is not a frequent complication; thus, a small number of patients were included in the present study. The CCC window at initial cataract surgery was assumed to have a circle formation; however, different surgeons performed initial cataract surgery in each of the included cases in this study and CCC sizes were not included in surgical records.

We report the categorization of weak zonules based on findings at capsulorhexis during cataract surgery and demonstrate the utility of classification in informing decisions regarding choice of cataract surgery method and the use of capsular expanders when performing PEA [19]. Greater assessment of zonular weakness is required when considering the use of CTR implantation and risk factors for poor outcomes, including pseudoexfoliation syndrome and post laser iridotomy, should also be evaluated. The indication for CTR implantation has previously been presumed as a zonular defect of less than 180 degrees without precise assessment of residual zonules. Zonular weakness can be detected by the presence of capsular folds at the time of initial CCC, phacodonesis with phacoemulsification, difficulty in rotating lens nuclei, and CCC window deformation following IOL in-the-bag insertion. Surgical manuals and guidelines regarding the use CTR implantation based on zonular weakness during cataract surgery are required.

We conclude that CTR implantation is effective in maintaining the capsular formation postoperatively as a result of the analysis of CCC size and oblateness in cases of zonular weaknesses with IOL–CTR complex dislocation following CTR insertion. However, there have been several reported cases of IOL deviation during the early operative stages. The fact that CTRs are not designed to prevent IOL dislocation over prolonged periods of time should be considered in cases with zonular dialysis.

The use of Yaguchi hooks provided good centralization and stabilization of the IOL–CTR complex in eyes with severely weak zonular fibers providing a simple technique for repositioning of dislocated complex via a corneal side port without IOL extraction. Additional studies evaluating zonular weakness classification during surgery, device selection, including CTRs, and analysis of postoperative changes to CCC windows in cases with risk factors for zonular dialysis are required.

References

1. Tsinopoulos I, Symeonidis C, Frangou E, Dimitrakos SA (2008) Capsule contraction syndrome in eight cases of hydrophobic one-piece intraocular lens implantation. *Clin Exp Optom* 91: 469-472.
2. Venkatesh R, Tan CS, Veena K, Ravindran RD (2008) Severe anterior capsular phimosis following acrylic intraocular lens implantation in a patient with pseudoexfoliation. *Ophthalmic Surg Lasers Imaging* 39: 228-229.
3. Gimbel HV, Condon GP, Kohnen T, Olson RJ, Halkiadakis I (2005) Late in-the-bag intraocular lens dislocation: incidence, prevention, and management. *J Cataract Refract Surg* 31: 2193-2204.
4. Hayashi K, Hirata A, Hayashi H (2007) Possible predisposing factors for in-the-bag and out-of-the-bag intraocular lens dislocation and outcomes of intraocular lens exchange surgery. *Ophthalmology* 114: 969-975.
5. Davis D, Brubaker J, Espandar L, Stringham J, Crandall A, et al. (2009) Late in-the-bag spontaneous intraocular lens dislocation: evaluation of 86 consecutive cases. *Ophthalmology* 116: 664-670.
6. Nagamoto T, Bissen-Miyajima H (1994) A ring to support the capsular bag after continuous curvilinear capsulorhexis. *J Cataract Refract Surg* 20: 417-420.
7. Hara T, Hara T, Yamada Y (1991) "Equator ring" for maintenance of the completely circular contour of the capsular bag equator after cataract removal. *Ophthalmic Surg* 22: 358-359.
8. Nagamoto T, Bissen-Miyajima H (1994) A ring to support the capsular bag after continuous curvilinear capsulorhexis. *J Cataract Refract Surg* 20: 417-420.
9. Bayraktar S, Altan T, Küküksümer Y, Yılmaz OF (2001) Capsular tension ring implantation after capsulorhexis in phacoemulsification of cataracts associated with pseudoexfoliation syndrome. Intraoperative complications and early postoperative findings. *J Cataract Refract Surg* 27: 1620-1628.
10. Jacob S, Agarwal A, Agarwal A, Agarwal S, Patel N, et al. (2003) Efficacy of a capsular tension ring for phacoemulsification in eyes with zonular dialysis. *J Cataract Refract Surg* 29: 315-321.
11. Werner L, Zaugg B, Neuhaan T, Burrow M, Tetz M (2012) In-the-bag capsular tension ring and intraocular lens subluxation or dislocation: a series of 23 cases. *Ophthalmology* 119: 266-271.
12. Yaguchi S, Yaguchi S, Asano Y, Kozawa T, Miyawaki T, et al. (2011) Repositioning and scleral fixation of subluxated lenses using a T-shaped capsule stabilization hook. *J Cataract Refract Surg* 37: 1386-1393.
13. Asano Y, Yaguchi S, Nishimura E, Soda M, Kozawa T (2015) Modified capsule expander implantation to reposition and fixate the capsular bag in eyes with subluxated cataractous lenses and phacodonesis: intermediate-term results. *J Cataract Refract Surg* 41: 598-606.
14. Nishimura E, Yaguchi S, Nishihara H, Ayaki M, Kozawa T (2006) Capsular stabilization device to preserve lens capsule integrity during phacoemulsification with a weak zonule. *J Cataract Refract Surg* 32: 392-395.
15. Ahmed II, Chen SH, Kranemann C, Wong DT (2005) Surgical repositioning of dislocated capsular tension rings. *Ophthalmology* 112: 1725-1733.
16. Jacob S, Agarwal A, Agarwal A, Sathish K, Prakash G et al. (2012) Glued endocapsular hemi-ring segment for fibrin glue-assisted sutureless transscleral fixation of the capsular bag in subluxated cataracts and intraocular lenses. *J Cataract Refract Surg* 38: 193-201.
17. Menapace R (2012) [Pseudoexfoliation syndrome and cataract surgery. Avoidance and treatment of complications]. *Ophthalmologie* 109: 976-989.
18. Kurz S, Krummenauer F, Hacker P, Pfeiffer N, Dick HB (2005) Capsular bag shrinkage after implantation of a capsular bending or capsular tension ring. *J Cataract Refract Surg* 31: 1915-1920.
19. Yaguchi S, Yaguchi S, Asano Y, Aoki S, Hamakawa M, et al. (2015) Categorization and surgical techniques of weak zonule based on findings at capsulorhexis during cataract surgery. *J Clin Exp Ophthalmol* 6: 407.