

# Anesthetic Considerations for Craniopharyngioma Resection in Pediatric Patient with Fontan Physiology: A Case Report

Al Zughaihi Nezar<sup>1</sup>, Mahmoud A Haroun<sup>1\*</sup>, Metwally A Mounir<sup>1</sup>, Mahran A Hamada<sup>1</sup> and Mahmoud M Okasha<sup>2</sup>

<sup>1</sup>King Abdullah Specialized Children Hospital KASCH, Riyadh, Saudi Arabia

<sup>2</sup>Faculty of Medicine, Ain Shams University, Egypt

\*Corresponding author: Mahmoud A Haroun, Department of Anesthesia, King Abdullah Specialized Children Hospital KASCH, Riyadh, Saudi Arabia, E-mail: harounlahm@hotmail.com

Received date: March 13, 2017; Accepted date: April 10, 2017; Published date: April 17, 2017

Copyright: © 2017 Nezar AZ, et al. This is an open access article distributed under the terms of the Creative Commons Attribution License, which permits unrestricted use, distribution, and reproduction in any medium, provided the original author and source are credited.

## Abstract

Fontan procedure is a palliative surgery done for patients born with single ventricle physiology. An understanding of the hemodynamic alterations in such a patient is important for successful perioperative management. Added to this challenge is the Craniopharyngioma which constitute about 2-6% of all the intracranial tumors in pediatric age group. Management of craniopharyngiomas in children is very challenging for anesthesiologist, owing to the developing neurological and physiological status, handling of a growing brain, perioperative endocrinological complications, and the management of hydration. We discuss the anesthetic considerations for a 6 years old female with Fontan circulation going for craniopharyngioma resection under general anesthesia.

**Keywords:** Congenital heart disease; Fontan; Craniopharyngioma; General anesthesia

## Introduction

In 1971, Fontan and Baudet first described a procedure for management of patients with a single ventricle pathology that diverted all systemic venous blood into the pulmonary arteries, without interposition of a ventricle, as a surgical palliation for patients with tricuspid atresia [1]. With advancement of surgical techniques and medical management, many patients with Fontan physiology present for non-cardiac surgeries. Craniopharyngiomas are benign neoplasms commonly located in the sellar or the suprasellar region and most commonly presenting as visual field defects [2-4]. The management of these intracranial tumors poses a challenge for anesthesiologists especially if occurred in a patient with Fontan physiology. Also understanding the Fontan physiology and circulation is essential for safe and successful anesthetic management of these patients. Perioperative diagnosis and management of endocrinological complications of craniopharyngioma is essential for reducing the mortality and morbidity associated with the surgery.

## Case Report

We report here the anesthetic management of 6 years old female weighing 15 kg, electively scheduled for Craniopharyngioma resection. Neurologically, the patient presented with headache, vomiting and seizures. CT brain showed a lesion in the suprasellar cistern extending to the floor of the 3rd ventricle, mild active hydrocephalus at both lateral Ventricles, otherwise cerebellum, basal ganglia and brainstem were normal. Brain MRI showed a bilobed mainly cystic lesion in the suprasellar cistern extending into the sella. The lesion measured 2.3 × 1.7 × 3 cm in anteroposterior, transverse, and craniocervical dimensions respectively encasing the optic chiasma and M1 segment of right middle cerebral artery. It displaced the inferior wall of the lateral ventricles superiorly and caused obstructive supratentorial

hydrocephalus which showed fluid-fluid level indicating hemorrhagic component, pituitary gland was compressed inferiorly by the lesion, brain parenchyma showed normal signal intensity, posterior fossa structures were normal and diagnosed provisionally as Craniopharyngioma (Figure 1).

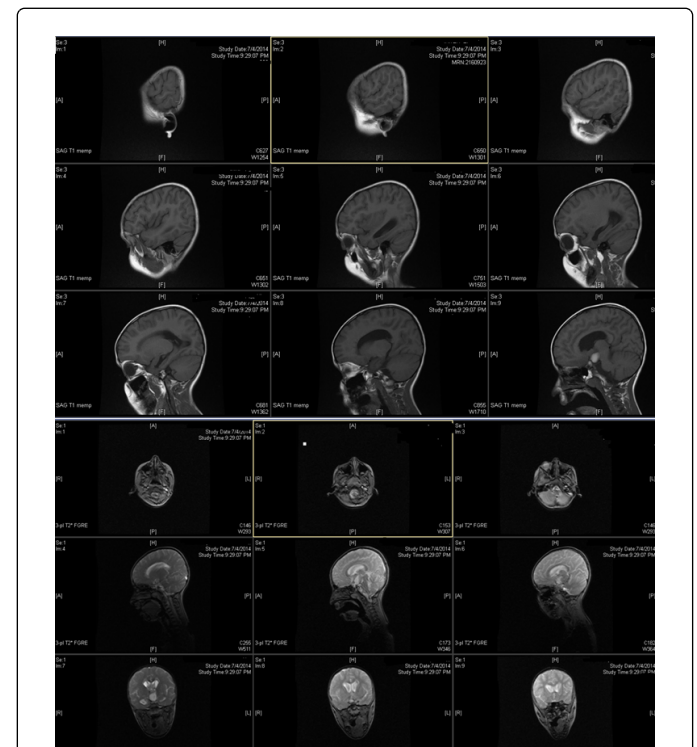


Figure 1: MRI brain.

The patient gave history of complex congenital heart disease in the form of double inlet left ventricle (DILV), pulmonary stenosis (PS). She underwent right Blalock-Taussig (BT) shunt (a right subclavian artery to right pulmonary artery shunt) shortly after birth, followed by a Glenn procedure (anastomosis between superior vena cava and right pulmonary artery) after few months and finally 2 months before craniotomy she had BT shunt dissection and modified Fontan procedure (this time anastomosing the inferior vena cava to the right pulmonary artery). She was on warfarin 5 mg, furosemide 20 mg and Captopril 12.5 mg once a day. Functionally, she had no cardiovascular (CVS) complaints at the time of admission, and was regular in her follow up in pediatric cardiology clinic with fair physical activity. The patient was graded 3 as per the American Society of Anesthesiologists (ASA III).

On examination, she was conscious, oriented, well nourished, afebrile, her heart rate was 82 beats/minute, regular and equal bilaterally, arterial blood pressure was 104/73 mmHg and pulse O<sub>2</sub> saturation (SpO<sub>2</sub>) was 99%. On cardiopulmonary examination there was equal air entry bilaterally with no adventitious sounds and a grade 2 systolic murmur, on neurological examination there was no neurological deficit or visual disturbance and Glasgow Coma Scale (GCS) was 15/15 while other systemic examination was unremarkable.

Investigations revealed hemoglobin of 11.2 g/dL and normal total and differential white blood cell counts. Renal function tests (RFT), liver function tests (LFT), thyroid stimulating hormone (TSH), free T4, blood sugar and serum proteins were within normal limits, serum sodium (Na) was 132 mg/dl, serum cortisol 34 nmol/L and prothrombin time was 22 seconds with an INR of 2.1. Electrocardiogram (ECG) was regular and showed sinus rhythm. Chest X ray showed mild cardiomegally and clear lung fields. Echocardiography showed no obstruction to Fontan pathway, patent bilateral bidirectional glenn, mild left and right atrioventricular valve (AVV) regurgitation and mildly depressed ventricular systolic function. No systemic outflow tract obstruction and no pericardial effusion were seen. There was a normal single ventricle physiology, patent foramen ovale (PFO) with no thrombi or vegetations.

A cardiology consultation was done and recommendation was to bridge warfarin using a low-molecular weight heparin (LMWH) 5 days prior to surgery (40 mg Enoxaparin subcutaneous twice a day to be withheld 12 h prior to surgery), repeat INR one day before the surgery to be less than 1.5 and give prophylaxis against infective endocarditis. Ophthalmic Consultation for fundus examination showed normal confrontation visual fields but she was not so cooperative to complete visual fields.

On the day of surgery the patient was reassessed and infective endocarditis prophylaxis was given in form of cefazolin 50 mg/kg 1 h prior to the procedure. She was premedicated using intravenous (IV) midazolam 0.1 mg/kg, and then she was taken to the operating room. Standard monitors were applied in the form of 5-leads Electrocardiogram (ECG), non-invasive arterial blood pressure (NABP) and pulse oximetry. Anesthesia was induced using IV ketamine 2 mg/kg, IV fentanyl 2 µg/kg, IV rocuronium 1 mg/kg and was intubated uneventfully with cuffed endotracheal tube size 5.5 mm. Right radial artery was cannulated for invasive arterial blood pressure (IABP) monitoring and left femoral vein was cannulated for central venous pressure (CVP) monitoring. Capnography, urinary catheter and temperature monitoring were also established. Anesthesia was maintained with sevoflurane in oxygen: air (40:60) keeping Minimum alveolar Concentration (MAC) 0.5-1.2, titrating rocuronium for

muscle relaxation according to the train of four (TOF). By the end of the procedure, total fentanyl used was 110 mcg and rocuronium was 50 mg. Steroid replacements with 4 mg Dexamethasone was given intravenously with induction of anesthesia.

The patient was ventilated using pressure controlled (PC) ventilatory mode with peak inspiratory pressure (PIP) of 15 cmH<sub>2</sub>O, respiratory rate (RR) 18 bpm and Positive End Expiratory Pressure PEEP 4 cmH<sub>2</sub>O. The end-tidal carbon dioxide was maintained within the range of 30-35 mmHg. Her blood pressure and heart rate were stable throughout the procedure, and maintained within 20% of the baseline values. The patient developed transient mild Diabetes insipidus (DI), UOP was more than 6 ml/Kg/h and serum Na in blood gases was in range of 135-139 mg/dL. It was successfully managed with urine output monitoring hourly and replacing IV fluids.

Surgery lasted 6 h 24 minutes in supine position with 30 degree head up to provide adequate surgical exposure and venous drainage with total blood loss around 100 ml. At the end of the procedure further analgesia was given in form of 1.5 mg of IV morphine and 250 mg of IV paracetamol, 0.2 mg of IV Granisetron was given to prevent postoperative nausea and vomiting and reversal of muscle relaxant was done using 0.15 mg of IV glycopyrrolate and 0.75 mg of IV neostigmine for the planned extubation. The patient was extubated successfully in the operating theater and was hemodynamically stable having a BP of 110/64 mmHg, HR of 119 bpm and SpO<sub>2</sub> of 100%. Patient was transferred to PICU for further hemodynamic and neurological monitoring. Monitoring UOP, plasma and urinary Na and osmolality for possible diabetes insipidus (DI) was mandatory.

Postoperatively she had manifestations of DI that continued for the next 2 days and was successfully managed using intranasal desmopressin (10 µg per puff) administered one puff two times daily together with replacing IV fluids and urine output monitoring hourly. The child recovered well thereafter and a computed tomography (CT) scan after surgery revealed a small amount of residual lesion in suprasellar. Anticoagulant was resumed in the postoperative period after ensuring adequate homeostasis according to bridging protocol. The histopathological examination confirmed the diagnosis of craniopharyngioma. The patient was discharged on the 10th postoperative day and was prescribed chemotherapy and regular follow-up.

## Discussion

Neurosurgery in the pediatric patients is a challenge not only for the neurosurgeon but also for anesthesiologist due to neurophysiological variations between adult and pediatric population [1]. CBF in infants and older children (about 90 to 100 mL/100 g/min) is higher than the adult CBF (50 mL/100 g/min). Also there is tight coupling between CBF and the metabolic requirement for oxygen (CMRO<sub>2</sub>). CMRO<sub>2</sub> in children is 5.2 mL/100 g/min, which is again higher than the CMRO<sub>2</sub> in the adults (3.5 mL/100 g/min). Thus, children are more liable for hypoxia-ischemic insult more than the adult. Cerebral auto-regulation exists in the pediatric brain and any extreme variations in blood pressure beyond the limits of auto-regulation place the child at a risk of developing cerebral ischemia or intraventricular hemorrhage. The large head in children represents a large percentage of body surface area and blood volume and so a large volume of their cardiac output is directed to the brain, thus, increasing the risk of hemodynamic instability in the perioperative period [2].

Craniopharyngiomas represent about 2-6% of all the intracranial tumors in the pediatric population [3]. These benign neoplasms are commonly located in the sellar or the suprasellar region, thus, most commonly presenting with mass effect on nerves (commonly present by visual field defect), vessels or hypothalamic pituitary disorder which may present with endocrine abnormalities [2,3,4]. Thus, preoperative screening and optimization for any hormonal imbalance is essential. Perioperative steroid replacement therapy is also required. Risk of DI preoperatively (8-35%), rarely intraoperatively, but most commonly in the postoperative period (70-90%) which causes large volumes of urine loss that need to be replaced on an hourly basis. DI may even require pharmacological treatment with synthetic vasopressin (DDAVP or desmopressin) if the resultant hypovolemia is not corrected with fluids [4]. Management of craniopharyngioma poses a challenge for neurosurgeons, endocrinologists, oncologists as well as anesthesiologists on account, includes surgical resection and post-surgery radiotherapy/chemotherapy for residual lesion [5,6].

Due to modification of surgical techniques and medical care, patients with congenital heart diseases for noncardiac surgeries expanded and became an important health care issue [7]. One of these patients are patients with fontan physiology which represent a unique challenge for the anesthesiologists during the perioperative period, so understanding the fontan physiology circulation is essential for safe and successful anesthetic management of these patients. It is recommended for those patients to be managed at centers where the relevant cardiologist and intensive care unit expertise are available. Anesthesiologists who care for them must be familiar with the fontan physiology and perioperative management to optimize outcomes because congenital heart disease is a risk factor for increased mortality for non-cardiac surgery [7].

In 1971 Fontan and Baudet [8], described a right atrial to pulmonary artery shunt procedure for tricuspid atresia. It involved diverting systemic venous blood from the right atrium to the pulmonary arteries, thus bypassing the right ventricle. This can be done in two ways:

Lateral tunnel Fontan where a baffle is placed inside the atrium to direct the systemic venous blood from the Inferior Vena Cava (IVC) to the lungs.

Extra cardiac where the inferior vena cava is split from the heart and anastomosed to the pulmonary artery using a conduit. A fenestration is created between the right atrium and the conduit which reduces the chance for pleural effusion to develop when the pulmonary vascular resistance (PVR) becomes significantly raised [7].

The fontan circulation functions by passive flow of the systemic venous return to the pulmonary vasculature and then to the single ventricle. So, pulmonary blood flow and cardiac output are the result of the pressure difference between the "upstream" component (consisting of the caval veins and the pulmonary artery) and the "downstream" component [9] (the pulmonary veins/atrium/single ventricle system). The ideal systemic venous pressure of Fontan circulation is approximately 10-15 mmHg and the pulmonary venous atria (functional left atrium) pressure is approximately 5-10 mmHg; so it allows a Trans pulmonary gradient driving pressure of 5-8 mmHg. Any factor that affects this gradient could compromise the single ventricle filling and hence the CO [9,10]. So patent fontan circulation depend on:

1) Adequate the upstream component flow which depends on a) unobstructed venous return from IVC and Superior Vena Cava (SVC),

b) adequate preload, c) patent anastomotic connections between the caval veins and pulmonary arteries and d) low intra-thoracic pressure.

2) Adequate downstream component which requires unobstructed pulmonary arterial/pulmonary venous flow a) low PAP (<15-20 mmHg), and b) low PVR

Patients with fontan physiology also have baseline venoconstriction to maximally augment the preload and therefore anesthetics that cause venodilatation can lead to cardiac instability by detrimental effect to CO [11]. So CO is maintained by adequate ventricular filling, normal AV valve, adequate diastolic and systolic function and normal sinus rhythm. Alterations in ventricular function or the onset of arrhythmias can lead to decreased CO and symptomatic deterioration [7].

Late complications of fontan include progressive myocardial dysfunction and failure [12], atrial arrhythmias which are extremely resistant to pharmacological therapy and causing rapid hemodynamic deterioration and heart failure [13], protein losing enteropathy which presents with oedema, immunodeficiency, ascites and fat malabsorption [14], chronic hepatic venous congestion which progress to centrilobular necrosis, fibrosis and cirrhosis [15], and renal dysfunction due to systemic venous hypertension and reduced renal Perfusion [13]. Patients with fontan physiology are at high risk of thromboembolism, due to low flow states, arrhythmias, and hypercoagulability. Bridging therapy should be prescribed to patients on warfarin until treatment can be continued [16-18]. Risk of infective endocarditis, so perioperative antibiotic prophylaxis with broad spectrum cover is required. The risk of air or fat emboli occurring during major surgery especially head and neck surgery is relatively high in patients with a fenestrated fontan. So some cardiologists recommend closing a fenestration preoperatively for patients undergoing high risk surgery [7].

During the preoperative evaluation for the patients with fontan physiology undergoing craniopharyngioma resection, it is important to consider the congenital structural pathology, degree of palliation completed at the time of assessment, the functional status, and comorbidities found in these patients which varies significantly [7]. Neurological examination (sensorium, cranial nerves, and any evidences of raised intracranial pressure) [1], so evaluation of these patients involves a detailed history and physical examination using a multisystem approach with attention to the unique characteristics of this patient population (cardiac and neurological). A detailed medical history should focus on changes in health status, exercise tolerance, current medication, hospital admissions, thorough physical examination, and baseline hematological, coagulation and biochemical investigations (electrolyte, renal and hepatic function) are always necessary even before minor surgery [7]. In addition, children with pituitary tumors require complete endocrinological evaluation [1]. A 12-lead ECG and echocardiography also required for assessment of rhythm, ventricular and valvular function, pulmonary vascular resistance and ventricular end diastolic pressure [7].

Intraoperatively, our anesthetic goal is to maintain adequate CO (as a slight compromise in CO can be hazardous) and maintaining adequate cerebral perfusion and oxygenation. Also we have to ensure adequate preload, maintain good ventricular filling and contractility while avoiding an increase in afterload. Since the blood flow from the systemic veins to the pulmonary circulation is passive, any increase in PVR can impair ventricular filling and CO. Consequently, it is important to avoid any factor increase the PVR that may be precipitated by hypercarbia, hypoxia, acidosis, inadequate analgesia or

anesthesia, hypothermia, use of vasoactive drugs, excessive mean airway pressure, and compression of the lung by pleural effusion or high PEEP [7].

So anesthesiologists should choose induction agents with the least effect on myocardial contractility, cardiac output and pulmonary blood flow [7]. Propofol may cause profound decreases in venous return and myocardial depression. Etomidate is a suitable induction agent for the preservation of myocardial contractility, PVR, and vascular tone [19,20]. Ketamine may be used but it increases PVR and myocardial oxygen consumption [21]. It is advisable to avoid muscle relaxants that cause histamine release, which can result in hypotension and tachycardia which adversely affect the COP and cerebral perfusion. Succinylcholine and rocuronium are recommended for rapid sequence induction because of their minimal vagolytic and minimal histamine release properties. Cisatracurium and vecuronium are also useful for their stable hemodynamic properties [22]. High concentrations of volatile agents should be avoided due to its dose dependent myocardial depression. Thus, a low concentration of an inhalational agent in combination with an infusion of a short acting opioid provides a cardio stable anesthetic [23].

In addition to standard monitoring, Central Venous Pressure (CVP) and invasive arterial monitoring are mandatory in Fontan patient as we are expecting significant volume shift. Monitoring the trend of the CVP can help in the assessment of vascular volume status, as it reflects only mean pulmonary artery pressure (mPAP) and not ventricular preload. Transesophageal echocardiography (TEE) can be used not only for intraoperative assessment of ventricular preload and function but also for early detection of air emboli [7] (unfortunately it was unavailable in our case). Monitoring of UOP on hourly base is mandatory for early detection of DI [2].

Inadequate pulmonary blood flow may occur due to hypovolemia or increased pulmonary vascular resistance (PVR) [13]. Although positive intrathoracic pressure may limit antegrade flow or even reverse flow in these systemic venous beds [23], controlled ventilation is used for prolonged and major surgery. Controlled ventilation with a ventilator strategy of low mean airway pressure, moderate alkalosis (PH=7.45, pCO<sub>2</sub>=35 mmHg), tidal volume of 5-6 ml/kg, low respiratory rate, short inspiratory times, low PEEP usually allow adequate pulmonary blood flow with minimal hemodynamic effects [7].

Surgical intervention may be associated with possible neuronal damage to the thalamus and the mammillothalamic tract, that is more in cases of developing brains of pediatric population and damage to nerves in the surgical site vicinity. Our patient had developed DI during the postoperative period that was managed with intranasal desmopressin along with fluid management and UOP monitoring each hour [5,6]. Postoperatively, these patients should be admitted to a monitored unit (ICU) to maintaining adequate analgesia, ensuring adequate ventilation, fluid management and providing supplemental oxygen are essential [7]. Also monitoring of UOP, fluid management and controlling of any endocrinal emergency [1].

## Conclusion

The most significant risk in this patient condition combined with Fontan physiology is the acute cardio-vascular collapse at induction of anesthesia, loss of reserve due to hypovolemia because of the high UOP and possible surgical bleeding. That's why generous IV fluid resuscitation to more than normal filling of the heart, slow titration of

aesthetic agents to minimize excessive peak depressant effects, care to minimize the circulatory effects of positive pressure ventilation, intensive and invasive monitoring of the circulation throughout the procedure and rapid access to cardiovascular resuscitation drugs such as inotropes and vasopressors are corner-stones of management in such a case.

## References

1. Bhatnagar V, Dwivedi D, Tandon U, Bhushan K (2015) The challenges in anesthetic management of pediatric craniopharyngioma, *Karnataka Anaesth J* 1: 205-207.
2. Krass IS (2007) Physiology and metabolism of brain and spinal cord. In: *Handbook of Neuroanaesthesia*. Philadelphia: Lippincott Williams & Wilkins 3-22.
3. Haupt R, Magnani C, Pavanello M, Caruso S, Dama E, et al. (2006) Epidemiological aspects of craniopharyngioma. *J Pediatr Endocrinol Metab* 19 Suppl 1: 289-293.
4. Karavitaki N, Cudlip S, Adams CB, Wass JA (2006) Craniopharyngiomas. *Endocr Rev* 27: 371-397.
5. Takahashi H, Yamaguchi F, Teramoto A (2005) Long-term outcome and reconsideration of intracystic chemotherapy with bleomycin for craniopharyngioma in children. *Childs Nerv Syst* 21: 701-704.
6. Bajwa SJ, Bajwa SK, Bindra GS (2011) The anesthetic, critical care and surgical challenges in the management of craniopharyngioma. *Indian J Endocrinol Metab* 15: 123-126.
7. Kothandan H, Leanne LM, Shah SKS (2015) Fontan Physiology: Anaesthetic Implications for Non-Cardiac Surgery: A Case Report. *Int J Anesthetic Anesthesiology* 2: 020.
8. Fontan F, Baudet E (1971) Surgical repair of tricuspid atresia. *Thorax* 26: 240-248.
9. McGowan F (2005) Perioperative issues in patients with congenital heart disease. *International Anesthesia Research Society, Review course lectures* 53-61.
10. Motoyama KE, Davis PJ (1996) *Smith's Anesthesia for infants and children* (6th edn) 445-539.
11. McClain CD, McGowan FX, Kovatsis PG (2006) Laparoscopic surgery in a patient with Fontan physiology. *Anesth Analg* 103: 856-858.
12. Piran S, Veldtman G, Siu S, Webb GD, Liu PP (2002) Heart failure and ventricular dysfunction in patients with single or systemic right ventricles. *Circulation* 105: 1189-1194.
13. Nayak S, Booker PD (2008) The Fontan Circulation. *Contin Educ Anaesth Crit Care Pain* 8: 26-30.
14. Mertens L, Halper DJ, Sauer U, Somerville J, Gewillig M (1998) Protein-losing enteropathy after the Fontan operation: An international multicenter study. *J Thorac Cardiovasc Surg* 115: 1063-1073.
15. Narkewicz MR, Sondheimer HM, Ziegler JW, Otanni Y, Lorts A, et al. (2003) Hepatic dysfunction following the Fontan procedure. *J Pediatr Gastroenterol Nutr* 36: 352-357.
16. Coon PD, Rychik J, Novello RT, Ro PS, Gaynor JW, et al. (2001) Thrombus formation after the Fontan operation. *Ann Thorac Surg* 71: 1990-1994.
17. Weipert J, Noebauer C, Schreiber C, Kostolny M, Zrenner B, et al. (2004) Occurrence and management of atrial arrhythmia after long-term Fontan circulation. *J Thorac Cardiovasc Surg* 127: 457-464.
18. Walker HA, Gatzoulis MA (2005) Prophylactic anticoagulation following the Fontan operation. *Heart* 91: 854-856.
19. Sprung J, Ogletree-Hughes ML, Moravec CS (2000) The effects of etomidate on the contractility of failing and nonfailing human heart muscle. *Anesth Analg* 91: 68-75.
20. Andropoulos DB, Stayer SA, Skjonsby BS, East DL, McKenzie ED, et al. (2002) Anesthetic and perioperative outcome of teenagers and adults with congenital heart disease. *J Cardiothorac Vasc Anesth* 16: 731-736.

- 
21. Lovell AT (2004) Anaesthetic implications of grown-up congenital heart disease. *Br J Anaesth* 93: 129-139.
  22. Naguib M, Samarkandi AH, Bakhamees HS, Magboul MA, el-Bakry AK (1995) Histamine-release haemodynamic changes produced by rocuronium, vecuronium, mivacurium, atracurium and tubocurarine. *Br J Anaesth* 75: 588- 592.
  23. Redington AN, Penny D, Shinebourne EA (1991) Pulmonary blood flow after total cavopulmonary shunt. *Br Heart J* 65: 213-217.