

Anaesthetic Management of a Case of Giant Pulmonary Bulla Undergoing Laparoscopic Cholecystectomy

Bhaskar Dutta^{1*} and Gangaprasad²

¹Trust Registrar, Dept of Anaesthetics, Peterborough Hospital NHS Foundation Trust, Bretton Gate, Peterborough, Post code: PE3 9GZ, UK

²Add. Prof, All India Institute of Medical Sciences, Ansari Nagar, New Delhi, India, 110029

Summary

Anaesthetic management of a patient with giant lung bulla who undergoes laparoscopic surgery deserves special considerations in view of the possible complications associated with the bulla. There may be acute enlargement or rupture of the bulla, necessitating emergency management. Precautionary measures which may be taken during anaesthesia include the avoidance of nitrous oxide, keeping low airway pressures during the surgery, immediate availability of chest drains in the anaesthetizing area and continuous monitoring including auscultation of the chest, observing airway pressures and arterial blood gas analysis.

Keywords: General anaesthesia; Pulmonary bulla

Introduction

Patients with coincidental bullous lesions of the lung occasionally present for non-thoracic surgeries. These patients are at increased risk during anaesthesia from potential complications which may arise from the bullae or underlying lung disease. The anaesthetic technique of choice in patients with bullae involves elimination of nitrous oxide together with spontaneous ventilation during the surgery [1-3]. Use of neuromuscular agents sometimes becomes inevitable due to coexisting conditions or in view of certain surgical procedures, which necessitates the use of Intermittent Positive Pressure Ventilation (IPPV). IPPV may result in over inflation of a bulla if it communicates with the airway. However, non-communicating bullous lesions might also rupture and produce pneumothorax. We hereby present the anaesthetic management of an elderly patient with a giant bulla, undergoing laparoscopic cholecystectomy, which warranted the use of IPPV.

Case Report

A 62 year (40 kg) female patient was posted for laparoscopic cholecystectomy for gall stone disease.

The patient was a non-smoker and known case of bronchial asthma since 20 years and was on some homeopathic medication, which was stopped 15 days back. She never required hospital admission for exacerbation of her asthma in the past and was asymptomatic at rest. However, she had dyspnea on moderate exertion. On admission to the hospital, she was started with Theophylline 150 mg twice daily, combined Formoterol-levoSalbutamol inhaler thrice daily and combined Ipratropium-Salbutamol nebulisation 6 hourly.

The patient also had history of pulmonary tuberculosis 10 years ago, for which she took anti tubercular treatment for 9 months and was declared cured. She was diagnosed as having a pulmonary bulla on her right lung, soon after resolution of tuberculosis, following a chest X-ray.

She also had hypertension for the past 5 years, which was controlled with Amlodipine 5 mg and Atenolol 50 mg, both once daily. Her blood pressure on admission was 136/90 mm Hg. A serial blood pressure recording showed values consistently below 140/90 mm Hg. Rest of the physical examination revealed no abnormality except for decreased air entry in the middle and lower zones of the right lung on auscultation.

Her preoperative biochemical investigations and Electrocardiogram (ECG) were within normal limits. However, chest X-ray [Figure

1] showed a giant bulla in the right middle and lower lung zones. Pulmonary function test revealed severe airflow limitation, with Forced Vital Capacity (FVC) 82% of predicted, forced expiratory volume in 1 second (FEV₁) was 50% of predicted, ratio of forced expiratory volume in 1 second to forced vital capacity (FEV₁/FVC) was 65% of predicted and Peak Expiratory Flow Rate (PEFR) was 45% of predicted. There was ineffectual cough mechanism and slight reversibility with bronchodilators. A High Resolution Computerised Tomography (HRCT) of the chest revealed multiple para septal emphysematous bullae in both lungs

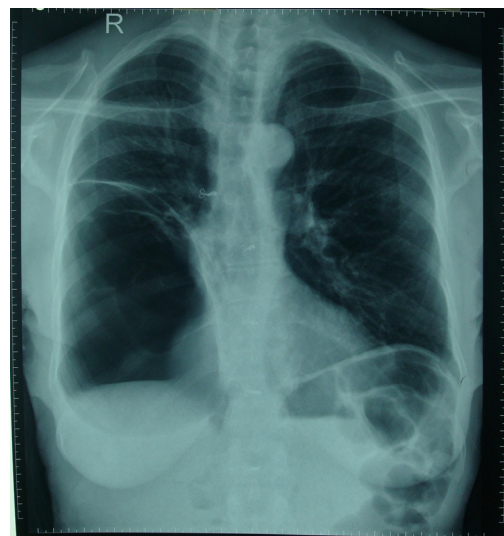


Figure1: PA view X-ray of the chest showing the "Giant" Lung bulla in the middle-lower zones of the right lung.

***Corresponding author:** Dr. Bhaskar Dutta, Deptt of Anaesthetics, Peterborough Hospital NHS Foundation Trust, Bretton Gate, Peterborough, Post code: PE3 9GZ, UK, Tel: +44 – 7729963759; Fax: +44 - 1733 – 678533, E-mail: dr_dbhaskar@yahoo.com

Received May 24, 2012; Accepted May 29, 2012; Published May 31, 2012

Citation: Dutta B, Gangaprasad (2012) Anaesthetic Management of a Case of Giant Pulmonary Bulla Undergoing Laparoscopic Cholecystectomy. J Anesth Clin Res 3:214. doi:10.4172/2155-6148.1000214

Copyright: © 2012 Dutta B, et al. This is an open-access article distributed under the terms of the Creative Commons Attribution License, which permits unrestricted use, distribution, and reproduction in any medium, provided the original author and source are credited.

(largest one in right lower lobe with underlying band like atelectasis) and fibro calcific lesions in left lower lobe with patchy areas of ground glass appearance. The opinion of a respiratory physician was also taken and the bulla was diagnosed to be non-communicating with the airway. Her room air saturation was 92-93% and room-air arterial blood gas analysis showed a pH of 7.36, pO₂ of 91 mm Hg, pCO₂ of 45 mm Hg, HCO₃⁻ of 20 meqV-L⁻¹, SaO₂ of 91.1%.

Preoperatively, patient's respiratory functions were optimised as far as possible, with chest physiotherapy. However, due to the presence of the giant bulla in her right lung, further improvement in her respiratory parameters was unlikely.

The patient was premeditated with alprazolam 0.25 mg on the night before surgery and oral pantoprazole 40 mg on the morning of surgery. She received the morning doses of inhaled formoterol-levosalbutamol and also nebulisation with ipratropium-salbutamol before coming to the operating room (OR). Upon arrival at the OR, all the routine monitors were applied including ECG, Non-Invasive Blood Pressure (NIBP) and pulse oximetry (SpO₂). Before induction of anaesthesia, a surgical trolley with chest tube and other necessary equipments were kept ready, in order to manage an inadvertent pneumothorax.

She was induced with intravenous fentanyl 80 µg and propofol 80 mg and incubated with 7.5 mm Endotracheal Tube (ETT) after administering 4 mg of vecuronium. The cuff of the ETT was inflated with 4 ml of air (just sufficient to prevent leak at an airway pressure of 15 cm H₂O). Anaesthesia was maintained with oxygen-air (FiO₂ of 0.5) and isoflurane (MAC 0.8 – 1.2) with intermittent doses of vecuronium and pressure controlled ventilation with a Peak Inspiratory Pressure (PIP) of 15 cm H₂O or less. Analgesia was maintained with intermittent intravenous doses of fentanyl (20-40 µg) and 1 g of paracetamol (infusion) was administered as well. In addition, port-site infiltration with local anaesthetic was also carried out.

As the surgeons started to create pneumoperitoneum, it was ensured that the intraabdominal pressure was kept constant at 10 mm Hg. Before creation of pneumoperitoneum, a PIP of 13 cm H₂O delivered a tidal volume of around 400 ml and an acceptable end-tidal CO₂ (EtCO₂) of around 30-35 mm Hg was ensured with a respiratory rate of 10 breaths per minute (bpm). Following pneumoperitoneum, the tidal volume delivered at a PIP of 13 cm H₂O became insufficient with around 125 to 180 ml and EtCO₂ gradually increased to 58 mm Hg. The PIP was then increased to 15 mm Hg and respiratory rate to 14 bpm which ensured a tidal volume of around 225 to 300 ml and an EtCO₂ of around 36-40 mm Hg. Frequent auscultation of the chest and monitoring of her haemodynamic parameters were carried out throughout the procedure. Her oxygen saturation remained at or above 98% intra operatively and an ABG showed normal blood gas values. The procedure was completed without any adverse consequences.

Postoperatively, the patient was shifted to the high dependency unit and was monitored carefully. Postoperative analgesia was maintained with intramuscular/intravenous tramadol 50 mg 6 hourly and intravenous paracetamol 1 g 8 hourly. Chest physiotherapy and incentive spirometry were started along with resumption of her oral medications on the first postoperative day. The patient recovered without any complications and was discharged on the third postoperative day.

Discussion

The incidence of patients with giant lung bulla, undergoing non-thoracic surgery is not available in the literature, which indicates the rarity of this condition. On the other hand, articles describing anaes-

thetic and surgical management of bullous lung diseases are frequently available. However, the anaesthetic management in patients with bullous lung disease, undergoing thoracic and non-thoracic surgery is grossly different.

Pulmonary "bullae" are pathologically dilated air spaces distal to the terminal bronchiole and are more than 2 cm in diameter in the distended state [4]. By convention they are called "giant bullae" when they occupy over one half the volume of the hemithorax. Some literatures describe giant bullae as those which encompass more than one-third of the lung volume [5]. Giant bullae are commonly found with paraseptal emphysema, but they may also occur in association with progressive fibrotic lung disorders [6-8].

The most important complications of bullae include infection, spontaneous pneumothorax, and haemorrhage into a bulla. Spontaneous pneumothorax is a frequent and serious complication in patients with bullous disease, more so in patients with compromised lung function. It occurs in about 15% of such patients [9]. Primary spontaneous pneumothorax occurs in the absence of known lung disease; the risk factors being male sex, smoking and a family history of pneumothorax. Secondary spontaneous pneumothorax occurs in patients with underlying lung disease, such as chronic obstructive lung disease, acute severe asthma, cystic fibrosis, interstitial lung disease, tuberculosis, connective tissue diseases, lung cancer etc.

Asymptomatic bullae are treated conservatively by reassurance, advice to stop smoking, avoid strenuous activities that can promote the rupture of the bullae. Patients are advised an annual chest radiograph and an alert for a prompt visit to a physician should symptoms develop. The decision to operate is often a challenging one. Patients should undergo surgical resection when they have incapacitating dyspnea with large bullae that fill more than 30% of the hemithorax and result in the compression of healthy adjacent lung tissue [9]. In addition, operation is indicated for patients who have complications related to bullous disease such as infection or pneumothorax [10]. The patient in discussion had fairly good functional capacity with no symptoms at rest, thus obviating the need for any type of surgery of the bullous lung lesion.

The problems associated with anaesthesia for the patient with a giant bulla are two-fold: firstly, the possibility of further enlargement of the bulla occurring under anaesthesia and, secondly, the general problems associated with the disease (usually emphysema) in the remaining lung tissue. Maintenance of high FiO₂ in perioperative period is a desired goal in the management of these patients. If the bulla communicates with the bronchial tree, Positive Pressure Ventilation (PPV) may cause it to expand or rupture and a situation like tension pneumothorax may be produced. If the bulla is highly compliant, tidal volume may be wasted in the form of dead space ventilation. Nitrous Oxide should be avoided whatever the mode of ventilation may be. It causes expansion of air filled cavities in the body because it is 34 times more diffusible than Nitrogen gas.

Laparoscopic procedures are a further threat to the safe management of patients with giant pulmonary bullae. This is not only because of creation of pneumoperitoneum and the resultant rise in intra-abdominal pressure, but also because of different patient positioning required for the surgery, which compromises respiratory functions further. However, laparoscopic cholecystectomy requires the patient to be placed in the reverse trendelenberg position with slight elevation of the right lateral side and this position does not, in itself, cause respiratory compromise.

Prevention of postoperative sore throat is very important in these patients, as this might lead to frequent coughing and subsequently undue stress to the pulmonary bullae. We ensured this by insufflating the pilot balloon of the ETT with only 4 ml of air, which was sufficient to prevent leak at 15 cm H₂O airway pressure.

To conclude, avoidance of nitrous oxide, keeping low airway and intraabdominal pressures during the surgery are basic measures for a safe outcome in laparoscopic surgeries in patients with an underlying bulla. Apart from that, immediate availability of chest drains in the anaesthetizing area and continuous monitoring including auscultation of the chest and arterial blood gas analysis should be carried out in order to urgently detect any adverse consequences during the surgery.

References

1. Gray TC, Edwards FR (1948) The anaesthetic problems associated with giant tension cysts of the lung. *Thorax* 3:237.
2. Brown AI (1966) Anaesthesia for the respiratory cripple. *Proc R Soc Med* 59:522-527.
3. Skivington MA (1973) Respiratory Diseases. In, *Anaesthesia and Uncommon Diseases: Pathophysiologic and Clinical Correlations.* (ed.) Katz, J. & Kadis, L.B. Toronto: Saunders, p. 176.
4. CIBA Guest Symposium (1959) Terminology, definitions, and classification of chronic pulmonary emphysema and related conditions. *Thorax* 14: 286-99.
5. Shah NN, Bhargava R, Ahmed Z, Pandey DK, Shameem M, et al. (2007) The vanishing lung Lung India *CJEM* 924: 233-234.
6. Ogilvie C, Catterall M (1959) Patterns of disturbed lung function in patients with emphysematous bullae. *Thorax* 14: 216-224.
7. Welch MH (1977) Variants of emphysema and miscellaneous disorders of airways. In, *Pulmonary Medicine* (ed.) Guenter, C.A. and Welch, M.H. Toronto: Lippincott Co., p. 650.
8. Crofton J, Douglas A (1975) *Respiratory Diseases.* 2nd ed. Oxford: Blackwell Scientific Publications, p. 350.
9. Greenberg JA, Singhal S, Kaiser LR (2003) Giant bullous lung disease: evaluation, selection, techniques, and outcomes. *Chest Surg Clin N Am* 13:631-649.
10. Vigneswaran WT, Townsend ER, Fountain SW (1992) Surgery for bullous disease of the lung. *Eur J Cardiothorac Surg* 6:427-430.