

## An Update on Tubercular Uveitis

Manisha Agarwal\* and Ankita Shrivastav

Shroff's Charity Eye Hospital, New Delhi, India

\*Corresponding author: Manisha Agarwal, Shroff's Charity Eye Hospital, New Delhi, India, Tel: +91-9811584615; E-mail: agarwalmannii@yahoo.co.in

Received date: July 04, 2017; Accepted date: August 09, 2017; Published date: August 24, 2017

Copyright: ©2017 Agarwal M, et al. This is an open-access article distributed under the terms of the Creative Commons Attribution License, which permits unrestricted use, distribution, and reproduction in any medium, provided the original author and source are credited.

### Abstract

Tuberculosis (TB) is an important cause of infectious uveitis causing significant morbidity and mortality especially in endemic countries. *Mycobacterium tuberculosis* (MTb) may infect any tissue or organ in the body, lungs being the most commonly affected. Ocular TB occurs due to hematogenous dissemination of MTb or due to a hypersensitivity reaction to the bacteria. It may lead to a very severe inflammation and destruction of ocular tissues leading to an irreversible loss of vision. Infection of the eye by MTb most commonly involves the uveal tissue causing anterior, intermediate, and posterior or panuveitis.

Awareness of the varied clinical manifestations is important to suspect the ocular TB which may often be difficult to confirm by diagnostic tests available. A timely diagnosis and management may help in preventing severe loss of vision and the eye.

**Keywords:** *Mycobacterium tuberculosis*; Ocular TB; Panuveitis

### Introduction

Tuberculosis is a multi-system disease caused by the obligate aerobic acid fast bacilli *Mycobacterium tuberculosis* (MTb) [1]. TB mainly affects the lungs and may have various extrapulmonary sites of involvement including ocular TB. The Centers for Disease Control and Prevention (CDC) estimates that one third of the world's population is infected with TB. However, only 10% of this population develops systemic manifestations whereas 90% have latent TB who may show activation at any time during their life [2]. An increasing trend of extrapulmonary tuberculosis was seen from 16% in 1992 to 21% in 2002 of all reported cases of tuberculosis to the CDC (Table 1) [3]. The incidence of ocular TB ranges from 1.45% to 5.74% [4]. TB is no longer limited to under-developed nations and people from lower socio-economic groups. This resurgence of TB could possibly be due to the increased migration and globalization, overcrowding and a corporate culture, immunosuppression especially in the form of human immunodeficiency virus (HIV) and hepatitis virus infection [5-8].

United States of America [9]	0.5%
People's Republic of China [10]	4.0%
Italy [11]	6.31%
Japan [12]	6.9%
India [13]	9.86%
Saudi Arabia [14]	10.5%
Iraq [15]	11.4%

**Table 1:** Prevalence of TB as an etiology of uveitis.

Uveitis is the commonest manifestation of tubercular infection of the eye. However confirming the diagnosis may not always be possible.

It remains unclear whether ocular involvement is a result of direct infection of the ocular tissue or a hypersensitivity reaction.

### Pathogenesis

MTb being an obligate aerobe affects organs in the body with high oxygen tension such as the lungs, kidneys, bone, meninges and choroid in the eye [4,16]. The uveal tract in the eye has a high blood supply making it the commonest ocular site for TB [16]. Ocular TB may not always have clinical evidence of systemic TB [17].

Ocular TB may develop as a primary disease wherein the eye is the primary site of involvement. Primary disease usually affects the conjunctiva, cornea, sclera and the ocular adnexa. Secondly the MTb may disseminate to the ocular tissues from a distant site in a hematogenous manner. Thirdly, the disease may manifest as a hypersensitivity reaction to MTb antigens present at a distant focus leading to inflammation despite the absence of the bacterium in the eye [18,19].

The retinal pigment epithelium (RPE) is said to provide a conducive environment to harbor MTb by phagocytosing the bacilli within the RPE cells [20]. Various studies have demonstrated MTb bacilli within the RPE cells [21,22].

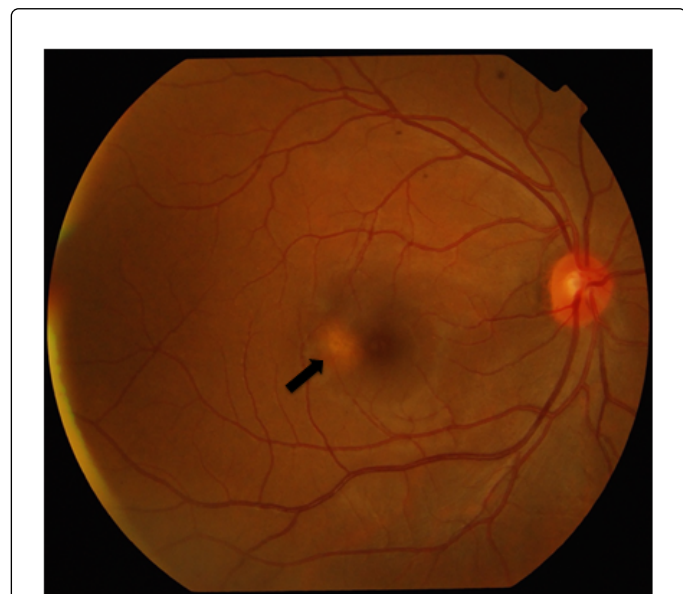### Clinical manifestations

Uveitis may be anterior, intermediate or posterior. Tubercular anterior uveitis manifests as a granulomatous uveitis which is often associated with a spill-over vitritis. Intermediate uveitis manifests as a cellular reaction in the vitreous cavity or the presence of snowballs.

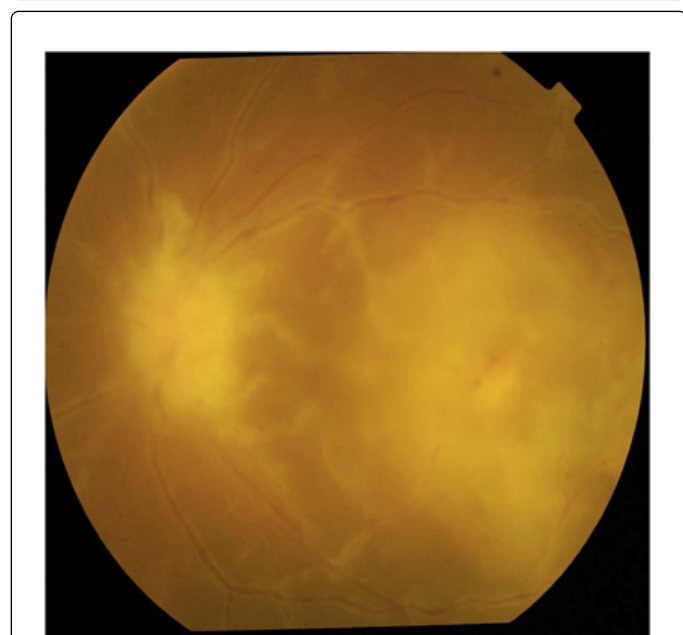
Posterior uveitis is the commonest presentation of ocular TB. It may present as choroidal tubercles, choroiditis, tubercular granulomas, retinal vasculitis and subretinal abscess. Optic nerve involvement may also be found.

Choroidal tubercles are small nodule like yellowish sub-retinal mass lesions seen on the posterior pole (Figure 1). The choroidal tubercles

are similar to the tubercles elsewhere in the body and show mononuclear infiltrates, granuloma (Figure 2) with caseation necrosis that may contain acid-fast bacilli [23-25].



**Figure 1:** Colour fundus photograph of right eye showing a choroidal tuberculoma at the macula (black arrow).

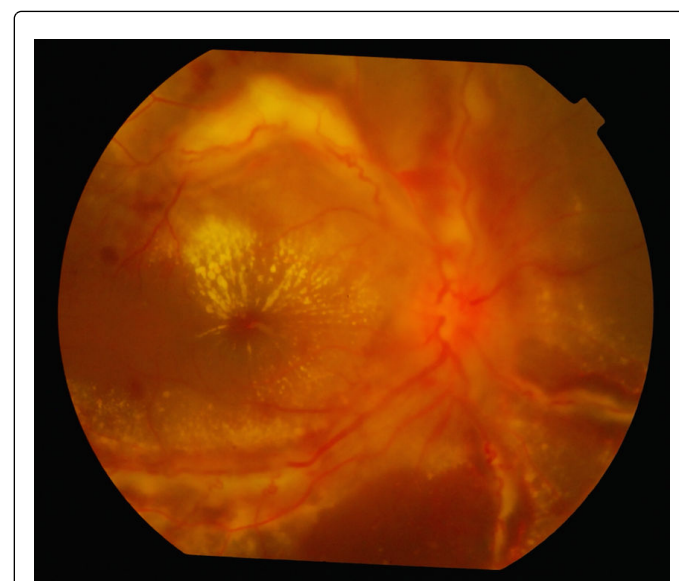

**Figure 2:** Granuloma on the ONH with perivascular sheathing and chorioretinitis patch with retinal hemorrhages in the macula.

Lesions of choroiditis may be solitary, multifocal or serpiginous [26]. Multifocal choroidal lesions are suggestive of hematogenous spread of MTb bacilli from other systemic sites [27,28]. Choroidal involvement may be multifocal to begin with but may show a progressive edge giving a serpiginous-like appearance. Two

morphologic patterns of the serpiginous like choroiditis are seen. The first is a wavelike progression and then confluence of multifocal choroiditis lesions. The second is a diffuse lesion to start with which shows an actively progressing edge with healing in the centre [29]. Serpiginous-like choroiditis may be an important marker for TB even in patients residing in non-endemic regions [30,31]. In contrast to classic serpiginous choroiditis, the lesions in TB-associated serpiginous-like choroiditis are more pigmented, more likely to be multifocal, and often arise outside the peripapillary region [32]. Any choroiditis lesion has the potential to breach the Bruch's membrane and hence must be monitored for the development of choroidal neovascularization [4]. There may be retinal vasculitis with perivascular choroidal lesions.

Retinal vascular inflammation is commonly seen in association with TB [33-35]. Retinal vasculitis mainly involves the veins and is often seen as a severe perivascular cuffing with infiltrates and vitritis (Figure 3). When associated with a focal active or healed chroiditis lesion along the inflamed vessel, a tubercular etiology is very likely to occur [2]. Macular star and optic disc edema may be seen, complicating tuberculous retinal vasculitis [33]. Tubercular retinal vasculitis often causes extensive peripheral retinal ischemia resulting in retinal neovascularisation. Retinitis usually occurs concomitantly with choroiditis causing a retinochoroiditis [2].



**Figure 3:** Colour fundus photograph of the right eye showing hyperemic disc with extensive vasculitis, retinal hemorrhages and hard exudates with macular star formation.

Subretinal abscess seen in a TB endemic area should raise a strong suspicion of ocular TB associated uveitis. Yellowish subretinal abscesses may occur from liquefaction necrosis within a tubercular granuloma. Overlying vitritis and retinal hemorrhages are often found associated with the abscess [2]. In severe cases, a subretinal abscess may rupture into the vitreous and result in endophthalmitis or panophthalmitis [36,37]. Panophthalmitis with scleral involvement may occur leading to globe rupture or scleral calcification in advanced cases [4,38].

Neuroretinitis is characteristically seen to develop secondary to a peripapillary infection [2]. Optic neuropathy may also occur due to a

hypersensitivity response to the tubercular antigen [4]. The various manifestations of involvement of the optic nerve may be papillitis, papilledema, optic neuritis, retrobulbar neuritis and optic nerve tubercles [39-41].

Tubercular uveitis may get complicated with the development of cystoid macular edema, cataract, glaucoma, epiretinal membrane, neovascularization, retinal detachment and vitreous hemorrhage [42].

In immunocompromised patients, ocular TB is more common and more severe. Extensive choroidal infiltrates and nodules, intense vitritis, endophthalmitis, and bilateral optic neuritis have been reported [43,44].

Fundus autofluorescence and fluorescein angiography may help in differentiating between active and healed lesions of tubercular uveitis [2,37]. Optical coherence tomography may help detect and quantify macular edema which may be clinically difficult to appreciate in the presence of severe intraocular inflammation [45].

## Diagnosis

Identification of MTb on the Lowenstein-Jensen media is the gold standard test for the diagnosis of TB [3,46]. However it may not be always possible to have a sample from ocular tissues for subjecting it to microbiological sampling and rarely one may find acid fast bacilli or grow MTb in ocular tissue samples. The various ocular samples which may be collected are choroidal biopsy, vitreous biopsy and aqueous sample. The overall yield of the ocular samples remains low as ocular tuberculosis is often a paucibacillary disease [47].

Vitreous samples have a better yield than aqueous samples. Undiluted vitreous samples improve the yield; however, we need to weigh the risks of collecting the sample with the infusion line switched off. The preparation of vitreous samples for cyto-pathological analysis has also changed over time to improve yields from this limited specimen. Intzedy et al. reported that samples placed in saline or prepared fresh followed by paraffin embedding were able to yield a positive diagnosis [48].

There is no single test available to confirm the diagnosis of tuberculosis and a diagnosis of presumed ocular tuberculosis can thus be made [49] by correlating the clinical signs and symptoms with corroborative evidence got on various tests such as skin hypersensitivity reactions-Mantoux test and Interferon gamma release assay (IGRA) which is considered more sensitive and specific than Mantoux test in the diagnosis of tubercular uveitis. IGRA is considered as a better first line test for the diagnosis of tubercular uveitis as it is not affected by the age of the patient or intake of steroids and is preferred in patients who have been vaccinated with Bacillus Calmette Guerin (BCG) vaccine because of the lack of cross reactivity. Combination of positivity of mantoux test and IGRA is highly suggestive of tubercular uveitis [50].

Diagnosis of pulmonary tuberculosis may be based on contrast enhanced computed tomography (CECT) of thorax which is said to be more sensitive than chest X-ray [51], positive smear for acid-fast bacillus in sputum sample, endobronchial lavage. The specimen obtained through endobronchial ultrasound (EBUS) or endoscopic ultrasound (EUS) may be subjected to microbiological and histopathological evaluation to confirm MTb. Ocular tissue biopsy of choroidal tubercles or choroidal granuloma may show necrotizing granulomas on histopathological examination suggestive of tubercular infection. Ocular samples may be subjected to polymerase chain

reaction (PCR) which is a molecular technique for evaluation of very small amounts of deoxyribonucleic acid (DNA) and ribonucleic acid (RNA) by enzymatic amplification of nucleic acid sequences [52]. PCR is immensely useful in detecting ocular tuberculosis and confirming the diagnosis very early in the course of the disease [29,33,53-55]. A clinicopathological study revealed the presence and quantified the number of copies of MTb in the retinal pigment epithelium (RPE) of an eye with granulomatous panuveitis [21]. Gene expert PCR helps in the diagnosis of rifampicin resistance [56].

Imaging is useful to document the disease and also for follow-up of the disease process and to better understand the progression and sequelae of the disease. Serial fundus photographs help in studying the resolution of lesions as well as documenting appearance of new lesions. Fundus fluorescein angiography (FFA) helps in studying the disease activity in choroiditis, retinal vasculitis, disc edema and also document cystoid macular edema which may develop as a complication of the inflammatory process. Indocyanine green angiography (ICGA) is most useful for studying choroidal pathologies. The choroiditis lesions are hypofluorescent on ICGA indicating permanent occlusion of the choriocapillaris. ICGA may also detect the CNVM or retinal angiomatous proliferation (RAP) that frequently develops in active tubercular granulomas [57].

Fundus autofluorescence (FAF) helps distinguish active from inactive lesions. A hypo-autofluorescent lesion with a hyper-autofluorescent edge is suggestive of disease activity [58].

Tubercular granulomas of the choroid are visible on enhanced depth imaging optical coherence tomography (EDI-OCT) as hyporeflective or isoreflective areas of increased homogeneity within the choroid [59]. EDI-OCT may also help in differentiating lesions of granulomatous uveitis. Tubercular lesions are usually lobulated in shape and less homogeneous in internal pattern as compared to sarcoidosis and Vogt-Koyanagi-Harada syndrome. Also, EDI-OCT has been reported to be more sensitive than ICGA in early decrease in granuloma size in response to treatment, thus is useful for follow-up of patients [60,61].

OCT angiography (OCT-A) is a relatively newer modality and there is limited evidence on OCT-A features of tubercular lesions. It may be useful in demonstrating choriocapillaries hypoperfusion seen as areas of flow void and tubercular retinal vasculitis seen as areas of non-perfusion [62,63].

## Treatment

Treatment of ocular tuberculosis is on the lines of management of systemic tuberculosis. The exact duration of treatment and the end point of treatment are difficult to determine and are more often decided based on the resolution of clinical and radiological signs. Patients may receive multidrug anti-tubercular therapy for a time period ranging from six to eighteen months depending upon the severity of the disease and the response of the disease to treatment [64].

As first line therapy a four drug regimen is used including isoniazid, rifampin, pyrazinamide and ethambutol. Pyrazinamide and ethambutol are stopped after two to three months, and treatment is continued for a total duration of six to eighteen months with isoniazid and rifampin. Response to treatment is evident within three to four weeks. Usually the ocular and systemic response follow a parallel path however at times this may not be seen and it could possibly be due to poor penetration of the systemic drugs in the eye [65]. A poor



response may also be secondary to multidrug resistance requiring a second line of drugs.

The drugs used in the management of multi-drug resistant (MDR) TB and extensively-drug resistant (XDR) TB drug categories which are required for its management include fluoroquinolones, capreomycin, kanamycin, amikacin, thioamides, cycloserine, aminosalicyclic acid, clofazimine, amoxicillin with clavulunate, linezolid, carbapenems, thioacetazone and clarithromycin [66].

Steroids help in limiting the damage to the ocular tissues resulting from inflammatory insult and also help in preventing a delayed hypersensitivity response to the tubercular antigen [4]. Paradoxical worsening (Jarisch-Herxheimer reaction) after initiation of ATT has been reported [66-70]. This phenomenon is thought to result from release of mycobacterial antigens after ATT, strengthening of host immune response, and decrease in immunosuppression mechanisms [71]. The other possible cause for worsening of ocular disease could be an inadequate immunosuppression with corticosteroid therapy after starting ATT requiring an increase in dose of corticosteroids or addition of immunosuppressive drugs.

Additionally, the role of rifampicin in reducing the bioavailability of corticosteroids also needs to be considered. Rifampicin has been shown to increase the plasma clearance of prednisolone by 45% and reduce drug bioavailability in tissues by 66% [72]. This may lead to undertreating the inflammatory component of the disease which in turn may lead to progressive inflammation. Noncompliance may also be a cause of treatment failure.

Retinal hypoxia is said to occur very early in ocular tuberculosis and may lead to early neovascularization requiring anti-VEGF injections

Retinal laser photocoagulation may be required in cases where neovascularization develops [2]. Pars plana vitrectomy may be required in a case which develops endophthalmitis and full thickness eye wall resection along with vitrectomy may be required for tuberculomas [73,74]. Elective surgeries such as cataract surgery should be deferred till the intense inflammation subsides.

## Conclusion

There is a resurgence of TB and it is no longer limited to the lower socio-economic group and developing countries. MDR-TB is showing an increasing trend. One needs to be aware of the varied manifestations of tubercular uveitis as no single test is confirmatory of the diagnosis of ocular TB. Diagnosis is mainly based on correlating clinical signs and symptoms with the results of various investigations. Regular monitoring of response to ATT, adequate control of inflammation with corticosteroids and immunosuppressive is vital to avoid damage to the ocular tissues due to the inflammation secondary to TB. One has to remember the occurrence of early neovascular complications secondary to retinal hypoxia. Tubercular uveitis requires a multidisciplinary approach including an ophthalmologist, a pulmonologist, internist, microbiologist and a pathologist, for the timely diagnosis and management of the patient in order to avoid blinding complications.

## References

- Jones RM, Brosseau LM (2015) Aerosol transmission of infectious disease. *J Occup Environ Med* 57: 501-508.
- Gupta V, Gupta A, Rao NA (2007) Intraocular tuberculosis--an update. *Surv Ophthalmol* 52: 561-587.
- Centers for Disease Control and Prevention, Gangadharan D, Smith J, Weyant R (2013) Biosafety Recommendations for Work with Influenza Viruses Containing a Hemagglutinin from the A/goose/Guangdong/1/96 Lineage. *MMWR Recomm Rep* 62: 1-7.
- Sharma A, Thapa B, Lavaju P (2011) Ocular tuberculosis: an update. *Nepal J Ophthalmol* 3: 52-67.
- [No authors listed] (2010) Global tuberculosis control: key findings from the December 2009 WHO report. *Wkly Epidemiol Rec* 85: 69-80.
- Blumberg HM, Migliori GB, Ponomarenko O, Haldal E (2010) Tuberculosis on the move. *Lancet* 375: 2127-2129.
- Gandhi NR, Nunn P, Dheda K, Schaaf HS, Zignol M, et al. (2010) Multidrug-resistant and extensively drug-resistant tuberculosis: a threat to global control of tuberculosis. *Lancet* 375: 1830-1843.
- Hawker JI, Bakshi S, Ali S, Farrington CP (1999) Ecological analysis of ethnic differences in relation between tuberculosis and poverty. *BMJ* 319: 1031-1034.
- Henderly DE, Genstler AJ, Smith RE, Rao NA (1987) Changing patterns of uveitis. *Am J Ophthalmol* 103: 131-136.
- Abrahams IW, Jiang YQ (1986) Ophthalmology in China. Endogenous uveitis in a Chinese ophthalmological clinic. *Arch Ophthalmol* 104: 444-446.
- Mercanti A, Parolini B, Bonora A, Lequaglie Q, Tomazzoli L (2001) Epidemiology of endogenous uveitis in north-eastern Italy. Analysis of 655 new cases. *Acta Ophthalmol Scand* 79: 64-68.
- Wakabayashi T, Morimura Y, Miyamoto Y, Okada AA (2003) Changing patterns of intraocular inflammatory disease in Japan. *Ocul Immunol Inflamm* 11: 277-286.
- Singh R, Gupta V, Gupta A (2004) Pattern of uveitis in a referral eye clinic in north India. *Indian J Ophthalmol* 52: 121-125.
- Al-Mezaine HS, Kangave D, Abu El-Asrar AM (2010) Patterns of uveitis in patients admitted to a University Hospital in Riyadh, Saudi Arabia. *Ocul Immunol Inflamm* 18: 424-431.
- Al-Shakarchi FI (2014) Pattern of uveitis at a referral center in Iraq. *Middle East Afr J Ophthalmol* 21: 291-295.
- Nickla DL, Wallman J (2010) The multifunctional choroid. *Prog Retin Eye Res* 29: 144-168.
- Alvarez S, McCabe WR (1984) Extrapulmonary tuberculosis revisited: a review of experience at Boston City and other hospitals. *Medicine* 63: 25-55.
- Kurup SK, Chan CC (2006) Mycobacterium-related ocular inflammatory disease: diagnosis and management. *Ann Acad Med Singapore* 35: 203-209.
- Tabbara KF (2005) Ocular tuberculosis: anterior segment. *Int Ophthalmol Clin* 45: 57-69.
- Basu S, Wakefield D, Biswas J, Rao NA (2015) Pathogenesis and pathology of intraocular tuberculosis. *Ocu Immunol and Inflamm* 23: 353-357.
- Rao NA, Saraswathy S, Smith RE (2006) Tuberculous uveitis: distribution of Mycobacterium tuberculosis in the retinal pigment epithelium. *Arch Ophthalmol* 124: 1777-1779
- Nazari H, Karakousis PC2, Rao NA1 (2014) Replication of Mycobacterium tuberculosis in retinal pigment epithelium. *JAMA Ophthalmol* 132: 724-729.
- Croxatto JO, Mestre C, Puente S, Gonzalez G (1986) Nonreactive tuberculosis in a patient with acquired immune deficiency syndrome. *Am J Ophthalmol* 102: 659-660.
- Barondes MJ, Sponsel WE, Stevens TS, Plotnik RD (1991) Tuberculous choroiditis diagnosed by chorioretinal endobiopsy. *Am J Ophthalmol* 112: 460-461.
- Biswas J, Madhavan HN, Gopal L, Badrinath SS (1995) Intraocular tuberculosis. Clinicopathologic study of five cases. *Retina* 15: 461-468.
- Akal A, Goncu T, Boyaci F, Sak Z, Yalcin F, et al. (2014) Primary tubercular chorioretinitis. *Ann Med Health Sci Res* 4: 965-967.
- Massaro D, Katz S, Sachs M (1964) Choroidal Tubercles. A Clue to Hematogenous Tuberculosis. *Ann Intern Med* 60: 231-241.

28. Tooke F (1936) Tuberculosis Of The Choroid Associated With Generalized Miliary Tuberculosis. *Br J Ophthalmol* 20: 23-32.
29. Gupta V, Gupta A, Arora S, Bambery P, Dogra MR, Agarwal A (2003) Presumed tubercular serpiginous like choroiditis: clinical presentation and management. *Ophthalmology* 110: 1744-1749.
30. Gan WL, Jones NP (2013) Serpiginous-like choroiditis as a marker for tuberculosis in a non-endemic area. *Br J Ophthalmol* 97: 644-647.
31. Cunningham ET, Gupta A, Zierhut M (2014) The creeping choroiditis - serpiginous and multifocal serpiginoid choroiditis. *Ocul Immunol Inflamm* 22: 345-348.
32. Bansal R, Gupta A, Gupta V, Dogra MR, Sharma A, Bambery P (2012) Tubercular serpiginous-like choroiditis presenting as multifocal serpiginoid choroiditis. *Ophthalmology* 119: 2334-2342.
33. Gupta A, Gupta V, Arora S, Dogra MR, Bambery P (2001) PCR-positive tubercular retinal vasculitis: clinical characteristics and management. *Retina* 21: 435-444.
34. Hoh HB, Kong VY, Jaais F (1998) Tuberculous retinal vasculitis. *Med J Malaysia* 53: 288-289.
35. Reny JL, Challe G, Geisert P, Aerts J, Ziza JM, et al. (1996) Tuberculosis-related retinal vasculitis in an immunocompetent patient. *Clin Infect Dis* 22: 873-874.
36. Gupta A, Bansal R, Gupta V, Sharma A, Bambery P (2010) Ocular signs predictive of tubercular uveitis. *Am J Ophthalmol* 149: 562-570.
37. Gupta A, Gupta V (2005) Tubercular posterior uveitis. *Int Ophthalmol Clin* 45: 71-88.
38. Raina UK, Tuli D, Arora R, Mehta DK, Taneja M (2000) Tubercular endophthalmitis simulating retinoblastoma. *Am J Ophthalmol* 130: 843-845.
39. Madhavan HN, Therese KL, Gunisha P, Jayanthi U, Biswas J (2000) Polymerase chain reaction for detection of Mycobacterium tuberculosis in epiretinal membrane in Eales' disease. *Invest Ophthalmol Vis Sci* 41: 822.
40. Minton J (1956) Ocular manifestations of tuberculosis meningitis: a pictorial survey. *Trans Ophthalm Soc* 76: 561-579.
41. Mansour AM (1998) Optic disk tubercle. *J Neuroophthalmol* 18: 201-203.
42. Parchand S, Tandan M, Gupta V, Gupta A (2011) Intermediate uveitis in Indian population. *J Ophthalmic Inflamm Infect* 1: 65-70.
43. Blodi BA, Johnson MW, McLeish WM, Gass JD (1989) Presumed choroidal tuberculosis in a human immunodeficiency virus infected host. *Am J Ophthalmol* 108: 605-607.
44. Jaafar J, Hitam WH, Noor RA (2012) Bilateral atypical optic neuritis associated with tuberculosis in an immunocompromised patient. *Asian Pac J Trop Biomed* 2: 586-588.
45. Al-Mezaine HS, Al-Muammar A, Kangave D, Abu El-Asrar AM (2008) Clinical and optical coherence tomographic findings and outcome treatment in patients with presumed tuberculous uveitis. *Int Ophthalmol* 28: 413-423.
46. Jagirdar J, Zagzag D (2004) Pathology and insights into pathogenesis of tuberculosis. In: Rom WN, Garay SM, eds. *Tuberculosis* (2nd edn) Philadelphia, PA: Lippincott Williams & Wilkins 323-344.
47. Mehta S (2016) Observed Patterns of Systemic Disease on PET/CT Scan in Patients with Presumed Ocular Tuberculosis: Findings and Hypotheses. *Ocul Immunol Inflamm* 22: 1-3.
48. Intzedy L, Teoh SC, Hogan A, Mangwana S, Mayer EJ, et al. (2008) Cytopathological analysis of vitreous in intraocular lymphoma. *Eye (Lond)* 22: 289-293.
49. Gupta A, Sharma A, Bansal R, Sharma K (2015) Classification of intraocular tuberculosis. *Ocul Immunol Inflamm* 23: 7-13.
50. Ang M, Wong W, Ngan CC, Chee SP (2012) Interferon-gamma release assay as a diagnostic test for tuberculosis-associated uveitis. *Eye* 26: 658-665.
51. Skoura E, Zumla A, Bomanji J (2015) Imaging in tuberculosis. *Int J Infect Dis* 32: 87-93.
52. Chan CC, Shen D, Tuo J (2005) Polymerase chain reaction in the diagnosis of uveitis. *Int Ophthalmol Clin* 45: 41-55.
53. Kotake S, Kimura K, Yoshikawa K, Sasamoto Y, Matsuda A, et al. (1994) Polymerase chain reaction for detection of Mycobacterium tuberculosis in ocular tuberculosis [letter]. *Am J Ophthalmol* 117: 805-806.
54. Biswas J, Therese L, Madhwan HN (1999) Use of polymerase chain reaction in detection of Mycobacterium tuberculosis complex DNA from vitreous sample of Eales' disease. *Br J Ophthalmol* 83: 994.
55. Madhavan HN, Therese KL, Gunisha P, Jayanthi U, Biswas J (2000) Polymerase chain reaction for detection of Mycobacterium tuberculosis in epiretinal membrane in Eales' disease. *Invest Ophthalmol Vis Sci* 41: 822.
56. Sharma K, Gupta V, Sharma A, Singh R, Sharma M, et al. (2017) Gene Xpert MTB/RIF assay for the diagnosis of intra-ocular tuberculosis from vitreous fluid samples. *Tuberculosis* 102: 1-2.
57. Bansal R, Basu S, Gupta A, Rao N, Invernizzi A, et al. (2017) Imaging in tuberculosis-associated uveitis. *Indian J Ophthalmol* 65: 264-270.
58. Gupta A, Bansal R, Gupta V, Sharma A (2012) Fundus autofluorescence in serpiginouslike choroiditis. *Retina* 32: 814-825.
59. Rostaqui O, Querques G, Haymann P, Fardeau C, Coscas G, Souied EH (2014) Visualization of sarcoid choroidal granuloma by enhanced depth imaging optical coherence tomography. *Ocul Immunol Inflamm* 22: 239-241.
60. Rifkin LM, Munk MR, Baddar D, Goldstein DA (2015) A new OCT finding in tuberculous serpiginous-like choroidopathy. *Ocul Immunol Inflamm* 23: 53-58.
61. Invernizzi A, Agarwal A, Mapelli C, Nguyen QD, Staurengi G, et al. (2017) Longitudinal follow-up of choroidal granulomas using enhanced depth imaging optical coherence tomography. *Retina* 37: 144-153.
62. Agarwal A, Mahajan S, Khairallah M, Mahendradas P, Gupta A, et al. (2017) Multimodal Imaging in Ocular Tuberculosis. *Ocul Immunol Inflamm* 25: 134-145.
63. Ferrara D, Waheed NK, Duker JS (2016) Investigating the choriocapillaris and choroidal vasculature with new optical coherence tomography technologies. *Prog Retin Eye Res* 52: 130-155.
64. Patterson PE, Kimerling ME, Bailey WC (1999) Chemotherapy of tuberculosis. In: Schlossberg D (eds). *Tuberculosis and Nontuberculous Mycobacterial Infections*, (4th edn), W. B. Saunders, Philadelphia, pp: 71-82.
65. Agarwal M, Jha V, Biswas J (2014) Rapidly blinding posterior tubercular uveitis. *J Ophthalmic Inflamm Infect* 4: 13.
66. Caminero JA, Sotgiu G, Zumla A, Migliori GB (2010) Best drug treatment for multidrug-resistant and extensively drug-resistant tuberculosis. *Lancet Infect Dis* 10: 621-629.
67. Gupta V, Bansal R, Gupta A (2011) Continued progression of tubercular serpiginous-like choroiditis after initiating antituberculosis treatment. *Am J Ophthalmol* 152: 857-863.
68. Rathinam SR, Lalitha P (2007) Paradoxical worsening of ocular tuberculosis in HIV patients after anti-retroviral therapy. *Eye* 21: 667-668.
69. Cheung CM, Chee SP (2009) Jarisch-Herxheimer reaction: paradoxical worsening of tuberculosis chorioretinitis following initiation of antituberculous therapy. *Eye* 23: 1472-1473.
70. Basu S, Das T (2010) Pitfalls in the management of TB-associated uveitis. *Eye (Lond)* 24: 1681-1684.
71. Afghani B, Lieberman JM (1994) Paradoxical enlargement or development of intracranial tuberculomas during therapy: case report and review. *Clin Infect Dis* 19: 1092-1099.
72. McAllister WA, Thompson PJ, Al-Habet SM, Rogers HJ (1983) Rifampicin reduces effectiveness and bioavailability of prednisolone. *Br Med J (Clin Res Ed)* 286: 923-925.
73. Hase K, Namba K, Saito W, Ohno S, Ishida S (2015) A case of tuberculous endophthalmitis successfully treated with vitrectomy followed by antituberculous agents. *J Ophthalmic Inflamm Infect* 8: 14.
74. Gopal L, Rao SK, Biswas J, Madhavan HN, Agarwal S (2003) Tuberculous granuloma managed by full thickness eye wall resection. *Am J Ophthalmol* 135: 93-94.