

An Ominous Anterior T Wave Changes: A Case Report on Wellens' Syndrome

Dayaratna J¹, Nisahan B, Guruparan M and Peranantharajah T

¹Jaffna Teaching Hospital, Jaffna, Sri Lanka

*Corresponding author: Dayaratna J, Registrar in Medicine, Jaffna Teaching Hospital, Jaffna, Sri Lanka, Tel: 94718663548; E-mail: jagathdayaratna@yahoo.com

Received date: November 12, 2017; Accepted date: November 16, 2017; Published date: November 22, 2017

Copyright: © 2017 Dayaratna J, et al. This is an open-access article distributed under the terms of the Creative Commons Attribution License, which permits unrestricted use, distribution, and reproduction in any medium, provided the original author and source are credited.

Abstract

Coronary heart disease (CHD) is one of the main causes for mortality and morbidity in both developed and developing countries throughout the world. CHD had claimed nearly 7.4 million deaths worldwide according to WHO in 2015.

Wellen's syndrome is now being increasingly recognized as a distinct entity causing acute coronary syndrome. The syndrome is due to critical narrowing of proximal left anterior descending (LAD) coronary artery.

Identification of this syndrome is paramount important because this is a preinfarction stage of CHD that often progresses to a devastating anterior myocardial infarction within a mean time of 8.5 days.

We report a 62 year old recently diagnosed, well controlled diabetic gentleman who presented with ischemic type of chest pain with normal ECG and normal cardiac biomarkers on admission, found to have Wellen's syndrome. He was managed successfully with urgent percutaneous coronary intervention (PCI).

Keywords: Wellens' syndrome; Critical LAD narrowing; Acute coronary syndrome; Chest pain

Introduction

Wellens' syndrome an entity of acute coronary syndrome due to critical lesion in the left anterior descending (LAD) is increasingly recognized [1]. The main dilemma in diagnosing it is due to its atypical presentation with normal cardiac biomarkers and minimal ECG changes.

Early diagnosis and prompt PCI is paramount in preventing serious mortality and morbidity due development of acute anterior myocardial infarction within first two weeks of presentation [2].

Case History

A 62 year old gentleman who was diagnosed with type 2 diabetes mellitus for two months duration with good control had presented with typical ischemic type of chest pain for 30 minute duration. The tightening type chest pain was at its maximum at onset and gradually subsided over 30 minutes.

On admission he was hemodynamically stable and the electrocardiograph (ECG) was normal without any ST or T wave changes. He was monitored at coronary care high dependency unit as he had strong family history of sudden cardiac death.

Troponin I titer was negative on admission, while full blood count, renal function tests, liver function tests and serum electrolytes were within the normal reference ranges. 2D echocardiogram was normal without any regional wall motion abnormalities.

Serial ECGs performed and after 6 hours of admission found to have biphasic anterior T wave inversions which was suggestive of Wellens' syndrome (Figure 1).

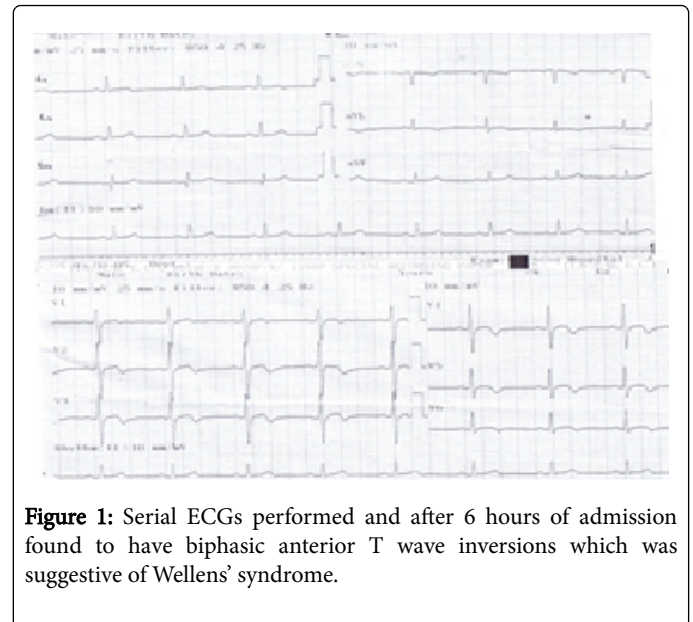


Figure 1: Serial ECGs performed and after 6 hours of admission found to have biphasic anterior T wave inversions which was suggestive of Wellens' syndrome.

Repeated troponin I titer was positive at a level of 2 ng/mL. Urgent coronary artery angiogram was performed which revealed critical LAD narrowing (Figure 2). Drug eluting stent was introduced which obtained Thrombolysis in Myocardial Infarction (TIMI) 3 flow without any post procedure complications.

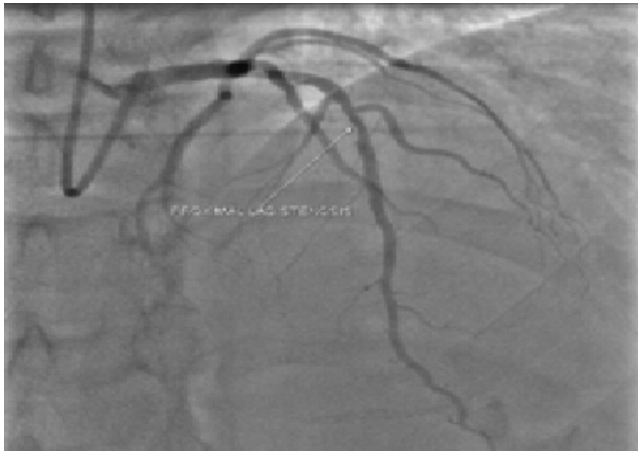

Figure 2: Coronary artery angiogram.

Discussion

Wellens' syndrome or acute anterior ischemia due to critical LAD lesion is well known phenomenon. It should be considered as probable causes with a typical ischemic chest pain or atypical chest pain. It's paramount to continuously monitor the patient with serial ECGs which will manifest as T wave inversions (type 1 Wellens' syndrome)

or biphasic T waves (type 2 Wellens' syndrome) in the anterior territory [3]. The T wave changes could also develop during pain free period following initial chest pain.

Cardiac markers such as troponin I may be positive or negative initially. Obtaining of a comprehensive history including family history for CAD and sudden cardiac death is vital in identification of possible ACS. Coronary artery angiogram is the diagnostic test of choice which will reveal critical LAD narrowing. Failing to recognize this syndrome results in acute anterior myocardial infarction and its complications within two weeks.

We recommend frequent ECG monitoring for patients with chest pain who have strong family history of CAD or sudden cardiac death at least for 24 hours. It will help to identify the rare syndrome like Wellens' in a poor resource setting to avoid devastating complications of CAD.

References

1. WHO Cardiovascular diseases (CVDs), Fact sheet Updated May 2017.
2. Chris ZD, Bar FW, Wellens HJ (1982) Characteristic electrocardiographic pattern indicating a critical stenosis high in left anterior descending coronary artery in patients admitted because of impending myocardial infarction. *Am Heart J* 103: 730-736.
3. Hanna EB, Glancy DL (2011) ST-segment depression and T-wave inversion: Classification, differential diagnosis and caveats. *Cleve Clin J Med* 78: 404-414.