

Agensis of Palmaris Longus Muscle among Selected Ethiopian Students

Tesfamichael Berhe¹ and Assegedech Bekele²

¹Lecturer of Anatomy, College of Health Sciences, Mekelle University, P.O. Box 1871, Ethiopia

²Associate Professor of Anatomy, Gondar college of Medicine and Health Sciences, University of Gondar, P.O. Box 196, Ethiopia

Abstract

Background: Palmaris longus muscle has received a growing interest for its role in constructive surgery. Since the agensis of Palmaris longus shows a strong racial variation, it is important to investigate its distribution on the Ethiopian students and compare the results with others.

Methods : a cross sectional descriptive study was conducted in 712 subjects comprising of 504 males and 208 females to assess the distribution of Palmaris longus in the freshman students of Gondar College of Medicine and Health Sciences ,University of Gondar, Ethiopia in 2010.

Results: The overall prevalence of absence both unilaterally and bilaterally in the two sexes was 15.3%. The bilateral absence was 8.1%. Unilateral absence was 7.2%. The distribution of unilateral absence on the right and left were 3.5% and 3.7% respectively. In 9 subjects the tendon of Palmaris longus was found duplicated unilaterally. In other ten individuals an overlapping and laterally deviating tendon of Palmaris longus muscle towards the tendon of flexor carpiradialis muscle were observed.

Conclusion: Results of this finding suggested that the prevalence of Palmaris longus agensis is similar as reported in standard anatomy texts but considerably differ from findings obtained from studies that are conducted in other black African populations.

Keywords: Palmaris longus muscle; Agensis; Race; Gender; Peculiar variation

Introduction

Background

Anatomical variations are common and should be expected to encounter them during dissection, physical examination, diagnosis and treatment. Palmaris longus muscle (PLM) is a slender fusiform muscle, whose short muscle belly arises from the medial epicondyle of humerus with a common flexor origin and its long tendon passes palmar to the transverse carpal ligament and is attached to the palmar aponeurosis. PLM tendon is located between the tendons of flexor carpiradialis (laterally) and flexor carpiulnaris (medially) at the distal middle ventral surface of forearm. It is innervated with a branch of median nerve and its function (when present) is to tense the palmar aponeurosis and to weakly flex the wrist joint synergized by flexor carpi radialis (FCR), flexor carpi ulnaris (FCU) and flexor digitorum superficialis (FDS) muscles [1]. Palmaris longus muscle, although of little functional use to the human upper limb, assumes great importance when used as donor tendon for transfer [2].

Palmaris longus is one of the most variable muscles of the human body. Some of its variations include (i) frequently absent on one or both sides (ii) division of the terminal tendon in to 2 or 3 separate tendons (iii) Muscle belly may be central, distal or digastric (proximal and distal muscle belly connected by a central tendon) in position. (iv) It may be completely muscular from origin to insertion or only a fibrous strand. (v) Either the muscle belly or tendon may be bifid or both. (vi) deviation of the tendon to be inserted to the pisiform bone or abductor pollicis brevis muscle [3].

The distribution of the palmaris longus agensis and other aspects of variations of the muscle are studied in different ethnic groups and populations of the world. But, the magnitude of absence or presence of the muscle in the population of Ethiopia and most other African populations is not well investigated.

The aim of this study was to determine the incidence of unilateral

and bilateral absence and variations of Palmaris longus for the selected group of students in CMHS, Gondar, Ethiopia in 2010.

Literature review

In vertebrates, PLM is found only in mammals and is best developed where the forelimb is used for ambulation. For example, the Palmaris longus is always present in the orangutan but is variably absent in higher primates such as chimpanzees and gorillas [4]. The prevalence of absence of the Palmaris longus has been extensively studied following the first report of its absence in 1559 [5]. The muscle is often absent on one or both sides and is much subject to variation [6]. Riemann et al. [7] found the muscle absent in 281 of 2205 specimens (12.5 %). Thompson et al. [8] found the muscle missing in about 16% of males and 24% of females, these figures being based on studies of cadavers [8].

Much has been reported about the variations in palmaris longus muscle in relation to its morphology, origin, insertion, nerve supply and presence or absence in different individuals. The first three-headed reversed palmaris longus muscle was recorded by Yildiz et al. [9] in a 36 year old woman. Oommen [10] has also recorded inverse (up-down) palmaris longus muscle in a cadaver, in which the muscle originates by a long thin tendon from the medial epicondyle by the common flexor tendon and from the ante-brachial fascia in both limbs. An atypical innervation was again recorded [11].

***Corresponding author:** Tesfamichael Berhe, Lecturer of Anatomy, College of Health Sciences, Mekelle University, P.O. Box 1871, Ethiopia, Tel: 251344416690; E-mail: tesfish316@gmail.com

Received December 25, 2013; **Accepted** February 08, 2014; **Published** February 10, 2014

Citation: Berhe T, Bekele A (2014) Agensis of Palmaris Longus Muscle among Selected Ethiopian Students. *Anat Physiol* 4: 136. doi:[10.4172/2161-0940.1000136](https://doi.org/10.4172/2161-0940.1000136)

Copyright: © 2014 Berhe T, et al. This is an open-access article distributed under the terms of the Creative Commons Attribution License, which permits unrestricted use, distribution, and reproduction in any medium, provided the original author and source are credited.

Palmaris longus is considered to be a dispensable tendon because its absence does not significantly affect the function of the wrist. It is therefore very useful in orthopedic, hand and reconstructive surgery. It is commonly used by hand surgeons for tendon transfers, second stage tendon reconstruction, pulley reconstruction as well as tendon grafts. Plastic surgeons also utilize the Palmaris longus in restoration of lip and chin defects. Many surgeons agree that the Palmaris longus tendon is the first choice as a donor tendon because it fulfills the necessary requirements of length, diameter and availability, and can be used in reconstructive surgery for a wide variety of procedures including lip augmentation, ptosis correction and in the management of facial paralysis without producing any functional deformity. Moreover, the Palmaris longus tendon is often considered the ideal donor for tendon grafts for replacement of the long flexors of the fingers and of the Flexor Pollicis longus tendon [2,12]. Its relevance in leprosy-affected hands is also documented because the muscle is usually spared in hand palsies consequent to leprotic neural damage [13]. Tendon grafts are frequently required, particularly in reconstructive hand surgery. Plantaris is then often sought as a substitute, and although there is less documentation about its incidence of absence, it appears to be not present in about 7% of cadavers [14].

Ultrasound identification and determination of its length and thickness was found helpful for the pre-operative planning of ligament reconstructive surgery [15].

Methods and Materials

The list of the students was obtained from the registrar of the college. The data was then collected from 712 individuals (1424 upper limbs) by five data collectors and the investigator applying the standard test for observing the tendon of the Palmaris longus muscle.

Individuals with a history of injury, disease or abnormality of the upper limb or upper limbs were excluded from the study.

From the total 504 (70.8%) are males and 208 (29.2%) are females. Each student was asked about to which ethnic group of Ethiopia he or she belongs to. But the majority of the ethnic distribution was found predominantly from one region i.e. 616 Amhara (86.5%), and 96 of them (13.5%) were from the other ethnic groups of Ethiopia such as Oromo 32(4.5%), Tigray 14(2%), and 50 (7%) were from SNNP (Guragie, Sheka, Kenbata, Siltie) and Somalia (table 1).

Each student was provided with a data collection format to fill about the age, sex, body side, hand dominance and ethnicity by him/herself, then he/she was observed and assessed for the presence or absence of the tendon of the muscle on the distal parts of both forearms.

| Age | Frequency= n (%) |
|------------------|------------------|
| 17-20 | 584 (82) |
| 21-24 | 123 (17.3) |
| ≥25 | 5 (0.7) |
| Sex | |
| Male | 504 (70.8) |
| Female | 208 (29.2) |
| Ethnicity | |
| Amhara | 616 (86.5) |
| Oromo | 32 (4.5) |
| Tigray | 14 (2) |
| Other | 50 (7) |

Table 1: Frequency of Socio- demographic characteristics of study subjects.

Whenever confusion rose to differentiate between the tendons of the flexor carpiradialis and Palmaris longus confirmation was performed by palpation.

The examination entailed observation of the volar aspect of the wrist, looking for the Palmaris longus tendon in its usual anatomical position just ulnar to the flexor carpi radialis tendon. The test is demonstrated by asking the subject to make opposition of the thumb and the little finger while flexing the wrist. During this, if the tendon of the muscle was not visualized or palpable 4 additional tests (Figure 1-5) were performed to confirm its absence.




Figure 1: Standard test (Schaeffer's test): The subject is asked to oppose the thumb to the little finger and then flex the wrist.

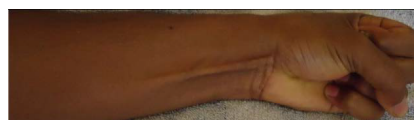

Figure 2: Thompson's test: The subject is asked to make a fist, then flex the wrist and finally the thumb is opposed and flexed over the fingers.

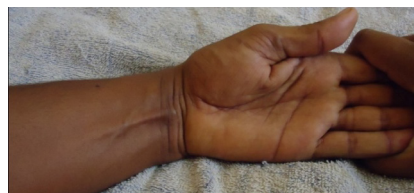

Figure 3: Mishra's test I: The metacarpo-phalangeal joints of all fingers are passively hyperextended by the examiner and the subject is asked to actively flex the wrist.

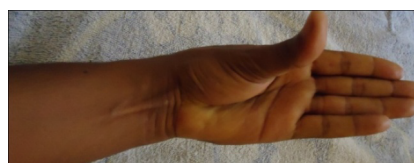


Figure 4: Mishra's test II: The subject is asked to abduct the thumb against resistance with the wrist in slight palmar flexion.

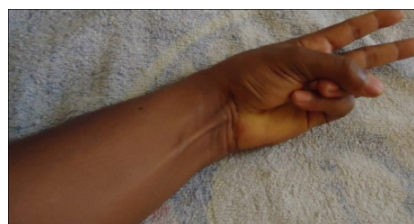


Figure 5: Pushpakumar's "two-finger sign" method: The subject is asked to fully extend the index and middle finger, the wrist and other fingers are flexed and finally the thumb is fully opposed and flexed.

Five data collectors who are physiotherapists (BSc.) were recruited for the process of data collection. They have a very good knowledge of surface anatomy and additional training was provided by the principal investigator for two weeks about the type and uniformity of data collected with demonstration of the techniques to assess for the existence or absence of the muscle on both forearms. Each data collectors again performed the data collection under the close supervision of the principal investigator. A pretest was also conducted to practice and check the applicability of the data collection techniques in 12 colleagues (24 upper limbs).

After data collection was completed, data was checked and cleared for its completeness.

Then data were entered and coded in to SPSS Version 16. After that, descriptive statistical analysis and statistical calculations were performed using this software to yield the results of the study.

The incidence of agenesis of this muscle in both sexes and on the two sides of upper limbs was analyzed using SPSS. Correlation and percentage score were used to assess the association of its agenesis in both sexes unilaterally and bilaterally. The prevalence of absence of the PL (unilateral or bilateral) was presented with a 95% confidence interval. The association between absence of the PL and body side, sex was assessed using chi-square tests. Statistical significance was set at $P < 0.05$

A signed paper of cooperation was obtained from the Department of Anatomy for 13 departments of the college. Study subjects were informed (in groups) about the purpose of the study and the type of the data to be collected and informed verbal consent was obtained from each individual at the time of data collection. The observational data was collected by asking each individual to uncover his/her forearms only to the elbow level and the obtained data was coded and kept confidential.

Whenever confusion arises in identifying the tendon of Palmaris longus muscle from the tendons of the other superficial flexor muscles of the forearm (Flexor carpi radialis, Flexor carpi ulnaris and Flexor digitorum superficialis, FDS), the anatomical relationships of their tendons was confirmed on palpation. Thus, palpation was required and used to confirm the bilateral presence of PLM in 70 (9.8%) individuals, and the unilateral presence of the left one in 5 individuals.

Results

Palmaris longus muscle was found absent in 109 (15.3%) subjects. It was absent bilaterally in 58 (8.1%) individuals and unilaterally absent in 51 (7.2%) subjects. Right Palmaris longus muscle unilateral agenesis and left PLM unilateral agenesis were 3.5 % and 3.7% respectively (Table 2-4, Figure 6).

| | Bilaterally present | Absent | | Total |
|--------|---------------------|------------|------------|-------|
| | | Bilateral | Unilateral | |
| Male | 432 (85.7%) | 37 (7.4%) | 35 (6.9%) | 504 |
| Female | 171 (82.2%) | 21 (10.1%) | 16 (7.7%) | 208 |
| Total | 603 (84.7%) | 58 (8.1%) | 51 (7.2%) | 712 |

Table 2: Distribution of Palmaris longus muscle between genders.

| | Right | Left | Bilaterally |
|------------|-----------|-----------|-------------|
| Male | 17 (3.4%) | 18 (3.6) | 37 (5.2%) |
| Female | 8 (3.8%) | 8 (3.8%) | 21 (10.1%) |
| Both Sexes | 25 (3.5%) | 26 (3.7%) | 58 (8.1%) |

Table 3: The Distribution of Palmaris longus absence on both limbs.

| | Hand Dominance | | Total |
|---------|----------------|------------|-------|
| | Right | Left | |
| Present | 575 (85.3%) | 28 (73.4%) | 603 |
| Absent | 99 (14.9%) | 10 (35.7%) | 109 |
| Total | 674 | 38 | 712 |

Table 4: Correlation of Palmaris longus muscle presence or absence with hand dominance.

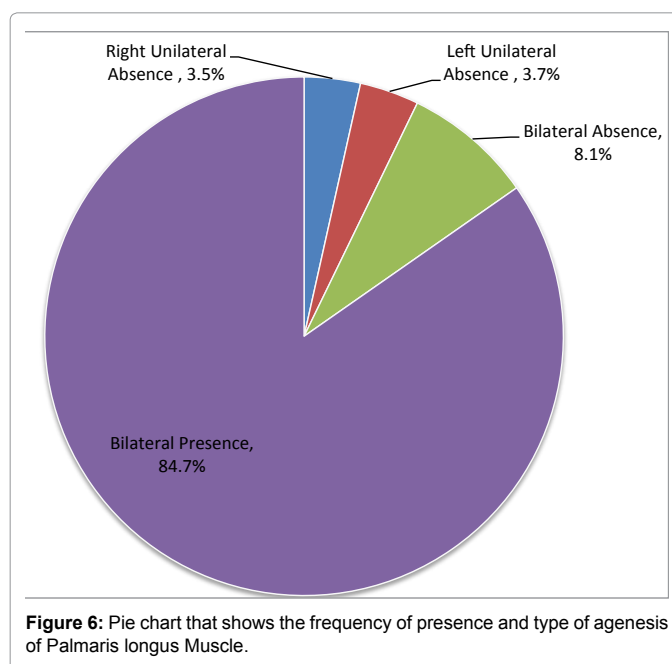


Figure 6: Pie chart that shows the frequency of presence and type of agenesis of Palmaris longus Muscle.

With regard to hand dominance, 38 (5%) of the subjects were left hand dominant and 674 subjects were right handed. The correlation of hand dominance and agenesis of Palmaris longus muscle was assessed in this study. The results show that there was no significant difference with the magnitude of absence in both sides because Palmaris longus was absent in 83 (11.7%) of the right forearms and in 84 (11.8%) left forearms of the study subjects. Hence, these values show that no significant difference exists with absence of Palmaris longus muscle and hand dominance.

The results about the peculiar variations of the muscle in both upper limbs of each individuals was recorded and it shows that bifurcation of the distal part of the tendon at the distal part of the muscle was observed in 6 individuals in the right forearm and in 3 individuals in their left PLM. Laterally deviating and overlapping tendons of PLM with the tendon of flexor carpiradialis muscle was again evident in other 6 individuals 4 in the right and 2 in the left one.

Discussion

The existence of anatomical variations differs among individuals or groups. The distribution of Palmaris longus muscle varies depending on the populations. According to a study by P. Thejodhar et al. [16] there appears to be considerable divisional (racial), ethnic and regional variation in the frequency with which the muscle is absent. The prevalence of absence of the Palmaris longus has been extensively studied following the first report of its absence in 1559 [8,25]. Some of the figures that indicate the distribution of the muscle in different population and races are mentioned in the table 5 [17-24].

| Author(s) | Year of publication | Number of subjects | Number of cases with absent PLM | Percentage (%) | Race/population |
|-----------------------|---------------------|--------------------|---------------------------------|----------------|---------------------------|
| Troha <i>et al</i> , | 1990 | 401 | 98 | 24.4% | North American Caucasians |
| Wehbé MA | 1992 | 120 | 30 | 25% | Pennsylvania |
| Gruber W | 1872 | 350 | 71 | 20.4% | Germans |
| SA Roohi | 2007 | 450 | 60 | 11.3% | Malaysia |
| Sebastin J et al. | 2006 | 329 | 15 | 4.6 | Chinese |
| Kapoor SK, et al | 2008 | 500 | 86 | 17.2%) | Indian |
| Ceyhan O, Mavt A. | 1997 | 7000 | 4473 | 63.8% | Gaziantep |
| Igbigbi & Ssekitoleko | 1996 | 245 | 5 | 2.0% | Ugandan |
| GO Mbaka, | 2002 | 600 | 40 | 6.7% | Nigerian |
| Gangata H | 2009 | 890 | 13 | 1.5% | Zimbabwe |

Table 5: Prevalence of absence (agenesis) of Palmaris Longus Muscle in different populations.

In this study the overall absence of the Palmaris longus was found in 15.3% of the study subjects.

The finding of this study shows strong correlation with the magnitude of absence that is mentioned in Anatomy texts, Indian and Malaysian population but it is lower than the findings in Turkish and other Caucasian populations. However, the prevalence in this study is found higher than the studies in Asian and other African population. This is indicative of strong racial variation of agenesis of the muscle.

There is disagreement in the literature regarding the symmetry of the absence of the muscle and whether absence is more common in women. It is suggested that apart from its ethnic variations, its absence is more common in women, bilateral absence is more common and unilateral absence occurs more frequently on the left side [25]. In this study, the overall bilateral absence (8.1%) was found higher than unilateral absence (7.2%) but it was not statistically significant. Palmaris longus muscle was bilaterally present in 432(85.7%) of the male subjects and in 171 females (82.2%). This shows that the overall prevalence of absence of Palmaris longus in females (17.8%) was higher than in males (14.3%). Females were found to have a higher bilateral absence than males but this was not again statistically significant (10.1%; $p=0.224$, 95%CI, 0.808 to 2.486). It shows similar values for the right side unilateral absence in 25 individuals (3.5%; $p=0.755$, 95% CI, 0.371 to 2.055) and left side unilateral absence in 26 individuals (3.7%; $p=0.859$, 95%CI, 0.396 to 2.164) of the total study subjects.

As mentioned in some studies, some peculiar variations of the Palmaris longus muscle belly and its tendon are observed such as duplication (bifurcation) of the distal part of its tendon, lateral deviation and overlapping of the tendon with the tendon of FCR.

Other cadaveric studies have recorded that reversed three headed Palmaris longus muscle, inverse (up-down) Palmaris longus and atypical innervations of the muscle were found in some cases. A reversed palmaris longus muscle means that the palmaris longus muscle is tendinous in its upper part and muscular in its lower part with the muscle belly triple which can be, characterized as "three-headed reversed palmaris longus muscle". The overuse of the reversed palmaris longus muscle can lead to the muscle's local hypertrophy. A reversed palmaris longus muscle may cause a compartment syndrome with pain and edema in the wrist's area, the carpal tunnel syndrome and Guyon's syndrome. The described variation is also useful to the hand surgeon, as the palmaris longus muscle is an anatomical landmark for operations at this area [26]. Some studies again correlated the absence of the muscle (PLM) with absence of plantaris muscle and other anomalous structures such as absence of flexor digitorum superficialis (FDS) to the little finger and abnormal superficial palmar arch. These associations were not explored in this study. However, a review of literature specifically

addressed this question. All of these studies have statistically analyzed their data and failed to demonstrate any association between the presence (or absence) of the PL with those structural alterations [3].

In this study, two peculiar variations i.e. duplication of the tendon and lateral deviation and overlapping of the tendon with the tendon of FCR were assessed and duplication of the tendon was observed unilaterally in 9(1.3%) individuals and laterally deviated tendon of the PLM was found unilaterally in other 10 (1.4%) individuals.

Five techniques of examining for the presence of the PL in vivo have been described in literature. The most commonly used technique is the standard technique described by Schaeffer [25]. The second method was described by Thompson et al in 1921 [8]. In 2001, Mishra described 2 methods of examining for the PL and in 2003; Pushpakumar et al. described the "two finger" sign method. All tests were used to check for both actions of the PL simultaneously. In some reports it is stated that the standard test and Thompson's test are somewhat difficult for patients to understand and are moderately complex manoeuvres. In this study, the standard test was applied in all subjects, but when the Palmaris longus tendon was absent or not well demonstrated with the standard test, the other 4 tests were applied to confirm the absence or presence of the tendon and the 4 tests were compared with which technique was the tendon best demonstrated when it was present with one or all of the confirmation tests. So, the Pushpakumar's and Mishra's II techniques were better tests than the others and the Pushpakumar's test was easily understood by subjects.

Conclusion and Recommendations

In this study, which included Ethiopian freshman students that come from different ethnic groups of Ethiopia to Gondar College of Medicine and Health Sciences, Palmaris longus muscle is absent unilaterally in 7.2% and bilaterally in 8.1% of the study subjects with an overall absence of 15.3%. Thus, this figure is considerably higher than results of other black African populations.

Bilateral absence is higher than unilateral absence and absence in females occurred more commonly than in males. But the magnitude of unilateral absence in the right and left forearms was similar in this study.

Generally the difference of results and correlation in the type of absence of PLM, hand dominance, gender and body side are not statistically significant.

Among the various techniques mentioned in the literature, the Pushpa Kumar's technique was the easiest to explain to subjects and seems the best way to assess the presence of the PL.

It is believed that the Palmaris longus is the most frequently used

for tendon transfers in hand and reconstructive surgeries, so surgeons are expected to have awareness about the magnitude of presence and absence of the muscle and its peculiar variations to provide effective medical interventions with the muscle.

This study was conducted based on knowledge of surface anatomy by identifying the tendon of the muscle in vivo. Other specific and detailed variations of the muscle can be obtained using other methods (e.g. by dissection of cadavers), so further study is recommended on other types of variations of the muscle and other variable anatomical structures.

References

1. Keith L, Moore (2006) *Clinically Oriented Anatomy*. 5th ed. Lippincott Williams and Wilkins, Philadelphia.
2. Roohi SA, Choon SL, Shalimar A, Tan GH, Naicker AS (2007) A Study on the Absence of Palmaris Longus in a Multiracial Population. *Malaysian Orthopedic Journal* 1: 26-28.
3. Pai MM, Prabhu LV, Nayak SR, Madhyastha S, Vadgaonkar R, et al. (2008) The palmaris longus muscle: its anatomic variations and functional morphology. *Rom J Morphol Embryol* 49: 215-217.
4. Thompson NW, Mockford BJ, Cran GW (2001) Absence of the palmaris longus muscle: a population study. *Ulster Med J* 70: 22-24.
5. Sebastin SJ, Lim AY (2006) Clinical assessment of absence of the palmaris longus and its association with other anatomical anomalies-- a Chinese population study. *Ann Acad Med Singapore* 35: 249-253.
6. Machado AB, Didio LJ (1967) Frequency of the musculus palmaris longus studied in vivo in some Amazon indians. *Am J Phys Anthropol* 27: 11-20.
7. Reimann AF, Daseler EH, Anson BJ, Beaton LE (1944) The palmaris longus muscle and tendon; a study of 1600 extremities. *Anat Rec* 89: 495-505.
8. Thompson JW, McBatts J, Danforth CH (1921) Hereditary and racial variations in the musculus palmaris longus. *Am J Phys Anthropol* 4: 205-220.
9. Yildiz M, Sener M, Aynaci O (2000) Three-headed reversed palmaris longus muscle: a case report and review of the literature. *Surg Radiol Anat* 22: 217-219.
10. Oommen A, Rajarajeshwari (2002) Palmaris longus – Upside Down. *J Anat Soc India* 51: 232-233.
11. Chauhan R (2003) A typical innervation of palmaris longus - A case report. *J Anat Soc India* 52: 171-173.
12. Davidson BA (1995) Lip augmentation using the palmaris longus tendon. *Plast Reconstr Surg* 95: 1108-1110.
13. Malaviya GN (2003) Palmaris longus--a muscle with multiple uses in leprosy-affected hands. *Indian J Lepr* 75: 327-334.
14. Surut J, Ekamol T, Weerachai K (2002) Palmaris longus and plantaris Tendon: Anatomical variations and relationship. *Srinagarind Med J* 17: 160-163.
15. Grechenig W, Clement H, Mayr J, Grechenig M (1999) [Ultrasound identification and size determination of the palmaris longus tendon]. *Biomed Tech (Berl)* 44: 319-323.
16. Thejodhar P, Potu BK, Vasavi RG (2008) Unusual palmaris longus muscle. *Indian J Plast Surg* 41: 95-96.
17. Troha F, Baibak GJ, Kelleher JC (1990) Frequency of the palmaris longus tendon in North American Caucasians. *Ann Plast Surg* 25: 477-478.
18. Wehbé MA (1992) Tendon graft donor sites. *J Hand Surg Am* 17: 1130-1132.
19. Gruber W (1872) *Beobachten aus der Menschlicher Und Yergleichendan Anatomie Berlin* *Memories de l'Academic Imperiale de St. Petersburg*. 11: 1-26.
20. Kapoor SK, Tiwari A, Kumar A, Bhatia R, Tantuway V, et al. (2008) Clinical relevance of palmaris longus agenesis: common anatomical aberration. *Anat Sci Int* 83: 45-48.
21. Ceyhan O, Mavt A (1997) Distribution of agenesis of palmaris longus muscle in 12 to 18 years old age groups. *Indian J Med Sci* 51: 156-160.
22. Igbigbi PS, Ssekitoleko HA (1998) Incidence of agenesis of the Palmaris longus muscle in Ugandans. *West African J Anat* 6: 21-23.
23. GO Mbaka, Akinlolu AA, Ayanuga AO, Shallie PD, Adefule AK (2008) The Incidence of Agenesis of Palmaris Longus among the Yoruba Tribe in Nigeria. *Nigerian J Med Rehabilitation*. 13: 11-14.
24. Gangata H (2009) The clinical surface anatomy anomalies of the palmaris longus muscle in the Black African population of Zimbabwe and a proposed new testing technique. *Clin Anat* 22: 230-235.
25. Schaeffer JP (1909) On the variations of the palmaris longus muscle. *Anat Rec* 3: 275-278.
26. Natsis K, Levva S, Totlis T, Anastasopoulos N, Paraskevas G (2007) Three-headed reversed palmaris longus muscle and its clinical significance. *Ann Anat* 189: 97-101.