

Advanced Pure Seminoma in a Young HIV – Positive Patient; A Case Report and Review of Literature

Carlo Messina^{1*} and Marco Messina²

¹IRCCS San Martino University Hospital-IST National Cancer Research Institute: Academic Unit of Medical Oncology, Italy

²San Raffaele-Giglio Hospital, Clinical Oncology Unit, Cefalù, Italy

*Corresponding author: Messina C, IRCCS San Martino University Hospital-IST National Cancer Research Institute: Academic Unit of Medical Oncology, Italy, Tel: +393339540076; Fax: +39010352753; E-mail: carlo.messi@hotmail.it

Rec date: May 31, 2016; Acc date: June 13, 2016; Pub date: June 20, 2016

Copyright: © 2016 Messina C, et al. This is an open-access article distributed under the terms of the Creative Commons Attribution License, which permits unrestricted use, distribution, and reproduction in any medium, provided the original author and source are credited.

Keywords: Germ cell tumors; Testicular cancer; HIV; HAART

Introduction

The acquired immunodeficiency syndrome (AIDS), initially recognized among homosexual men in United States in 1981 due to immunodeficiency virus (HIV), represents the worst epidemic disease of the twentieth century. It's estimated that there are 2.1 million people infected with HIV, resulting in 1.5 million AIDS deaths per year worldwide [1,2]. The overall prevalence of HIV seems to have stabilized likely due to increased survival of infected people because of combined aggressive antiretroviral treatment (cART) [2]. The distribution of HIV infection differs widely among geographic region, with nearly three quarters of the world's HIV-infected population in sub-Saharan Africa [3]. There are several modes of acquiring HIV infection: sexual transmission, parenteral transmission, and perinatal transmission. The relative importance of these different ways of transmission in driving the HIV epidemic varies geographically and has evolved over time [4]. HIV-positive patients have an increased risk to develop malignancy [5]. While some tumors, such as Kaposi's sarcoma, non-Hodgkin's lymphoma, invasive cervical cancer, and possibly Hodgkin's disease have been linked to HIV infection either for epidemiologic or for clinicopathologic features, seems to be a slight increase in the incidence of testicular malignancies in men infected with HIV compared with HIV-uninfected men [6]. This increased risk is limited to seminomas and does not appear to affect the incidence of non-seminomatous germ cell tumors (GCTs) [6].

We hereby describe the case of an HIV-positive patient with elevated tumor markers and multiple secondary retroperitoneal and mediastinal lymphadenopathy at first presentation who underwent left radical orchiectomy. Patient was started on standard first line chemotherapy with concomitant HAART antiretroviral therapy; he experienced a complete biochemical response with residual retroperitoneal mass after three cycles of Cisplatin 20 mg/m² d1-5, Etoposide 100 mg/m² d1-5, Bleomycin 30 mg d 2-9-16 every three weeks (PEB regimen) and undetectable HIV-RNA. The following attempts to provide a comprehensive review of literature on the oncological management of testicular cancer in HIV-positive patients.

Case Presentation

A 28-year-old man, smoker, was admitted to the Urology Department for a 6-month history of left painless testicular swelling. After the detection of left testicular mass with ultrasonography, patient underwent left radical orchiectomy. Pre-operative tumor markers showed α -FP1 33 U/L, β -HCG 13,8 U/L, LDH 1476 U/L. The histological examination revealed the presence of pure seminoma with

scant tumor infiltrating lymphocytes sized 64×64×53 mm (Figure 1), invading the rete testis and tunica albuginea, namely pT2, pNx, pMx. Staging total-body CT scan revealed the presence of multiple secondary para-aortic lymph node measuring 12×15×7 cm and 3×4 cm and single mediastinal lymphadenopathy. During cryopreservation of spermatic liquid, laboratory examination reported HIV- positive status, screening for HBV and HCV was negative. The case was discussed with a multidisciplinary infectious disease specialist and patient was started on antiretroviral cART therapy with raltegravir 400 mg and emtricitabine-tenofovir 400 mg both twice daily in combination with Trimethoprim-Sulfamethoxazole 160 mg+800 mg daily as prophylaxis for *Pneumocystis Carinii* pneumonia. Post-operative tumor markers showed α -FP 5 U/L, β -HCG 28 U/L, LDH 1776 U/L. Therefore patient was started on first line chemotherapy according to PEB regimen for 3 cycles. HIV-RNA level became undetectable after three weeks of antiretroviral therapy, at the beginning of the second chemotherapy cycle.

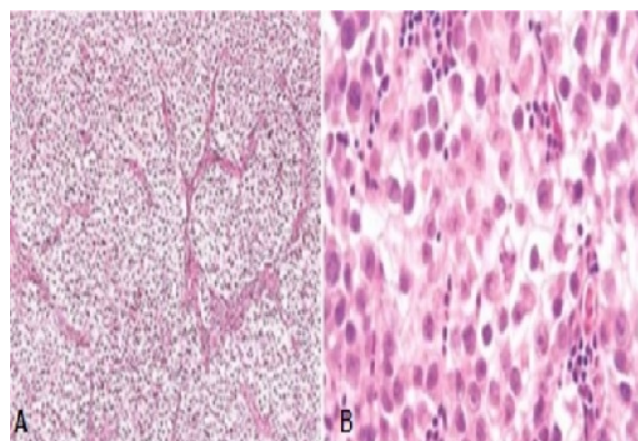
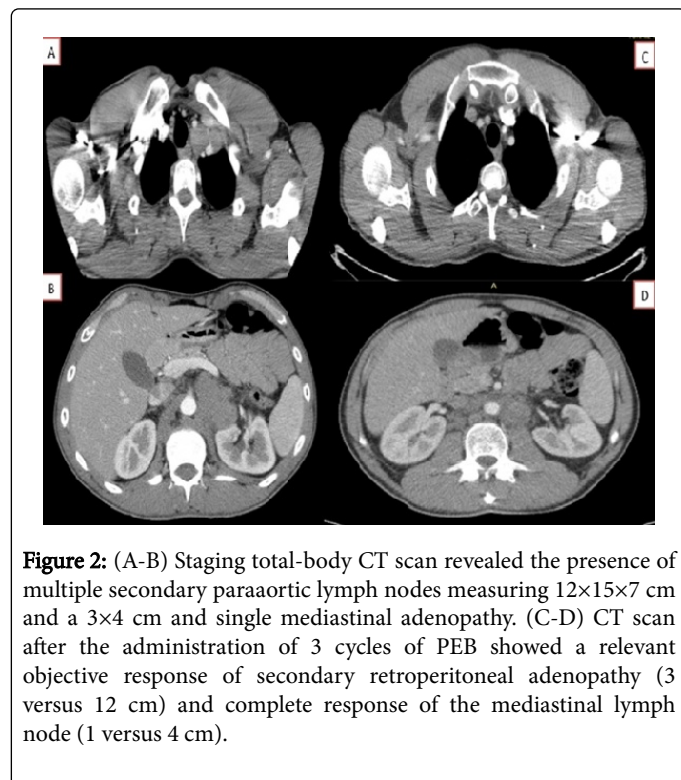


Figure 1: (A) Low magnification shows seminoma cells forming different lobules separated by septa. (B) High Magnification demonstrates large cells with distinct cell borders, pale nuclei, prominent nucleoli with scant infiltrating lymphocytes.

Treatment compliance was good without major toxicities except for non-febrile neutropenia that required Filgrastim administration in order to maintain optimal dose intensity. CT scan performed at the end of the third cycle (Figure 2) showed a relevant objective response of secondary retroperitoneal adenopathy (3 versus 12 cm), complete response of the mediastinal lymph node (1 versus 4 cm) and normalization of serum tumor markers, respectively β -HCG 1 U/L,

LDH 297 U/L. In view of the good response to chemotherapy with residual retroperitoneal lymphadenopathy, one more cycle of PE was delivered. Restaging at 6 weeks after the end of chemotherapy showed the residual retroperitoneal mass with low density at CT scan, persistent remission of tumor markers and undetectable HIV-RNA. Patient is currently followed-up with periodical clinical and instrumental evaluation.



Discussion

Although testicular cancer is responsible for only 1% of all cancers in men, it is the most common solid malignancy among males between the ages of 15 and 35 [7]. Data from SEER revealed that almost 95% of testicular cancers are GCTs that are divided according to histology into seminomas and non-seminomas, while other testicular malignancies include Leydig cell and Sertoli cell tumors, gonadoblastoma, lymphomas and carcinoids tumors [8]. Although approximately each year 8700 men are diagnosed with testicular cancer in the United States, it's estimated that most of them will survive due to the availability of effective treatment, and fewer than 400 men will die of their tumor [7]. A review based on data from 12 European countries found that the incidence of GCTs was increasing by 1 to 6% per year in the various countries; however mortality rates decreased or were stable in most regions, reflecting improvements in treatment [9]. Testicular cancers represent one of the most curable neoplasms, accounting 5-year survival rate over 95% [7]. Risk-adapted chemotherapy with 3 or 4 cycles of PEB according to the prognostic classification of International Germ Cell Cancer Collaborative Group (IGCCCG) is the standard of care for patients with advanced or metastatic GCTs [8,9]. The optimal treatment of relapsed GCTs depends upon the response to prior therapy, the location and timing of the relapse, and tumor histology. For men who relapse after first line chemotherapy with PEB, TIP (Paclitaxel, Ifosfamide plus Cisplatin) or VeIP (Vincristine, Ifosfamide

plus Cisplatin) are the two most common standard regimens recommended by international guidelines [10-12]. Men with GCTs in second or subsequent relapse and those who progress during or immediately after a Platinum-based chemotherapy regimen are considered to have Platinum-refractory disease and high dose chemotherapy represents the preferred option for this subset of patients [10-12].

Men with HIV-acquired immunodeficiency syndrome are reported to be at increased risk for GCT, particularly seminoma [13]. Goedert et al. reported in a large epidemiologic study carried out with matching population-based cancer and HIV/AIDS registry data among 268,950 men who developed AIDS in 1980 to 2003 that seminoma risk was increased significantly with HIV/AIDS (standardized incidence ratio 1.9; 95% CI, 1.6-2.2), whereas non-seminoma was not. Seminoma risk was elevated regardless of age, race, or HIV/AIDS transmission group [13]. In a large multi institutional study, Powles et al. examined the natural history of GCTs in patients with HIV and the effect of HAART in the epidemiology of the HIV-related GCT [14]. Among 35 cases of patients with HIV-related GCTs, testicular seminoma occurs significantly more frequently in HIV-positive men (relative risk 5.4: 95% CI, 3.35 to 8.1) than in the matched control population, while non-seminoma did not occur more frequently. Moreover there was no change in the incidence of GCT since the introduction of HAART [14].

However the reason for increased risk of seminoma among HIV-positive patients remains unknown. Impairment of immune-surveillance by HIV infection has been proposed as a possible mechanism supported by the evidence that a higher extent of lymphocyte infiltration in stage I seminoma is associated with a reduced risk of disease recurrence [15].

Initial studies suggested that patients with HIV-related cancer had worse outcome compared to those who were HIV negative due to high mortality for opportunistic infections such as *Pneumocystis Carinii* pneumonia, less tolerance to chemotherapy regimen resulting in treatment discontinuation and lower response rate and lastly a more aggressive behavior of GCT due to an intrinsic chemotherapy resistance [16]. However no prospective randomized clinical trial are available to explore prognosis, clinical outcome and oncological management for HIV-positive patients with testicular cancer, so decision making is often based on large retrospective series. In a matched control case-control study, Powles et al. compared the treatment outcomes for HIV-positive and negative men with GCT and the impact of HAART on the response to chemotherapy and overall survival (OS) [17]. The 5 – years OS rates among HIV-positive cohort was significantly decreased when compared to the control (76% vs 90%, p=0.03). However HIV was responsible for 70% of this mortality. Moreover, although the introduction of HAART decreased the HIV-related mortality, there were a similar number of tumor-related deaths between case and control in the pre and post HAART era. Relapse free survival for Stage I patients treated with orchiectomy or surveillance was not affected by HIV status (p=0.68). No difference in disease free survival was reported in patients with metastatic spread (p=0.78). Treatment toxicity in the HIV-positive and negative patients was not directly compared, however no chemotherapy related deaths were recorded, suggesting that toxicities do not exceed in HIV-positive patient compared to controls [17].

Moreover Bernardi et al. retrospectively analyzed the clinical outcome of 26 HIV- infected patients with testicular GCTs (14 seminoma and 12 non-seminoma) observed within the Italian Cooperative Group on AIDS and Tumors (GICAT). Treatment with

PEB regimen or radiotherapy was delivered according to histology and tumor stage at diagnosis. Prophylactic administration of Trimethoprim was delivered in order to prevent *Pneumocystis Carinii* pneumonia. Complete response rate was 95%, while recurrence occurred in 32%. The 3-year OS and disease free survival were both 65%. Severe hematologic toxicities were reported in 7 of 15 patients. No patient experienced opportunistic infection, thus this finding supports the prophylaxis with Trimethoprim. Therefore authors concluded that standard chemotherapy regimen should be delivered either in HIV-positive GCT either in those HIV- negative [17].

For the case here reported, initial multidisciplinary evaluation of the HIV infection was essential in order to select the optimal drugs for HAART, whose pharmacokinetic and toxicity profile was potentially less interfering with PEB chemotherapy regimen. We were able to deliver standard first line chemotherapy respecting the pre-planned dose intensity without major toxicities. Even if this case was considered at good prognosis according to the IGCCCG classification system, we delivered a forth cycle of PE regimen, omitting Bleomycin administration to avoid pulmonary toxicity. We are aware that it might be considered an overtreatment but this decision was made from the tumor board basing on the favorable toxicity profile of the three previous chemotherapy cycles and considering the impairment of immune-surveillance, as confirmed by the evidence of low lymphocyte infiltrate at tumor level on pathological specimens.

Conclusion

The present review highlights the significant increased risk of seminoma in HIV positive patients respect to non-seminoma. Although the lack of data from prospective randomized clinical trials, tumor related mortality in HIV positive patients reported in retrospective study was similar compared with HIV-negative patients. Therefore HIV-infected patients with testicular cancer should be offered the standard oncologic therapy taking into account histology, pathological stage at diagnosis and IGCCCG class of risk, resulting in an excellent OS with respect to GCT. HAART reduced the risk of HIV-related mortality, and can be administered safely in combination with chemotherapy or radiotherapy. Prophylaxis with Thrimethoprim-Sulfamethoxazole to prevent *Pneumocystis Carinii* pneumonia should be recommended.

Conflict of Interest

All authors declare no conflicts of interest.

References

- Centers for Disease Control (CDC) (1981) Kaposi's sarcoma and Pneumocystis pneumonia among homosexual men-New York City and California. *MMWR Morb Mortal Wkly Rep* 30: 305-308.

- Zeng W, Shepard DS, Avila-Figueroa C, Ahn H (2016) Resource needs and gap analysis in achieving universal access to HIV/AIDS services: a data envelopment analysis of 45 countries. *Health Policy Plan* 31: 624-633.
- Nyindo M (2005) Complementary factors contributing to the rapid spread of HIV-I in sub-Saharan Africa: a review. *East Afr Med J* 82: 40-46.
- Piot P (2006) AIDS: from crisis management to sustained strategic response. *Lancet* 368: 526-530.
- Rubinstein PG, Aboulaifa DM, Zloza A (2014) Malignancies in HIV/AIDS: from epidemiology to therapeutic challenges. *AIDS* 28: 453-465.
- Powles T, Bower M, Daugaard G, Shamash J, De Ruyter A, et al. (2003) Multicenter study of human immunodeficiency virus-related germ cell tumors. *J Clin Oncol* 21: 1922-1927.
- Walsh TJ, Grady RW, Porter MP, Lin DW, Weiss NS (2006) Incidence of testicular germ cell cancers in U.S. children: SEER program experience 1973 to 2000. *Urology* 68: 402-405.
- Bray F, Richiardi L, Ekbom A, Pukkala E, Cuninkova M, et al. (2006) Trends in testicular cancer incidence and mortality in 22 European countries: continuing increases in incidence and declines in mortality. *Int J Cancer* 118: 3099-3111.
- International Germ Cell Consensus Classification: a prognostic factor-based staging system for metastatic germ cell cancers (1997) International Germ Cell Cancer Collaborative Group. *J Clin Oncol* 15: 594-603.
- Einhorn LH, Williams SD, Loehrer PJ, Birch R, Drasga R, et al. (1989) Evaluation of optimal duration of chemotherapy in favorable-prognosis disseminated germ cell tumors: a Southeastern Cancer Study Group protocol. *J Clin Oncol* 7: 387-391.
- Motzer RJ, Jonasch E, Agarwal N, Beard C, Bhayani S, et al. (2015) Testicular Cancer, Version 2. *J Natl Compr Canc Netw* 13: 772-799.
- Oldenburg J, Aparicio J, Beyer J, Cohn-Cedermark G, Cullen M, et al. (2015) Personalizing, not patronizing: the case for patient autonomy by unbiased presentation of management options in stage I testicular cancer. *Ann Oncol* 26: 833-838.
- Goedert JJ, Purdue MP, McNeel TS, McGlynn KA, Engels EA (2007) Risk of germ cell tumors among men with HIV/acquired immunodeficiency syndrome. *Cancer Epidemiol Biomarkers Prev* 16: 1266-1269.
- Parker C, Milosevic M, Panzarella T, Banerjee D, Jewett M, et al. (2002) The prognostic significance of the tumour infiltrating lymphocyte count in stage I testicular seminoma managed by surveillance. *Eur J Cancer* 38: 2014-2019.
- Hentrich MU, Brack NG, Schmid P, Schuster T, Clemm C, et al. (1996) Testicular germ cell tumors in patients with human immunodeficiency virus infection. *Cancer* 77: 2109-2116.
- Powles T, Bower M, Shamash J, Stebbing J, Ong J, et al. (2004) Outcome of patients with HIV-related germ cell tumors: a case-control study. *Br J Cancer* 90: 1526-1530.
- Bernardi D, Salvioni R, Vaccher E, Repetto L, Piersantelli N, et al. (1995) Testicular germ cell tumors and human immunodeficiency virus infection: a report of 26 cases. Italian Cooperative Group on AIDS and Tumors. *J Clin Oncol* 13: 2705-2711.