

Adductor Canal Block Combined with Sciatic Nerve Block Vs. Local Analgesic Infiltration for Pain Control after Total Knee Arthroplasty

Magdy H Eldegwy^{1*} and Mohamed A Negm²

¹Department of Anesthesiology and Intensive Care, Faculty of Medicine, Al-Azhar University, Cairo, Egypt

²Department of Orthopedic Surgery, Faculty of Medicine, Al-Azhar University, Cairo, Egypt

*Corresponding author: Eldegwy MH, Department of Anesthesiology and Intensive Care, Faculty of Medicine, Al-Azhar University, Cairo, Egypt, E-mail: magdydegwy@gmail.com

Received date: December 26, 2017; Accepted date: January 22, 2018; Published date: January 29, 2018

Copyright: ©2018 Eldegwy MH, et al. This is an open-access article distributed under the terms of the Creative Commons Attribution License, which permits unrestricted use, distribution, and reproduction in any medium.

Abstract

Background: A combined adductor canal block (ACB) and sciatic nerve block (SNB) is new different way to achieve an efficient postoperative analgesia after total knee replacement (TKR) that spares the weakness of quadriceps femoris muscle. This prospective randomized controlled trial aimed to evaluate the efficiency and safety of the combined adductor canal with sciatic nerve blocks versus local analgesic infiltration alone for pain control after total knee replacement.

Patients and methods: Forty patients (ASA II, and III), undergoing unilateral total knee replacement, were randomly and allocated to two groups (20 patients each), block group (ACB+SNB): the patient received US- guided adductor canal block combined with sciatic nerve block, local group (LAI): patient received local analgesic injection (LAI) to entire of the knee joint. The primary outcomes were postoperative visual analogue scale (VAS) at rest and with movement, first request of analgesics and 24 h total consumption of morphine. Secondary outcome measures included sedation score and side effects associated with morphine consumption like nausea, vomiting.

Results: There was a significant reduction in postoperative morphine consumption, VAS, nausea and vomiting and sedation at 12 h in local group. There were no complications attributable to the ACB or SNB blocks.

Conclusion: Combined adductor canal with sciatic nerve blocks could significantly reduce VAS scores, morphine consumption, and first request for analgesia in comparison with local analgesic infiltration alone following TKA. Additionally, there is a lower incidence of sedation, nausea and vomiting in the combined blocks group.

Keywords: Adductor canal block; Sciatic nerve block; Local analgesic infiltration; VAS; Total knee replacement

Introduction

Total knee replacement (TKR) is a common surgery to improve quality of life and mobility in patients with chronic osteoarthritis. This surgery is mostly associated with moderate to severe pain [1,2]. Good post-operative analgesia after TKR facilitates of early mobilization, reduction of length of hospital stay, less postoperative complications, prevents progression of acute pain to chronic pain and provides a hemodynamic stability [3].

There are many analgesic regimens have been described to relieve the postoperative pain after TKR. Local anesthetic infiltration (LAI) is an alternative, appropriate anesthetic option to patient-controlled analgesia (PCA) of opioids and peripheral nerve blocks that usually performs by orthopedic surgeons. It has low cost and lack of a motor block of the lower limb. This technique was firstly reported by Bianconi and colleagues [4] since 14 years for knee arthroplasty. It has been become widespread among orthopedic surgeons. LAI usually administrates as periarticular or with intra-articular infiltration. Meanwhile, the efficacy of LAI was comparable to that of epidural anesthesia, femoral nerve block (FNB) [2], adductor canal block (ACB) [5], and intrathecal morphine [6]. Sciatic nerve block (SNB) and LAI

are two major options to supplement FNB in relieving of pain after TKR, However, its short duration of action limited its clinical application [7-9].

The PCA opioids may be associated with some side effects like nausea, vomiting, and respiratory depression. Epidural analgesia usually causes pruritus and urinary retention unpleasant numbness of a large area of the lower limb is common after FNB [10]. A peripheral nerve block (PNB) has many advantages over PCA and epidural analgesia. Epidural anesthesia has good postoperative analgesia, but it limits the use of anticoagulants to guard against deep venous thrombosis (DVT). Non-steroidal anti-inflammatory drugs may cause renal complications, gastrointestinal bleeding, and epidural hematoma, especially when combined with anti-thrombotic prophylaxis like low molecular weight heparin [11]. FNB decreases the strength of quadriceps femoris muscle that increasing the risk of fall after TKR, and prolongs the hospital stay. Many investigators still consider FNB the gold standard postoperative analgesic therapy after TKR [12-14]. ACB recently has gained popularity because of the less motor weakness for quadriceps muscle. The adductor canal is a tunnel in the middle third of the thigh, extending from the apex of the femoral triangle to end at the adductor hiatus. The Sensory nerve fibers that supply knee joints were located in this canal, moreover, blocking of these sensory nerve fibers could provide good analgesia after TKR [14].

ACB was introduced recently to manage the pain after knee surgery [15,16]. It is a technique resulting in sensory blockade and can be easily visualized by ultrasonography at the middle third of the thigh [17]. It is a sufficient analgesic and has advantage from FNB due to lack of weakness of quadriceps femoris muscle. Thus, the risk of fall was low and the success rate is high. Combined LAI with ACB may improve and prolong analgesia [5]. The sensory fibers for knee joint involve both the femoral and sciatic nerves. FNB and LAI differ in their effects on these nerves because FNB has analgesic effects only in the femoral nerve area, whereas LAI involves the injection into the entire knee joint [5].

We compared ultrasound guided combined adductor canal and sciatic nerve blocks that performed by anesthesiologist with surgeon applied local anesthetic infiltration for analgesic efficacy within the first 24 h after TKR.

Patients and Methods

After obtaining approval from the Regional Ethics Committee, and written informed consents, we conducted this randomized, controlled clinical trial. Forty patients (ASA II, and III), undergoing unilateral total knee replacement, were randomly and allocated to two groups (20 patients each). Block group (ACB+SNB): the patient received US-guided adductor canal block combined with sciatic nerve block with injection of 15 ml levobupivacaine 0.25% for each nerve block. Local group (LAI): patient received local injection of total volume 100 mL of mixture of 48.25 mL of normal saline, 50 mL 0.25% levobupivacaine, 0.75 mL (0.75 mg) of adrenaline, 1 mL of ketorolac (30 mg) to entire of the knee joint. Exclusion criteria were patients with history of allergy to local anesthetics, patients Scheduled for bilateral TKA major systemic disease, regular narcotic use, blood coagulopathy, neuromuscular disease, sensory impairment of the lower limb, and patients who were unable to understand the response grading of the Visual Analogue Scale (VAS). All patients were instructed one day before surgery about the study protocol and the use of VAS.

There was no deviation from the standard preoperative, postoperative care, and anesthesia protocols remained unchanged. All patients underwent general anesthesia and was induced with fentanyl 1 mcg/kg, 2% lidocaine (1.5 mg/kg), 2-3 mg/kg of propofol, rocuronium (0.5 mg/kg), and then endotracheal intubation was done. Anesthesia was maintained with sevoflurane and oxygen. Anesthesia was maintained with sevoflurane 1.5-2 vol% in 50% O₂/air. Anesthetics were titrated according to hemodynamic parameters. The lungs were mechanically ventilated aiming ECO₂ between 35-40 mmHg. Additionally, remifentanyl infusion was started at incision from 0.1 µg/kg/min, increased or decreased according to the blood pressure or heart rate changed by approximately 15% of the baseline, and stopped at skin closure. No additional opioids or analgesics including fentanyl were given during the surgery.

All surgeries and LAI were done by single orthopedists. A certified anesthesiologist in regional anesthesia performed all peripheral nerve blocks with the assistance of other anesthesia technician. The evaluators and patients were blinded to the group assignments throughout the study. Another surgeon and anesthesiologist (not included in this study) were involved in patient's data collection. All blocks were single injection, unilateral and performed using a portable ultrasound machine multi-beam capability (Philips Healthcare[®], Sqaq Release 1.0.1, USA), with two probes: a linear 7-12 MHz probe for

ACB and a curvilinear 2-5 MHz probe for SNB. Both probes were covered with Tegaderm dressing (3M, St. Paul, MN) during the block.

LAI: The patients received infiltration of the surgical site with the local analgesic solution that divided into four doses in 3 syringes. The first dose (25 mL) was given into the posterior part of the capsule and in the intercondylar area before installing the implant. The second dose (50 mL) was given into the anterior part of the capsule, the medial and lateral collateral ligaments, and along the tibia and femur. After closure of the capsule, the third dose (25 mL) was infiltrated into the subcutaneous tissue.

ACB: Full aseptic precautions were maintained during the block. The skin was sterilized with povidone iodine 10%, then the linear ultrasound probe was placed transverse to the longitudinal axis of the extremity at the mid thigh, then the femoral artery was found under the sartorius muscle with the vein in the short axis. At this level, the saphenous nerve (SN) which appeared as a hyperechoic structure and was placed just lateral to the artery in the adductor canal (Figure 1). A 20 G, 8 cm Tuohy needle (Sonoplex[®]; Pajunk, USA) was connected to a 20 mL syringe containing 15 mL of 0.25% levobupivacaine, and then introduced in-plane approach from the lateral aspect of the ultrasound probe and directed towards the SN, then the local anesthetic was infiltrated around it [18,19].

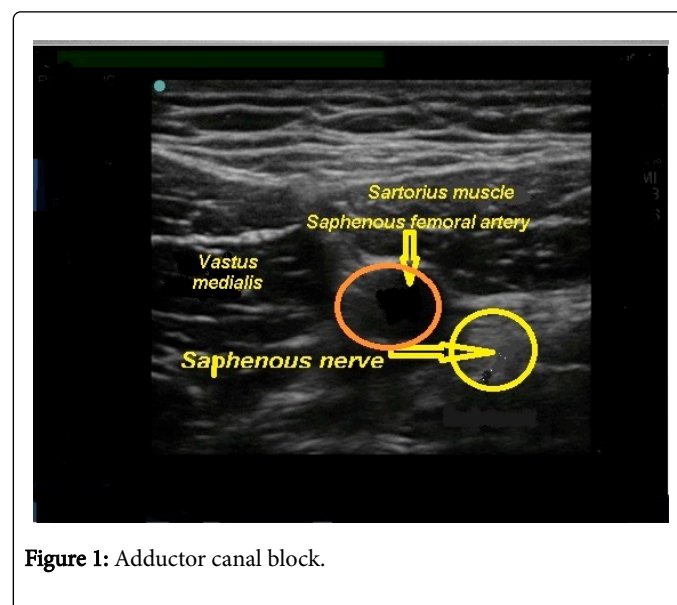


Figure 1: Adductor canal block.

SNB: Full aseptic precautions also were maintained during this block. Usually the best ultrasound scanning of the proximal sciatic nerve can be achieved in the sub-gluteal area. At this level, the sciatic nerve becomes more in a superficial position and can be identified between the gluteus maximus and biceps muscles between two bony landmarks of the greater trochanter and ischial tuberosity. The sciatic nerve appears as round to oval to flat and only moderately hyperechoic structure. We used a curvilinear ultrasound probe to perform sub-gluteal approach to SNB. Depending upon the depth of the sciatic nerve, the patients were moved to a lateral recumbent position, then the curvilinear ultrasound probe was placed parallel to the line created by the greater trochanter and ischial tuberosity [20], then a 20 G, 10 cm Tuohy needle (Sonoplex[®]; Pajunk, USA) was connected to a 20 mL syringe containing 15 mL of 0.25% levobupivacaine, and introduced out-of-plane technique in the transverse plane, and directed towards the sciatic nerve, then the local anesthetic was infiltrated around it

(Figure 2). After we had finished SNB, the patient moved into the supine position again to start the recovery from the general anesthesia.

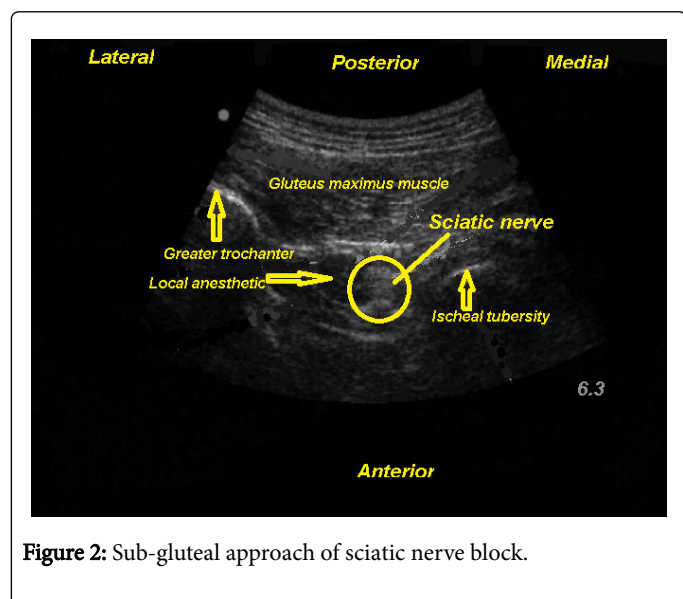


Figure 2: Sub-gluteal approach of sciatic nerve block.

Sevoflurane was discontinued and neuromuscular reversal was provided with administration of 0.05 mg/kg of neostigmine and 0.02 mg/kg of atropine intravenously, then tracheal extubation was done once the patient fulfilled the criteria of extubation. The patients were transferred to the post-anesthesia care unit (PACU) for one h, and remained monitored using ECG, noninvasive blood pressure, and pulse oximetry until meeting the PACU discharge criteria. If the blocks or LAI were ineffective in recovery room, the patient would exclude from the study. Both groups received paracetamol 1 gm/8h. The primary outcomes that measured in this study were postoperative VAS at rest and with movement, first request of analgesics and 24 h total consumption of morphine. Patients were asked to mark their pain scores on a VAS (0-10 cm, with unmarked line in which 0 cm= no pain and 10 cm= worst pain imaginable). Postoperatively, an investigator collected the VAS pain scores at rest and with movement at 1, 4, 8, 12 and 24 h. If the VAS ≥ 3 or on patient request, patient-controlled analgesia (PCA) was set to give 1mg bolus of morphine with 7 min lockout and time to first analgesic request was recorded. Secondary outcome measures included sedation score and side effects associated with morphine consumption like nausea, vomiting. In cases of postoperative nausea and vomiting, patients received 4 mg IV ondansetron. Sedation scores were assigned by the investigator using a sedation scale (awake and alert=0, quietly awake=1, asleep but easily aroused=2, deep sleep=3).

Randomization

Patients were randomized into two study groups by drawing sequentially numbered, coded, sealed, and opaque envelopes with a computer-generated allocation number. A research assistant who took no further part in the study prepared the sealed envelopes for the randomization (Figure 3).

Statistical analysis

The findings of the groups were statistically compared using SPSS version 20 (SPSS Inc., Chicago, IL). Data were expressed as mean \pm SD, number and percentage. Nominal non-parametric data were analyzed

using Chi-Square test. Parametric data were compared using unpaired t-test. Ordinal non-parametric data were analyzed using Mann-Whitney U-test. P-values <0.05 were considered statistically significant.

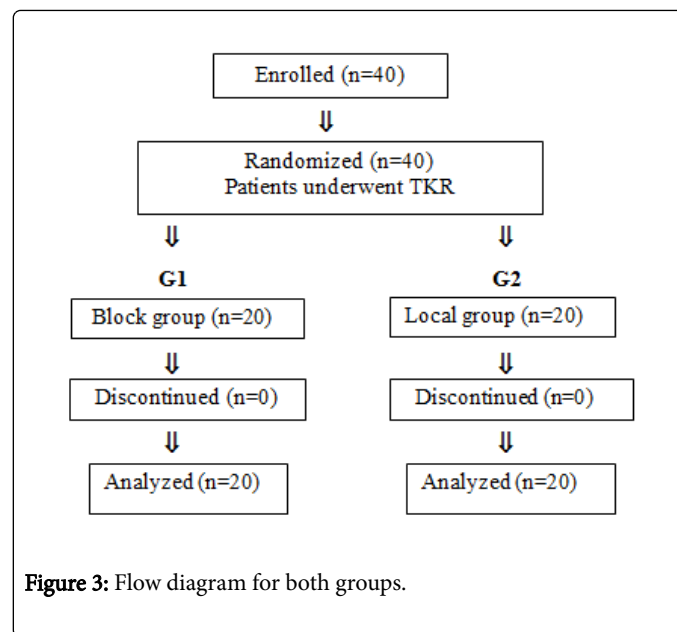


Figure 3: Flow diagram for both groups.

Results

Variable	Block group (n=20)	Local group (n=20)	P value
Age (years)	55 \pm 12	58.3 \pm 16.3	0.7
Weight (kg)	69.5 \pm 8.8	72 \pm 8.7	0.63
Sex (male/female)	16/4	17/3	0.69
ASA (II/III)	14/6	14/6	1
Duration of surgery (min)	130.3 \pm 29	128.8 \pm 33	0.93
Data are expressed as mean \pm SD and number			

Table 1: Patients' characteristics and clinical data.

Variable	Block group (n=20)	Local group (n=20)	P value
1 h	1.75 \pm 0.76	2.21 \pm 0.64	0.28
4 h	2.05 \pm 0.67	2.33 \pm 0.7	0.5
8 h	2.46 \pm 0.39	2.9 \pm 0.78	0.25
12 h	2.73 \pm 0.4	4.45 \pm 1.65*	0.03
24 h	3.43 \pm 0.9	4.2 \pm 1.65	0.34
Data are expressed as mean \pm SD. *Significant compared to other group.			

Table 2: Postoperative pain VAS score at rest.

The saphenous and sciatic nerves were localized by ultrasound easily, and the blocks were performed without complications. Patient's

characteristics and clinical data were comparable in both groups (Table 1).

There was statistical increase in VAS pain score at rest and with movement in local group at 12 h postoperatively compared to local group (Tables 2 and 3).

Variable	Block group (n=20)	Local group (n=20)	P value
1 h	1.9 ± 0.68	2.23 ± 0.8	0.28
4 h	2.23 ± 0.46	2.53 ± 0.67	0.4
8 h	2.53 ± 41	2.95 ± 0.72	0.25
12 h	2.88 ± 0.13	4.7 ± 1.78*	0.032
24 h	3.76 ± 1	4.36 ± 1.4	0.57

Data are expressed as mean ± SD. *Significant compared to other group.

Table 3: Postoperative pain VAS score with movement.

The time to first request for analgesia postoperatively was significantly longer in block group compared to local group. Moreover, there was a significant increase in morphine consumption through 24 h postoperatively in local group compared to block group (Table 4).

Variable	Block group (n=20)	Local group (n=20)	P value
First request (min)	501.5 ± 74	352.6 ± 117*	0.025
PCA morphine consumption (mg/24 h)	4.66 ± 3.14	11.5 ± 3*	0.03

Data are expressed as mean ± SD. *Significant compared to other group; PCA= Patient Controlled Analgesia.

Table 4: Time to first analgesic request and PCA morphine consumption postoperatively.

There was a significant increase in the incidence of postoperative nausea and vomiting (PONV) in local group compared to block group. In addition, there was a significant increase in sedation score in local group compared to block group at 12 h postoperatively; however there was no significant difference at other study intervals (Table 5).

Variable	Block group (n=20)	Local group (n=20)	P value
Sedation Score			
4 h	0.8 ± 0.75	1 ± 0.9	0.73
8 h	1 ± 0.63	1.16 ± 0.75	0.68
12 h	0.5 ± 0.55	1.83 ± 1.17*	0.03
24 h	0.66 ± 0.51	1 ± 1.26	0.56
Incidence of PONV	6 (30%)	3 (15%)*	0.034

Data are expressed as mean ± SD and number (%). *Significant compared to other group. PONV=Post-Operative Nausea and Vomiting.

Table 5: Postoperative sedation score and incidence of PONV.

Discussion

In our prospective, randomized study, we evaluated the analgesic efficacy of ACB+SNB blocks to local analgesic infiltration for pain VAS at rest and with movement, first request of morphine, total morphine consumption and occurrence of sedation and side effects due to more morphine consumption like PONV. This study demonstrates that ACB+SNB blocks provide effective prolonged postoperative analgesia, when compared with LAI, in patients undergoing unilateral TKR. Moreover, combined ACB+SNB blocks reduced postoperative morphine consumption; improved pain scores at rest and on movement and prolonged the time to first request for supplemental analgesia, and reduced the incidence of PONV and sedation.

Most of previous published studies compared the peripheral nerve blocks with LAI, contributes to add SNB to FNB in comparison with LAI, or compare ACB with FNB after TKR, while there no more studies compared the combined ACB and SNB with LAI. Only one clinical trial compared both blocks (ACB+SNB) with LAI for pain management after TKR, moreover, results of our study contradict this study[21], which showed that combined ACB with SVB was comparable in analgesic efficacy to LAI.

The present study supports the idea that the sciatic nerve also contributes to the postoperative pain after TKR as regards the combined innervation of the knee joint by both the femoral and sciatic nerves, and the overlap in their innervation of the anterolateral aspect of the knee [22]. There are many meta-analysis studies were supporting that adding SNB to FNB can reduce postoperative opioid consumption and decreased the postoperative pain VAS score in the first 24 h after TKR [23-26].

Some of previous trials stated that effectiveness of LAI in management of postoperative pain when compared with single femoral nerve block. Song et al. [27] stated that local analgesic injections improved post-operative pain control with minimal side effects when compared with PCA. Moreover, peri-articular LAI can replace PCA for postoperative pain control after TKR. In a meta-analysis study [28] that compared the post-operative analgesia that achieved with LAI and femoral nerve block of TKR, they found that LAI might be the best option in pain control after TKR, as it achieved a faster pain relief and was simple to perform than femoral nerve block for patients with TKA, Bin Hu et al. meta-analysis study [29] suggested that LIA provided better analgesia after TKR than regional nerve blocks at rest and preserved quadriceps femoris muscle function in the immediate postoperative period. Moreover, there many studies found that LAI provided similar postoperative pain control to femoral nerve block after TKR. In addition, LAI could significantly reduce the morphine consumption compared to FNB, suggesting that LIA has a better analgesic effect than FNB [30-32]. However, LIA has limited to perform in some orthopedic centers due to its short duration of action and insufficient analgesia to the anterior aspect of the knee joint. Therefore, multimodal analgesia regimens were recommended to achieve pain control with less total perioperative morphine consumption, and facilitate early mobilization and discharge.

Both FNB and ACB can give good postoperative pain relieve after TKR [33]. Recently, there has been a shifting trend from the use of FNB towards the use of adductor canal block for postoperative analgesia in patients undergoing TKA. The anterior branch of obturator nerve, the saphenous nerve, and a branch of the posterior femoral nerve within the adductor canal are sensory to the surrounding tissue of the knee joint [33,34]. Kim et al. [35] compared

femoral nerve block and adductor canal block and for post-operative pain management with TKR, they found that the comparative reduction of post-operative pain with less opioid consumption, additionally, adductor canal block had spring of the quadriceps with no difference in range of motion. Wang et al. [24] performed a meta-analysis from randomized controlled trials and found that no difference between adductor canal block and femoral nerve block as regards the pain management or morphine consumption after TKR, in addition, a better knee mobility with sparing of quadriceps strength and decreased risk of falls. A recent meta-analysis of randomized controlled trials have stated that adductor canal block is effective as a rescue additional block when local infiltration analgesia is insufficient for post-operative pain management, moreover, the combined LAI with adductor canal block seem to be associated with improvement of pain after TKR [34]. However, still there is a lack of clinical trials of the combined adductor canal block with periarticular infiltration versus periarticular infiltration alone for pain management after TKR. There is a study [5] indicated that the combined adductor canal block with periarticular infiltration could significantly reduce VAS scores at rest when compared with periarticular infiltration alone for pain management after TKR.

On the other hand, there is recent study [36] have compared ACB with FNB, they evaluated the block efficacy of the two blocks after arthroscopic knee, and they reported that patients with FNB had superior analgesia with less analgesic requirements compared with ACB. Moreover, a meta-analysis study [33] stated that the FNB and ACB had no significant difference as regards of VAS score with within 48h postoperatively and the muscle strength of quadriceps muscle. Adrenaline has some advantages in peripheral nerve blocks like maintaining tissue levels of local anesthetic and decreasing bleeding [37]. However, the precautions should be taken to avoid injecting adrenaline too close to the skin because a case of wound necrosis has been recorded [38].

Conclusion

ACB combined with SNB provided decreased VAS scores and less morphine consumption at 12 h compared with LIA in total knee arthroplasty. In addition, it was associated with less sedation and lower risks of nausea and vomiting.

References

1. Nakagawa S, Arai Y, Inoue H, Kan H, Hino M, et al. (2016) Comparative effects of periarticular multimodal drug injection and single-shot femoral nerve block on pain following total knee arthroplasty and factors influencing their effectiveness. *Knee Surg Relat* 28: 233-238.
2. Albrecht E, Guyen O, Jacot-Guillarmod A, Kirkham KR (2016) The analgesic efficacy of local infiltration analgesia vs femoral nerve block after total knee arthroplasty: a systematic review and meta-analysis. *Br J Anaesth* 116: 597-609.
3. Chaubey D, Mahajan HK, Chauhan PR, Govind PS, Singh P, et al. (2017) Comparison of Continuous Femoral Nerve Block versus Local Infiltration Analgesia as a Postoperative Analgesia in Unilateral Total Knee Arthroplasty. *J Clin Diagn Res* 11: 13-16.
4. Bianconi M, Ferraro L, Traina G, Zanoli G, Antonelli T, et al. (2003) Pharmacokinetics and efficacy of ropivacaine continuous wound instillation after joint replacement surgery. *Br J Anaesth* 91: 830-835.
5. Xing Q, Dai W, Zhao D, Wu J, Huang C, et al. (2017) Adductor canal block with local infiltrative analgesia compared with local infiltrate analgesia for pain control after total knee arthroplasty: A meta-analysis of randomized controlled trials. *Medicine* 96: e8103.
6. Andersen L, Kehlet H (2014) Analgesic efficacy of local infiltration analgesia in hip and knee arthroplasty: a systematic review. *Br J Anaesth* 113: 360-374.
7. Andersen L, Husted H, Otte KS, Kristensen BB, Kehlet H (2008) A compression bandage improves local infiltration analgesia in total knee arthroplasty. *Acta orthop* 79: 806-811.
8. Mahadevan D, Walter RP, Minto G, Gale TC, McAllen CJ, et al. (2012) Combined femoral and sciatic nerve block vs combined femoral and periarticular infiltration in total knee arthroplasty: a randomized controlled trial. *J arthroplasty* 27: 1806-1811.
9. McNamee D, L Parks, K Milligan (2002) Postoperative analgesia following total knee replacement: an evaluation of the addition of an obturator nerve block to combined femoral and sciatic nerve block. *Acta Anaesthesiol Scand* 46: 95-99.
10. Ilah, OA, JP Davidson, HS Tullos (1994) Continuous epidural analgesia using fentanyl and bupivacaine after total knee arthroplasty. *Clin Orthop Relat Res* 299: 44-52.
11. Davies A, Segar E, Murdoch J, Wright D, Wilson I (2004) Epidural infusion or combined femoral and sciatic nerve blocks as perioperative analgesia for knee arthroplasty. *Br J Anaesth* 93: 368-374.
12. Albrecht E, Morfey D, Chan V, Gandhi R, Koshkin A, et al. (2014) Single-injection or continuous femoral nerve block for total knee arthroplasty? *Clin Orthop Relat Res* 472: 1384-1393.
13. Paul JE, Arya A, Hurlburt L, Cheng J, Thabane L, et al. (2010) Femoral Nerve Block Improves Analgesia Outcomes after Total Knee Arthroplasty A Meta-analysis of Randomized Controlled Trials. *Anesthesiology* 113: 1144-1162.
14. Gao F, Ma J, Sun W, Guo W, Li Z, et al. (2017) Adductor canal block versus femoral nerve block for analgesia after total knee arthroplasty: a systematic review and meta-analysis. *Clin J pain* 33: 356-368.
15. Hanson NA, Allen CJ, Hostetter LS, Nagy R, Derby RE, et al. (2014) Continuous ultrasound-guided adductor canal block for total knee arthroplasty: a randomized, double-blind trial. *Anesth & Analg* 118: 1370-1377.
16. Mariano E, Perlas A (2014) Adductor Canal Block for Total Knee Arthroplasty The Perfect Recipe or Just One Ingredient? *Anesthesiology* 120: 530-532.
17. Bendtsen TF, Moriggl B, Chan V, Pedersen EM, Børglum J (2014) Defining adductor canal block. *Reg Anesth Pain Med* 39: 253-254.
18. Patterson ME, Bland KS, Thomas LC, Elliott CE, Soberon JR, et al. (2015) The adductor canal block provides effective analgesia similar to a femoral nerve block in patients undergoing total knee arthroplasty-a retrospective study. *J clin anesth* 27: 39-44.
19. Grevstad U, Mathiesen O, Valentiner LS, Jaeger P, Hilsted KL, et al. (2015) Effect of adductor canal block versus femoral nerve block on quadriceps strength, mobilization, and pain after total knee arthroplasty: a randomized, blinded study. *Reg Anesth Pain Med* 40: 3-10.
20. Nagafuchi M, Sato T, Sakuma T, Uematsu A, Hayashi H, et al. (2015) Femoral nerve block-sciatic nerve block vs. femoral nerve block-local infiltration analgesia for total knee arthroplasty: a randomized controlled trial. *BMC anesthesiol* 15: 82.
21. Rizk H, Y Hosni, Abdeldayem S (2017) Combined adductor canal and sciatic nerve block compared with local intraarticular infiltration analgesia for total knee arthroplasty: a prospective blinded randomized controlled study. *Cur Orthop Pract* 28: 179-183.
22. Ilfeld BM, Madison SJ (2011) The sciatic nerve and knee arthroplasty: to block, or not to block-that is the question. *Reg Anesth Pain Med* 36: 421-423.
23. Abdallah FW, Brull R (2011) Is sciatic nerve block advantageous when combined with femoral nerve block for postoperative analgesia following total knee arthroplasty?: a systematic review. *Reg Anesth Pain Med* 36: 493-498.
24. Zhang Z, Yang Q, Xin W, Zhang Y (2017) Comparison of local infiltration analgesia and sciatic nerve block as an adjunct to femoral nerve block for pain control after total knee arthroplasty: A systematic review and meta-analysis. *Medicine* 96: e6829.

25. Cook P, Stevens J, Gaudron C (2003) Comparing the effects of femoral nerve block versus femoral and sciatic nerve block on pain and opiate consumption after total knee arthroplasty. *J arthroplasty* 18: 583-586.
26. Dang CP, Gautheron E, Guilley J, Fernandez M, Waast D, et al. (2005) The value of adding sciatic block to continuous femoral block for analgesia after total knee replacement. *Reg Anesth Pain Med* 30: 128-133.
27. Song MH, Kim BH, Ahn SJ, Yoo SH, Kang SW, et al. (2016) Peri-articular injections of local anaesthesia can replace patient-controlled analgesia after total knee arthroplasty: a randomised controlled study. *Int Orthop* 40: 295-299.
28. Yun XD, Yin XL, Jiang J, Teng YJ, Dong HT, et al. (2015) Local infiltration analgesia versus femoral nerve block in total knee arthroplasty: a meta-analysis. *Orthop Traumatol Surg Res* 101: 565-569.
29. Hu B, Lin T, Yan S, Tong S, Yu J, et al. (2016) Local infiltration analgesia versus regional blockade for postoperative analgesia in total knee arthroplasty: a meta-analysis of randomized controlled trials. *Pain physician* 19: 205-214.
30. Ma J, Zhang W, Yao S (2016) Liposomal bupivacaine infiltration versus femoral nerve block for pain control in total knee arthroplasty: A systematic review and meta-analysis. *Int J Surg* 36: 44-55.
31. Ashraf A, Raut VV, Canty SJ, McLauchlan GJ (2013) Pain control after primary total knee replacement. A prospective randomised controlled trial of local infiltration versus single shot femoral nerve block. *Knee* 20: 324-327.
32. Carli F, Clemente A, Asenjo J, Kim D, Mistraretti G, et al. (2010) Analgesia and functional outcome after total knee arthroplasty: periarticular infiltration vs. continuous femoral nerve block. *Br J anaesth* 105: 185-195.
33. Dong CC, Dong SL, He FC (2016) Comparison of adductor canal block and femoral nerve block for postoperative pain in total knee arthroplasty: a systematic review and meta-analysis. *Medicine* 95: e2983.
34. Wang D, Yang Y, Li Q, Tang SL, Zeng WN, et al. (2017) Adductor canal block versus femoral nerve block for total knee arthroplasty: a meta-analysis of randomized controlled trials. *Scientific reports* 7: 40721.
35. Kim DH, Lin Y, Goytizolo EA, Kahn RL, Maalouf DB, et al. (2014) Adductor Canal Block versus Femoral Nerve Block for Total Knee Arthroplasty: A Prospective, Randomized, Controlled Trial. *Anesthesiology* 120: 540-550.
36. Rahimzadeh P, Faiz HR, Imani F, Hobika GG, Abbasi A, et al. (2017) Relieving Pain After Arthroscopic Knee Surgery: Ultrasound-Guided Femoral Nerve Block or Adductor Canal Block? *Turk J Anaesthesiol Reanim* 45: 218-224.
37. Anderson LA, Engel GM, Bruckner JD, Stoddard GJ, Peters CL (2009) Reduced blood loss after total knee arthroplasty with local injection of bupivacaine and epinephrine. *J Knee Surg* 22: 130-136.
38. Toftdahl K, Nikolajsen L, Haraldsted V, Madsen F, Tønnesen EK, et al. (2007) Comparison of peri-and intraarticular analgesia with femoral nerve block after total knee arthroplasty: a randomized clinical trial. *Acta orthop* 78: 172-179.