

Acute Necrotizing Pancreatitis after *Tityus obscurus* Scorpion Envenomation in French Guiana

Kallel H^{*}, Mayence C, Guegueniat P and Didier Hommel

Service de Réanimation, Centre Hospitalier Andrée Rosemon de Cayenne, avenue des Flamboyants, Guyane Française, France

^{*}Corresponding author: Hatem Kallel, Service de réanimation Polyvalente, Centre Hospitalier Andrée Rosemon de Cayenne, Avenue des Flamboyants, 97300 Cayenne, Guyane Française, France, Tel: 00594-694-47-12-77; E-mail: kallelhat@yahoo.fr

Received date: October 21, 2016, Accepted date: November 07, 2016, Published date: November 15, 2016

Copyright: © 2016 Kallel H, et al. This is an open-access article distributed under the terms of the Creative Commons Attribution License, which permits unrestricted use, distribution, and reproduction in any medium, provided the original author and source are credited.

Abstract

We report the case of a 7 year old boy which presented acute necrotizing pancreatitis after he was stung by *Tityus obscurus* scorpion. The diagnosis was made on the basis of elevated amylase and lipase enzymes and on abdominal CT scan showing acute necrotizing pancreatitis involving the body and the tail of pancreas. Under analgesics and symptomatic treatment, the patient improved clinically with return of pancreatic enzymes to normal.

Keywords: Scorpion; *Tityus obscurus*; Pancreatitis

Introduction

Scorpion sting is a major health problem in many countries with several clinical manifestations varying from isolated local pain to major symptoms including respiratory, hemodynamic or neurologic failure.

Digestive manifestations after scorpion sting were widely described. They usually include gastric distension, abdominal pain, nausea, and vomiting [1-3]. Pancreatitis was also reported after *Tityus serrulatus*,

Tityus trinitatis, and *Leiurus quinquestriatus* envenomation in children [4-8]. However and in our knowledge, acute pancreatitis after *Tityus obscurus* envenomation has not been previously reported.

The Case

A seven years old boy was admitted to our ICU after severe scorpion envenomation. The animal was captured by the parents and was recognized by experts as a *Tityus obscurus*.

The accident occurred at 7:00 am, the boy was putting on his shoes, and the scorpion stung him on the third toe of his right foot.

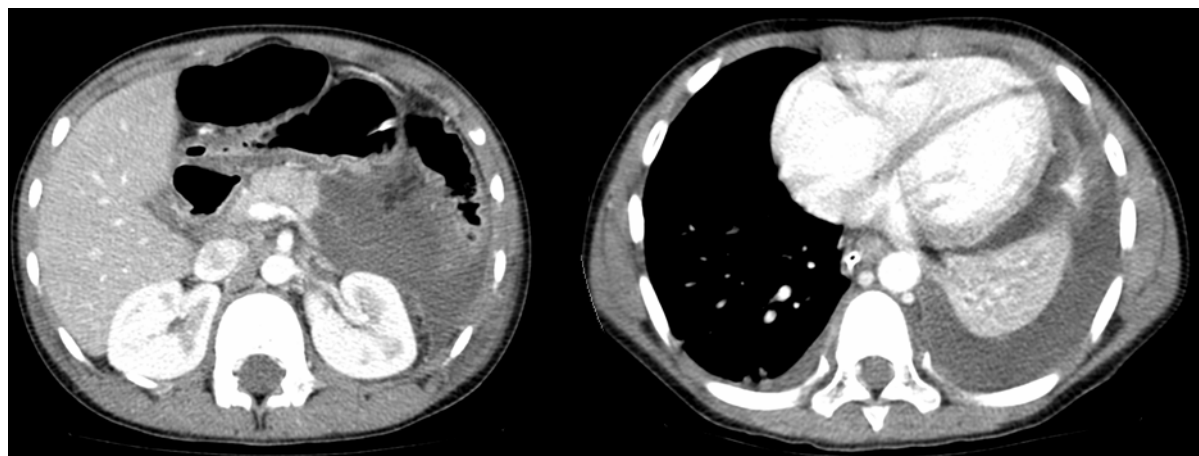


Figure 1: Abdominal and thoracic CT scan showing (A) necrosis involving most of body and tail of the pancreas with a minimal amount of ascites, (B) a left-sided abundant pleural effusion.

The first symptoms occurred 30 min later they included hyper salivation, agitation, twitching and hyperventilation. He was transported to our ICU with the diagnosis of severe scorpion sting.

On admission to ICU, the clinical exam found somnolence, twitches, hyper salivation, Dysarthria, abdominal pain with a maximum in the epigastric region, severe pain of the third right toe

and urine retention. The pupils were symmetric and reactive to light. Arterial blood pressure was 116/48 mmHg, cardiac rhythm was 128/min, respiratory rhythm was 38/min, temperature was 36.9°C, and SpO₂ was 100% under 6 l oxygen. Cardiac sounds were normal. Pulmonary auscultation showed no crackles or abnormal sounds.

Biological exams showed blood sugar at 10.9 mmol/l, leucocytosis at 14400/mm³, troponine level <0.003 µg/l, metabolic acidosis with alkaline reserves at 16 mmol/l and lactates at 7.3 mmol/l. C-reactive protein (CRP) was non-detectable. Renal and liver functions were normal.

Chest X-ray showed no pulmonary abnormalities but a gastric distension. The patient was putted on oxygen, gastric aspiration and Paracetamol. At day 2, we noted a worsening of abdominal pain with maximum at the epigastric region, vomiting and fever. Biological exams showed leucocytosis at 20700/mm³, raised CRP level at 48.5 mg/l, elevated amylase level at 1921 UI/l, elevated lipase level at 960 UI/l, alkaline reserves decreased to 14 mmol/l and CK were at 3935 UI/l. Microbiological exams were negative.

The abdominal CT scan showed large region of necrosis involving most of body and tail of pancreas with a minimal amount of ascites, (Figure 1). The chest CT scan showed a left-sided abundant pleural effusion (Figure 1).

Thoracocentesis and pleural fluid analysis performed at day 5, showed an exudate pleural fluid with protein dosage at 29 g/l and amylase dosage at 3643 UI/l (The ratio amylase in the pleural liquid/blood amylase level was 13.8).

The patient was given more pain relievers, metoclopramide, glucose serum infusion and he was kept fasting.

Evolution was marked by an improvement of the patient's condition within 6 days with return of pancreatic enzymes to normal, return of the temperature to normal, disappearance of abdominal pain, and well tolerated refeeding (Figure 2).

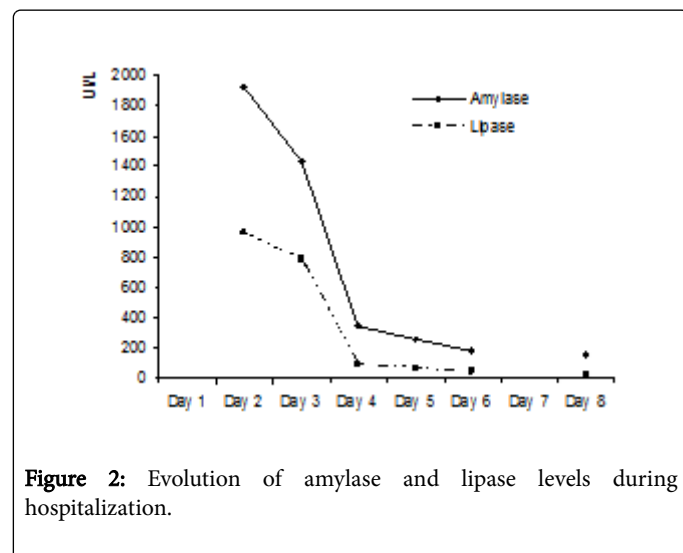


Figure 2: Evolution of amylase and lipase levels during hospitalization.

The patient was transferred to the paediatric department at day 8 of hospitalization and he leaved the hospital at day 10.

Discussion

We report a case of necrotizing pancreatitis after *Tytilus obscurus* sting in 7 years old boy. This complication is very rare and was poorly reported in the literature. Digestive complications after scorpion sting were well described with all types of scorpions. They include gastric distension, abdominal pain, nausea, and vomiting [1-3]. More rarely, acute pancreatitis was reported after *Tityus serrulatus*, *Tityus trinitatis*,

and *Leiurus quinquestriatus* envenomation in children [4-8]. In all cases, pancreatitis was diagnosed biologically. However and in our knowledge, acute pancreatitis after *Tityus obscurus* envenomation has not been previously reported.

In 1970, Bartholomew et al. [4] reported 24 cases of acute pancreatitis which appeared soon after *Tityus trinitatis* sting. The diagnosis of pancreatitis was based only on the dosage of serum amylase. This complication was explained by the capacity of venom to induce exocrine secretion in both isolated and intact pancreas and to cause contraction of sphincter of oddi [9]. Novaes et al. [6], in an experimental study found the same results with cellular damage to the pancreas when they inject Tityus toxin (from *Tityus serrulatus*) to dogs and rats. They suggest a direct action of the venom to pancreas. In another experimental study, Novaes et al. [10], found that the toxin of *Tityus serrulatus* scorpion is an agent of considerable efficacy in the induction of acute and pancreatitis in rats.

Overall, four mechanisms were advanced to explain acute pancreatitis after scorpion sting. The first is a local and direct effect of the venom on the pancreas as demonstrated by Bartholomew et al. [9] and Novaes et al. [6]. The second mechanism is ischemic secondary to a massive outpouring of catecholamines immediately after the sting leading to gastrointestinal ischemia and lactic acidosis [3]. The third mechanism is that scorpion venom inhibits angiotensine converting enzyme resulting in accumulation of bradykinine which is implicated in the development of acute reversible pancreatitis [11]. And the fourth mechanism is an over-stimulation of parasympathic system with a cholinergic effect on the pancreas [2,12].

In our case, patient developed acute necrotizing pancreatitis soon after the envenomation. The gastric distension and the elevated level of lactic acid found on admission lead us to think that ischemia is one of the principal factors explaining the occurrence of pancreatitis. In addition, in our case, pancreatitis was severe because of necrosis observed on the abdominal CT-scan and because of pleural reaction effusion with respiratory difficulties and need to thoracosentesis. However, pancreatitis was reversible with return to normal of clinical and biological disturbances within 6 days.

Tytilus obscurus is the most encountered scorpion in French Guyana [13]. It can be described as a great scorpion measuring 8 to 10 cm, it is dark in color with thin pincers [14,15]. In our case, the scorpion was captured and brought by the parents to the hospital. It was identified by experienced professionals as a *Tytilus obscurus*. Even if it is known as a non-dangerous scorpion, it can cause severe envenomation in children [14] because of the ratio body weight/volume of venom injected. So, in French Guyana, physicians have to be aware from scorpion envenomation especially in children and in low body weight persons.

In our case, the patient recovered and no further investigation was performed. So we cannot exclude pancreas malformation. However patient was examined later in the outpatient department and he was going very well.

References

1. Chippaux JP, Goyffon M (2008) Epidemiology of scorpionism: a global appraisal. Acta Trop 107: 71-79.
2. Bahloul M, Chaari A, Khlaf-Bouaziz N, Hergafi L, Ksibi H, et al. (2005) Gastrointestinal manifestations in severe scorpion envenomation. Gastroenterol Clin Biol 29: 1001-1005

3. Sofer S, Cohen R, Shapir Y, Chen L, Colon A, et al. (1997) Scorpion venom leads to gastrointestinal ischemia despite increased oxygen delivery in pigs. Crit Care Med 25: 834-840.
4. Bartholomew C (1970) Acute scorpion pancreatitis in Trinidad. Br Med J 1: 666-668.
5. Novaes G, Cardozo Cde C, Costa NM, de Falco CN, de Carvalho MH, et al. (1990) Experimental chronic interstitial pancreatitis induced by scorpion toxin in rats. Arq Gastroenterol 27: 187-190.
6. Novaes G, Cabral AP, de Falco CN, de Queiroz AC (1989) Acute pancreatitis induced by scorpion toxin, tityustoxin. Histopathological study in rats. Arq Gastroenterol 26: 9-12.
7. Sofer S, Shalev H, Weizman Z, Shahak E, Gueron M (1991) Acute pancreatitis in children following envenomation by the yellow scorpion *Leiurus quinquestriatus*. Toxicon 29: 125-128.
8. George Angus LD, Salzman S, Fritz K, Ramirez J, Yaman M, et al. (1995) Chronic relapsing pancreatitis from a scorpion sting in Trinidad. Ann Trop Paediatr 15: 285-289.
9. Bartholomew C, McGeeney KE, Murphy JJ, Fitzgerald O, Sankaran H (1976) Experimental studies on the aetiology of acute scorpion pancreatitis. Br J Surg 63: 807-810.
10. Novaes G, de Queiroz AC, das Neves MM, Cardozo C, Ribeiro-Filho L, et al. (1998) Induction of acute and chronic pancreatitis with the use of the toxin of the scorpion *Tityus serrulatus*: experimental model in rats. Arq Gastroenterol 35: 216-22.
11. Ismail M, Fatani AJ, Dabees TT (1992) Experimental treatment protocols for scorpion envenomation: a review of common therapies and an effect of kallikrein-kinin inhibitors. Toxicon 30: 1257-1279.
12. Isbister GK, Bawaskar HS (2014) Scorpion envenomation. N Engl J Med 371: 457-463.
13. Benmosbah M, Guegueniat P, Mayence C, Egmann G, Narcisse E, et al. (2013) Epidemiological and clinical study on scorpionism in French Guiana. Toxicon 73: 56-62.
14. Hommel D, Hulin A, Lourenço WR (2000) Accident scorpionique létal par *Tityus cambreigi* Pocock: À propos d'un cas en Guyane Française. Concours medical: (Paris) 122: 481-484.
15. Mimeau E, Chesneau P (2006) Fauna attacks in French Guiana: retrospective 4-year analysis. Med Trop 66: 69-73.