

Acute Myopia Induced by Topiramate Plus Phentermine for the Treatment of Obesity

Jong-Su Park, Sung-Woo Lee*, Su-Jin Kim and Yun-Sik Hong

Department of Emergency Medicine, College of Medicine, Korea University, Seoul, Korea

Abstract

Topiramate (TPM) is currently used for the treatment of epilepsy, migraine prophylaxis, bipolar diseases, and post-traumatic stress disorders. Recent studies reveal that a low-dose combination of Phentermine plus controlled-release Topiramate (PHEN/TPM CR) as an adjunct to lifestyle modification reduces body weight in obese and overweight adults without significant side effects. We are reporting the case of an overweight young girl with acute progressive myopia due to topiramate, which was being used to treat her obesity.

Introduction

Topiramate (TPM) is currently used for the treatment of epilepsy, migraine prophylaxis, bipolar diseases, and post-traumatic stress disorders [1,2]. The best known and most common ophthalmic complication of TPM is the acute onset of ciliochoroidal effusion syndrome [1]. Recently, Topiramate (TPM) plus phentermine in conjunction with lifestyle modification may provide a well-tolerated and effective option for the sustained treatment of obesity complicated by cardiometabolic disease without significant adverse effects compared to the control groups [3,4]. We are reporting the case of an overweight young girl with acute progressive myopia due to topiramate, which was being used to treat her obesity.

Case Report

A 14-year-old girl complaining of acute bilateral blurred vision since the previous day was admitted to the emergency department. Her visual acuity had previously not necessitated corrective eyewear. She was overweight; her height was 159cm and her weight was 60kg (body mass index = 23.7). She had visited a local family medicine clinic for obesity management three days ago and had been prescribed topiramate 25mg, phentermine 15mg and fluoxetine 10mg once a day to reduce her body weight. She had been taking the drugs for two days before the onset of acute blurred vision. She did not show any noticeable findings on the initial physical examination, nor did she have any history relevant to her symptoms. Her blurred vision was therefore thought to be drug-induced.

On ophthalmic examination, both pupils were normal and

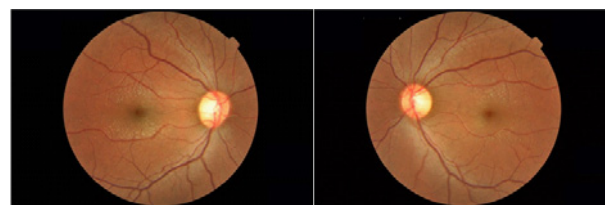


Figure 1: Fundus photography of both eyes showing edematous maculae.

bilaterally reactive to light. Extraocular muscle movement was fully intact. Uncorrected visual acuity was 0.02, oculus dexter(OD)/0.04, oculus sinister(OS). Automated refraction revealed bilateral myopia with spherical equivalents of -10.5-diopters (D), OD/ -10.0 D, OS. Slit-lamp examination revealed no conjunctival injection, a clear cornea, and shallow and clear anterior chambers (anterior chamber depth: 2.19mm, OD/2.30mm, OS). Intraocular pressures were bilaterally measured at normal values (13mmHg, OU) (Table 1). The color vision test was also normal. Fundoscopic examination showed macular striae radiating from the fovea and a cellophane-like reflex (Figure 1). Optical Coherence Tomography (OCT) revealed undulating profiles with congruent retinal and choroidal layers plicae (Figure 2). Macular striae on fundoscopic examination and undulating profiles on OCT images were interpreted as a result of an effusion syndrome confined to the macular choriocapillaris. She was diagnosed with topiramate-induced myopia. The topiramate was discontinued immediately and cycloplegics (atropine) was administered during 3days. The patient followed up with her ophthalmologist. Ten days later her visual acuity returned to normal and she had no lasting visual complaints. All ocular changes had disappeared (Table 1).

		Uncorrected VA	Refraction	Anterior chamber depth (mm)	IOP (mmHg)	Macular edema
6 month ago (at local clinic)	OD	1.0				
	OS	1.0				
presentation	OD	0.02	-10.50D (1.0)	2.19	13	Slightly
	OS	0.04	-10.00D (1.0)	2.30	13	Slightly
1day later	OD	0.15	-1.50D(0.8) [†]	3.56	12	
	OS	0.2	-1.50D(0.8) [†]	3.61	12	
3days later	OD	0.7	+0.25D(0.8) [†]	3.66	13	
	OS	0.7	+0.25D(0.8) [†]	3.70	13	
10days later	OD	1.0	-0.25D(1.0)	Deep	14	Absent
	OS	0.9	-0.25D(1.0)	Deep	14	Absent

[†]: The result was cycloplegic refraction

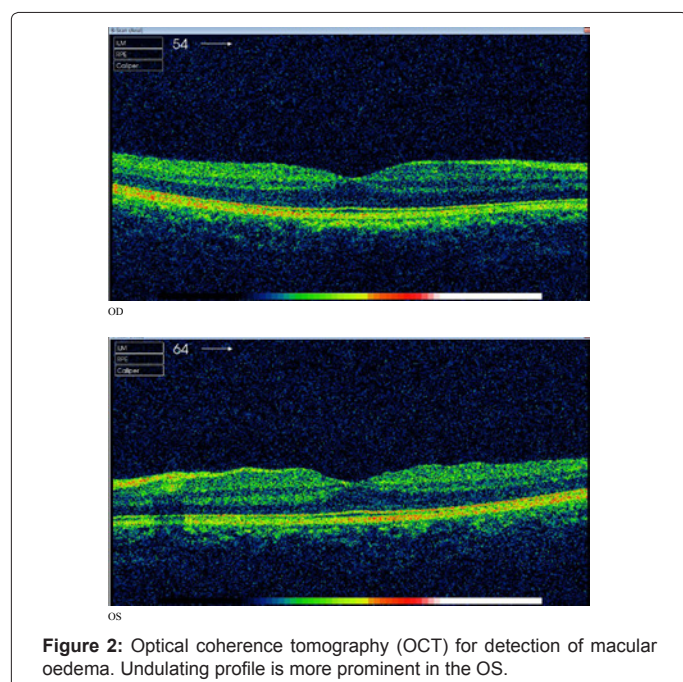
Table 1: Clinical and Ocular examination parameters at presentation and 10 days after cessation of topiramate.

*Corresponding author: Sung-Woo Lee, Department of Emergency Medicine, College of Medicine, Korea University, 126-1, 5-ga, Anam-dong, Sungbuk-gu, Seoul, Korea, 136-705, Tel: 82-2-920-5408; Fax: 82-2-920-5269; E-mail: kuedlee@korea.ac.kr

Received October 11, 2012; Accepted October 26, 2012; Published October 29, 2012

Citation: Park JS, Lee SW, Kim SJ, Hong YS (2012) Acute Myopia Induced by Topiramate Plus Phentermine for the Treatment of Obesity. J Clin Toxicol 2:148. doi:10.4172/2161-0495.1000148

Copyright: © 2012 Park JS, et al. This is an open-access article distributed under the terms of the Creative Commons Attribution License, which permits unrestricted use, distribution, and reproduction in any medium, provided the original author and source are credited.



Discussion

Recent studies [3,4] reveal that a low-dose combination of Phentermine plus controlled-release Topiramate (PHEN/TPM CR) as an adjunct to lifestyle modification reduces body weight in obese and overweight adults. These studies did not show any significant adverse effects compared to the control groups. However, it should be noted that several other studies [1,2,5,6] hypothesized that topiramate may induce acute myopia. According to a Food and Drug Administration report [7], the prevalence of ciliochoroidal effusion syndrome is three per 100,000 of all TPM consumers. Symptoms typically occur within one month of topiramate therapy initiation. In contrast to primary narrow-angle glaucoma, which is rare under 40 years of age, secondary angle closure glaucoma associated with topiramate has been reported in pediatric patients as well as adults.

In the previous review [1], transient TPM-induced myopic shift (TiPM) causes acute transitory blurred vision that spontaneously resolves after drug cessation. On the other hand, TPM-induced Angle Closure Glaucoma (TiACG) can be refractory to ordinary ocular hypotensive drugs (whether topical or systemic), leading to ocular complications such as cataract, uveitis, and even permanent visual loss. TPM-induced Angle Closure Glaucoma (TiACG). Although the exact mechanism remains unclear, topiramate, an oral sulphamide derivative medication, is known to cause ciliochoroidal effusion, which leads to forward rotation of the ciliary body and displacement of the lens-iris diaphragm, with resultant acute angle closure glaucoma and myopic shift [8,9]. In most cases of TiACG, symptoms resolved soon after cessation of the drug. Topical timolol, dorzolamide, brimonidine, and oral or intravenous acetazolamide were found to be the most suitable ocular hypotensive drug following the discontinuation of TPM [1]. Cycloplegics are effective in reducing IOP since they cause retraction of the ciliary processes [10]. Other treatments (topical steroids and laser iridotomy, choroidal drainage, etc.) are considered in the cases of refractory TiACG.

Other topiramate ocular side effects were reported in the previous case reports. TPM-induced ocular inflammatory reactions [11], retinal side effects [12], visual field defects were reported [13]. Similar to this case, several case reports reveal topiramate-induced maculopathy [14-16]. Untreated maculopathy may cause severe and irreversible disorder if topiramate is not promptly discontinued.

In conclusion, general physicians will have to be aware of these potential complications. Furthermore, it is essential for patients to be educated and warned when prescribed topiramate for the treatment of obesity.

References

1. Abtahi MA, Abtahi SH, Fazel F, Roomizadeh P, Etemadifar M, et al. (2012) Topiramate and the vision: a systematic review. *Clin Ophthalmol* 6: 117-131.
2. Caglar C, Yasar T, Ceyhan D (2012) Topiramate induced bilateral angle-closure glaucoma: low dosage in a short time. *J Ocul Pharmacol Ther* 28: 205-207.
3. Gadde KM, Allison DB, Ryan DH, Peterson CA, Troupin B, et al. (2011) Effects of low-dose, controlled-release, phentermine plus topiramate combination on weight and associated comorbidities in overweight and obese adults (CONQUER): a randomised, placebo-controlled, phase 3 trial. *Lancet* 377: 1341-1352.
4. Garvey WT, Ryan DH, Look M, Gadde KM, Allison DB, et al. (2012) Two-year sustained weight loss and metabolic benefits with controlled-release phentermine/topiramate in obese and overweight adults (SEQUEL): a randomized, placebo-controlled, phase 3 extension study. *Am J Clin Nutr* 95: 297-308.
5. Cereza G, Pedrós C, Garcia N, Laporte JR (2005) Topiramate in non-approved indications and acute myopia or angle closure glaucoma. *Br J Clin Pharmacol* 60: 578-579.
6. Chen TC, Chao CW, Sorkin JA (2003) Topiramate induced myopic shift and angle closure glaucoma. *Br J Ophthalmol* 87: 648-649.
7. MEDICATION GUIDE TOPAMAX® (TOE-PA-MAX) (topiramate) Tablets and Sprinkle Capsules.
8. Chalam KV, Tillis T, Syed F, Agarwal S, Brar VS (2008) Acute bilateral simultaneous angle closure glaucoma after topiramate administration: a case report. *J Med Case Rep* 2: 1.
9. Craig JE, Ong TJ, Louis DL, Wells JM (2004) Mechanism of topiramate-induced acute-onset myopia and angle closure glaucoma. *Am J Ophthalmol* 137: 193-195.
10. van Issum C, Mavranakas N, Schutz JS, Shaarawy T (2011) Topiramate-induced acute bilateral angle closure and myopia: pathophysiology and treatment controversies. *Eur J Ophthalmol* 21: 404-409.
11. Jabbarpoor Bonyadi MH, Soheilian R, Soheilian M (2011) Topiramate-induced bilateral anterior uveitis associated with hypopyon formation. *Ocul Immunol Inflamm* 19: 86-88.
12. Ozturk BT, Genc E, Tokgoz M, Kerimoglu H, Genc BO (2011) Ocular changes associated with topiramate. *Curr Eye Res* 36: 47-52.
13. Di Legge S, Bruti G, Di Piero V, Lenzi G (2002) Topiramate versus migraine: which is the cause of glaucomatous visual field defects? *Headache* 42: 837-838.
14. Gualtieri W, Janula J (2012) Topiramate maculopathy. *Int Ophthalmol*.
15. Beyenburg S, Weyland C, Reuber M (2009) Presumed topiramate-induced maculopathy. *Epilepsy Behav* 14: 556-559.
16. Tsui I, Casper D, Chou CL, Tsang SH (2008) Electronegative electroretinogram associated with topiramate toxicity and vitelliform maculopathy. *Doc Ophthalmol* 116: 57-60.