

Accidental Intra Arterial Injection of Ephedrine: What about the Treatment with Nitroglycerin?

Sergeja Kozar^{1*} and Goran Kurnik²

¹Department of Anaesthesiology and Intensive Therapy, University Medical Centre Ljubljana, Ljubljana, Slovenia

²Department of Anaesthesiology and Intensive Therapy, General Hospital Novo mesto, Novo mesto, Slovenia

*Corresponding author: Sergeja Kozar, Department of Anaesthesiology and Intensive Therapy, General Hospital Slovenj Gradec Slovenj Gradec, Slovenia, Tel: +38640800090; E-mail: sergeja.kozar@gmail.com

Received date: Feb 09, 2015, Accepted date: Feb 24, 2015, Published date: Feb 28, 2015

Copyright: © 2015 Kozar S, et al. This is an open-access article distributed under the terms of the Creative Commons Attribution License, which permits unrestricted use, distribution, and reproduction in any medium, provided the original author and source are credited.

Abstract

Accidental intra-arterial (IA) injection of drugs in the perioperative setting is fortunately a rare event, but it can cause severe extremity ischaemia, which can result in significant morbidity due to tissue necrosis. There have been many articles reported about inadvertent intra-arterial injections of various drugs over the last decades.

However, we found none about the unintentional IA injection of ephedrine, so we present the following case.

Keywords: Ephedrine; Intra-arterial injection; Treatment; Nitroglycerin

Introduction

Ephedrine is a sympathomimetic that has both, a direct (α , β 1 and β 2 receptor agonists) and an indirect (release of norepinephrine from presynaptic nerve terminals and monoamine oxidase inhibition) mechanisms of action. It is a safe and widely used drug in the daily anesthesia practice to prevent or treat hypotension resulting from sympathetic blockade during regional anesthesia or from the effects of general anaesthesia. Ephedrine sulphate injection is manufactured for subcutaneous, intramuscular and intravenous administration [1].

Case report

A 66-year old right handed female, with medical history of arterial hypertension and allergy to nimodipine, was scheduled for embolisation with micro-coils due to cold aneurysm of anterior communicating artery.

She had no history of smoking, hyperlipidemia or problems in terms of peripheral vascular disease.

Initially, patient received two intravenous cannulas (G18) preoperatively. Following Allen's test (as according to local protocol), an 20 G arterial cannula (BD Arterial Cannula, Becton Dickinson Critical Care Systems Pte Ltd) was easily inserted in the left radial artery for continuous blood pressure monitoring. The catheter was flushed with standard normal saline solution with heparin (1 IU/ml) and connected to a pressure transducer, showing normal arterial waveform on the monitor. Induction of general anaesthesia was performed using propofol, remifentanyl and rocuronium.

Total intravenous anaesthesia (propofol, remifentanyl) with intermittent boluses of rocuronium was chosen for the maintenance.

Few minutes after induction, drop in arterial pressure was detected. Colloids were used for primary treatment, however the hypotension persisted. A decision to treat it with 10 mg of ephedrine (2 ml) was

made. A member of the anaesthesia team accidentally injected the solution into the artery line. The left hand became colder and slightly paler as compared to the right one. Pulse oximeter, placed on the left index finger, showed low quality pulse signal and still adequate oxygen saturation. This mistake was immediately noticed, arterial line was disconnected and catheter flushed with normal saline with heparin. After reconnection of the line, there was no regular arterial wave on the monitor. The intra-arterial catheter was left in place and an infusion of 0.9% saline solution (75 ml/h) via catheter was started to maintain patency. An initial loading dose of heparin 5000 IU was given intravenously and the hand was elevated. Meanwhile, the right radial artery was cannulated for blood pressure monitoring, showing normal waveform.

The scheduled procedure was then initiated and approximately half an hour after IA injection of ephedrine, contrast angiography of the left upper limb was made, indicating multiple narrowings of radial artery due to vasospasms with absence of flow distally at the palmar region, which was maintained through a collateral flow from ulnar artery (Figure 1).

The operation lasted for around 3 hours without any surgical complications, meantime acetylsalicylic acid 500 mg intravenously was administered and heparin 1000 IU was repeated every hour as according to local protocol.

Throughout the procedure, the left hand was carefully observed. It was warm and of normal color, pulse oximeter placed on the left index finger showed quality pulse signal and normal oxygen saturation.

After the procedure, angiography of left arm was done again, showing persistent vasospasms of left radial artery with absence of distal blood flow (Figure 2).

An injection of 300 μ g nitroglycerin as a bolus (10 ml of 30 μ g/ml solution) via arterial catheter in the left radial artery was done, followed by contrast through the same catheter after 3 minutes. Angiography was repeated, showing complete restoration of left radial artery flow (Figure 3).

After that, the patient was extubated and transferred to high dependency unit.

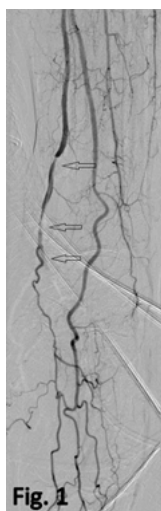


Figure 1: Digital subtraction angiography of the left forearm (intraarterial anterograde contrast injection with angiographic catheter paced in a left axillary artery) immediately after the ephedrine application. Multiple narrowings of radial artery due to vasospasms with absence of flow distally at the palmar region is seen (arrows). Perfusion of palmar region is maintained through a collateral flow from ulnar artery (deep palmar arch).

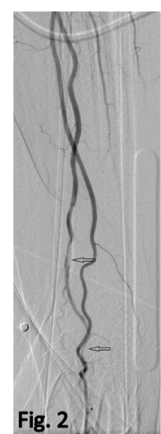

Figure 2: Digital subtraction angiography of the left forearm (with angiographic catheter placed at the same site as on Figure 1.) at the time of termination of operative procedure (approximately after 3 hours). Vasospasms of radial artery with absence of flow distally are still seen (arrows).

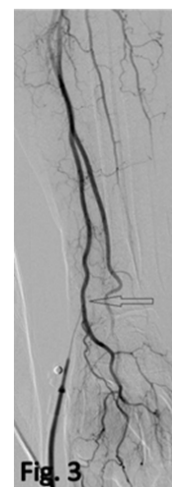

Figure 3: Digital subtraction angiography of the left forearm (intraarterial retrograde contrast injection through the arterial line) after intraarterial nitroglycerin application. Immediate restoration of normal patency of entire radial artery is obvious (arrow).

The recovery was uneventful; the left hand was of appropriate color, painless and warm. Capillary refill, sensation and motoric properties of the hand were normal (Figure 4).

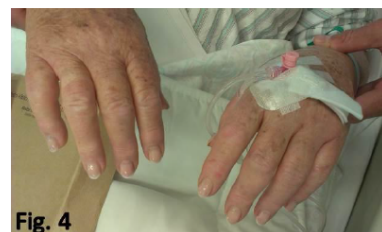

Figure 4: Sensation and motoric properties of the hand.

Arterial catheter with normal saline infusion was removed in the morning on the first day after surgery.

The patient was explained about the IA injection during the procedure and possible late complications. She has also received written instructions on her discharge home.

Discussion

First reports of unintentional IA injections were published more than 60 years ago [2,3].

The estimated incidence of that event is between 1:56 000 to 1:3440 [4].

IA injections can have devastating consequences for the patients, such as limb ischemia, necrosis, gangrene or amputations, so it is very important to be aware of the symptoms, signs and immediate treatment options of such an unpleasant event. The only problem is that no definite guidelines are available so far and that all the

recommendations for management of inadvertent IA injections are more or less anecdotal and based on individual case reports. Treatment of these patients is therefore directed toward symptomatic relief, cessation or reversal of arterial spasm, reestablishment of blood flow, treatment of any sequelae and long-term rehabilitation [4].

When it comes to suspected IA injection, catheter should be left in place for administration of various medication for vasodilatation and spasm relief. Some also suggest continuous infusion of isotonic solution to maintain catheter patency [4], and we have done this in our case.

We have also performed angiography of the affected limb as soon as possible, showing us the extent of blood flow impairment and helping us with treatment decisions [5].

It is known, that complications after accidental IA injections are closely related to the drugs injected, highlighting the pH and osmolarity as the most important factors determining the sequelae [4]. So, according to various investigators, high pH or high osmolarity of injected medication can result in more severe complications; occurring also later in the peri- and postoperative period [4,6]. But that was not the case with ephedrine, which has acidic pH and low tonicity (pH 5.8; osmolarity 310 mOsm/L).

There are also many other different pathophysiological mechanisms described in the literature, causing reflex vasospasm after IA injection, but it seems that thrombosis is the common end point for all IA injections [4]. Thereafter we flushed the catheter with heparinized saline solution and administered 5000 IU of heparin intravenously.

The next objective in management of spasm caused by IA injection is to promote local vasodilatation and relief of arterial constriction. This can be achieved either with extremity sympathectomy (nerve blocks) or applications of various medicines. Local anesthetics, direct arterial vasodilators, thromboxane inhibitors, iloprost, papaverine, thrombolytics and corticosteroids have all been already proposed or used for vasospasm after IA injection [4]. Since emergency IA injections of local anaesthetics have often been successfully performed for spasm relief [7-9], we wanted to use 0.5% lidocaine IA, but because Ghouri et al. [10] warned about possible risks that can worsen already affected blood flow to the limb, we decided to wait and observe the hand. Nicardipine was also effectively used in one case [11], but our patient had known allergy to it.

If the patient had pain and low limb perfusion after the procedure, we would also treat her with an axillary plexus block.

Nitroglycerin is a potent vasodilator, that has effects on arteriolar and venous smooth muscle. This is caused by activation of guanylate cyclase, leading to a local increase in cyclic-guanosine monophosphate. Nitroglycerine is most commonly used for the treatment of angina pectoris, myocardial infarction, acute heart failure, hypertensive crisis and for the maintenance of the desired blood pressure [1]. Many articles also outline its effective intra arterial use [12-14], so based on this data, we decided to treat persisting vasospasm after procedure with the intra-arterial bolus of nitroglycerin, which proved to be very effective.

Conclusion

As according to our knowledge, this is the first case of accidental IA injection of ephedrine. Likewise, despite many therapeutic options already advised, we found no article describing nitroglycerin as a potential medicine for the treatment of arterial spasm following inadvertent IA injection. We think that IA administration of nitroglycerin is very interesting approach in the management of arterial spasm, but more similar cases or studies should be done to approve its use and determine the appropriate dosing.

References

1. Calvey N, Williams N (2008) Principles and Practice of Pharmacology for Anaesthetists. Oxford: Blackwell Publishing.
2. Macintosh RR, Heyworth PA (1943) Intra-arterial injection of pentothal. *Lancet* 2: 571.
3. Cohen SM (1948) Accidental intra-arterial injection of drugs. *Lancet* 2: 409-417.
4. Sen S, Chini EN, Brown MJ (2005). Complications after unintentional intra-arterial injection of drugs: risks, outcomes, and management strategies. *Mayo Clin Proc* 80: 783-795.
5. Rautio R, Keski-Nisula L (2006) Inadvertent intra-arterial drug injections: the role of angiographic and clinical findings. *Acta Radiol* 47: 554-558.
6. Evans JM, Latto IP, Ng WS (1974) Accidental intra-arterial injection of drugs: a hazard of arterial cannulation. 3 Case reports. *Br J Anaesth* 46: 463-466.
7. Samanta S, Samanta S (2013) Accidental intra arterial injection of diclofenac sodium and their consequences: report of two cases. *Anaesth Pain & Intensive Care* 17: 101-102.
8. Hanny-Johner AR, Cartier Faessler V, Walder B (2012) Accidental Intra-Arterial Injection of Alcoholic Chlorhexidine-Complications and their Management. *J Clinic Toxicol* 2: 140.
9. Shukla AN, Ghaffar ZBA, Joshi SC (2009) Inadvertent intra arterial injection of Rocuronium: A case report. *The Internet Journal of Anesthesiology*.
10. Ghouri AF, Mading W, Prabaker K (2002) Accidental intraarterial drug injections via intravascular catheters placed on the dorsum of the hand. *Anesth Analg* 95: 487-491.
11. Boudaoud S, Jacob L, Lagneau F, Payen D, Servant JM, et al. (1993) Successful treatment of vasospastic acute ischaemia with intra-arterial nicardipine. *Eur J Anaesthesiol* 10:133-134.
12. Stoeckelhuber BM, Suttman I, Stoeckelhuber M, Kueffer G (2003) Comparison of the vasodilating effect of nitroglycerin, verapamil, and tolazoline in hand angiography. *J Vasc Interv Radiol* 14: 749-754.
13. Dharma S, Shah S, Radadiya R, Vyas C, Pancholy S, et al. (2012) Nitroglycerin Plus Diltiazem Versus Nitroglycerin Alone for Spasm Prophylaxis with Transradial Approach. *J Invasive Cardiol* 24: 122-125.
14. El-Zammar ZM, Latorre JG, Wang D, Satyan S, Elnour E, et al. (2012) Intra-arterial vasodilator use during endovascular therapy for acute ischemic stroke might improve reperfusion rate. *Ann N Y Acad Sci* 1268: 134-140.