

## A Rare Case of Hydronephrosis Secondary to an Intra-abdominal Haematoma in a Patient with Marfan's Syndrome

Luke Stroman\*, Harikesh Kaneshayogan and Evangelos Mazaris

Department of Urology, St. Mary's Hospital, Paddington, London

### Abstract

A patient with Marfan's Syndrome and type B aortic dissection presented to an academic teaching hospital with sudden onset left loin to groin pain and haemodynamic instability. Her INR was raised at 9.3 and haemoglobin had dropped from 126 to 106 g/L. CT abdomen revealed unilateral left hydronephrosis secondary to ureteric compression by an 11.8×7.0×8.6 cm retroperitoneal haematoma originating from the left iliopsoas. The haematoma was managed conservatively with transfusion of fresh frozen plasma and strict bed rest. A left retrograde uretric JJ stent was placed without complication and she was discharged from hospital eight days after presentation.

**Keywords:** Hydronephrosis; Marfan's; Iliopsoas rupture; Haematoma

### Case Report

A 56 year-old lady presented with a 24 hour history of sudden onset intense burning left loin to groin pain radiating down her left leg, with associated nausea and vomiting. She was passing good amounts urine with no urinary symptoms of note. Bowel habit was regular. She was known to have Marfan's syndrome, and a complex history of cardiothoracic surgery including a type A aneurysm repair and aortic arch repair 25 years previously; mechanical aortic valve replacement requiring warfarinisation 5 years previously; and a type B aortic aneurysm (Figure 1) requiring distal aortic arch and descending thoracic aorta replacement 2 years previously.

On examination she had left loin tenderness with no peritonism and no masses palpable. All peripheral pulses were present and equal. Chest was clear. Blood pressure was 114/71, heart rate 80, regular and had temperature of 36.5°C. Urinalysis showed only trace of blood. Nitrites, protein and leucocytes were negative. Her INR was raised at 9.3 and haemoglobin 12.6 g/L. White cell count was  $20.2 \times 10^9/L$ . Creatinine was 55  $\mu\text{mol/L}$ , urea 3.4 mmol/L. A repeat blood test after 4 hours showed a drop in haemoglobin to 106 g/L.

A leaking aortic dissection was initially suspected and CT aortic angiogram performed. In the left retroperitoneum extending down to the left groin around the common femoral and superficial femoral artery, a large heterogenous mass was visualised, consistent with acute haematoma. Dilatation of the left renal pelvis and upper ureter was seen related to the left retroperitoneal haematoma.

The patient was initially transferred to a high dependency unit for strict monitoring of blood pressure, haemoglobin and renal function. Her raised INR was reversed with three units of fresh frozen plasma.

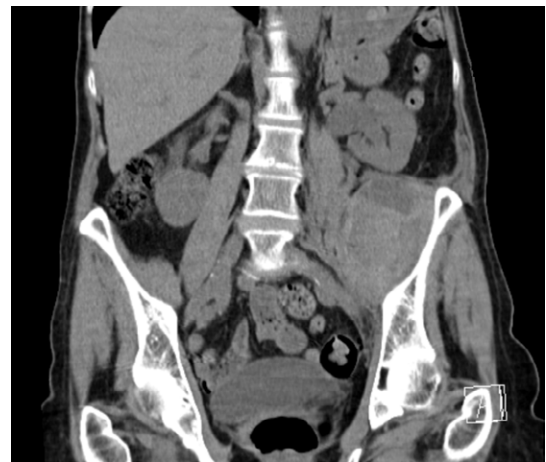Following discussion at uro-radiology multi-disciplinary team meeting it was decided that the haematoma was caused by acute bleeding from a blood vessel within the iliopsoas muscle with secondary ureteric impingement, resulting in hydronephrosis (Figure 1). There was no concomitant tracking of haematoma from previous aortic dissection (Figures 2 and 3).

Decision was made to manage the haematoma conservatively. Once her INR was adequately reduced to 1.5, a left retrograde uretric double J stent was placed without complication. The patient was discharged eight days following admission. The patient remained asymptomatic with no flank pain, indicative of non expanding haematoma. Haemoglobin and renal function were measured and continued to be within normal limits. Due to multiple CT scans on admission it was

decided that follow-up CT scan would be delayed until 6 months to minimise further exposure to radiation.

### Discussion

Marfan's syndrome is an autosomal dominant connective tissue disorder with many associations including aortic aneurysm or dissection, aortic or mitral valve prolapse and spontaneous pneumothorax. Marfan's syndrome is characterised by mutations in gene FBN-1. Glycoprotein fibrillin-1 is encoded by FBN-1 and contributes to formation of connective protein elastin and extracellular matrix. Tissue in which elastin is abundant such as blood vessels are commonly affected by Marfan's syndrome due to altered elasticity, resulting in aneurysm and rupture.



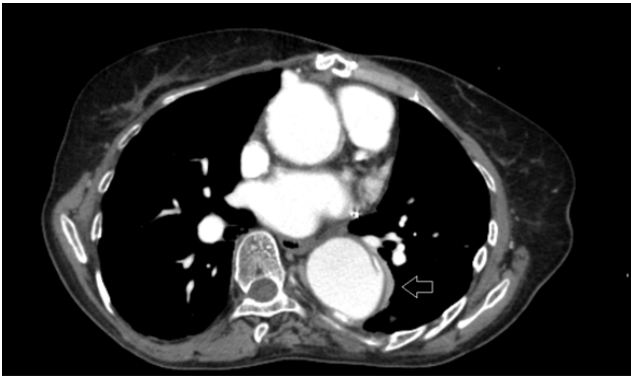
**Figure 1:** A coronal view of the left iliopsoas haematoma causing hydronephrosis.

**\*Corresponding author:** Luke Stroman, Senior House Officer, Department of Urology, St. Mary's Hospital, Paddington, London, UK, Tel: 44 20 3312 666; E-mail: [stromanl@doctors.org.uk](mailto:stromanl@doctors.org.uk)

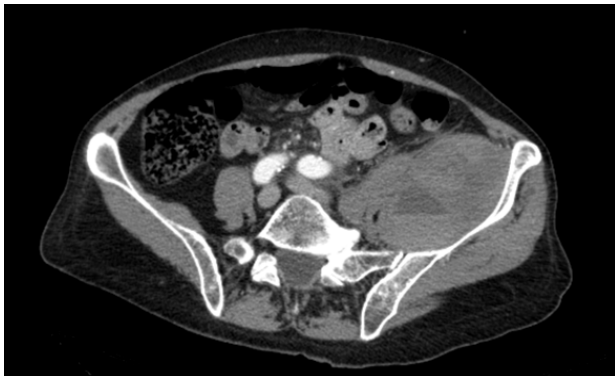**Received** January 20, 2014; **Accepted** February 21, 2014; **Published** February 24, 2014

**Citation:** Stroman L, Kaneshayogan H, Mazaris E (2014) A Rare Case of Hydronephrosis Secondary to an Intra-abdominal Haematoma in a Patient with Marfan's Syndrome. Med Surg Urol 3: 128. doi:[10.4172/2168-9857.1000128](https://doi.org/10.4172/2168-9857.1000128)

**Copyright:** © 2014 Stroman L, et al. This is an open-access article distributed under the terms of the Creative Commons Attribution License, which permits unrestricted use, distribution, and reproduction in any medium, provided the original author and source are credited.



**Figure 2:** A transverse view of contrast CT showing previously diagnosed Stanford Type B thoracic aortic dissection (arrow). The major thoracic branches are not involved.



**Figure 3:** A transverse view of intrabdominal haematoma secondary to iliopsoas rupture seen on contrast CT. No tracking is seen to from aorta to haematoma.

Intra-abdominal haematomas causing secondary hydronephrosis are extremely rare with only a few cases being previously reported in the literature comprising of 5 case reports. Of these the most common cause is a haematoma secondary to bleeding from the rectus sheath [1-6]. Only one case has been reported involving the iliopsoas muscle [6]. It has never been reported in a patient with Marfan's Syndrome. Anticoagulation, or a tendency to bleed such as disseminated intravascular coagulation, can predispose individuals to intra-abdominal bleeding, resulting in haematoma formation and secondary hydronephrosis [4,5].

Diagnosis should be made by combining clinical correlation with CT radiological imaging. Causes of intrabdominal haematoma include retroperitoneal haematoma should include rectus sheath haematoma, inferior epigastric artery rupture and iliopsoas rupture. Risk factors for intrabdominal haematoma include anticoagulation, coagulation disorders, acute increase in intrabdominal pressure, trauma and invasive procedures [6].

Management of this condition involves correcting any haemodynamic instability, followed by reversal of anticoagulation or treatment of bleeding diatheses. Once this is accomplished, decompression of the obstructed urinary system is necessary. The haematoma may be treated conservatively by regular monitoring for improvement in size, or surgically via evacuation of the clot [5,7].

## Conclusion

Intra-abdominal haematomas causing hydronephrosis are very uncommon and more so in Marfan's Syndrome. Due to the higher incidence of aortic aneurysms in Marfan's Syndrome, leaking or ruptured aneurysms are important causes of intra-abdominal haematomas that need to be rapidly diagnosed and treated. A conservative approach to management of iliopsoas haematomas is highly effective in combination with double J stenting to relieve hydronephrosis.

## References

1. Reig Ruiz C1, Vila Barja J, Ahmad Wahab A, Morote Robles J, Soler Roselló A (1992) [Infrequent cause of bilateral obstructive uropathy]. *Actas Urol Esp* 16: 420-421.
2. Colapinto V, Comisarow RH (1979) Urologic manifestations of the iliacus hematoma syndrome. *J Urol* 122: 272-275.
3. Cordero OC, Baldonado RT, Conte SJ, Lopez FA (1974) Rectus sheath hematoma: cause of pelvic pseudotumor. *Urology* 3: 577-580.
4. Dangle PP1, Patel MB, Terán M, Chehval MJ (2013) Obstructive uropathy secondary to rectus sheath hematoma. *W V Med J* 109: 32-33.
5. Toyonaga J1, Tsuruya K, Masutani K, Maeda H, Nakamura K, et al. (2009) Hemorrhagic shock and obstructive uropathy due to a large rectus sheath hematoma in a patient on anticoagulant therapy. *Intern Med* 48: 2119-2122.
6. Kasotakis G (2014) Retroperitoneal and rectus sheath hematomas. *Surg Clin North Am* 94: 71-76.
7. Irisawa M1, Tsukuda S, Amanuma M, Heshiki A, Kuroda I, et al. (2005) Chronic expanding hematoma in the retroperitoneal space: a case report. *Radiat Med* 23: 116-120.