

A Rare Case of Bilateral Circumscribed Posterior Keratoconus in Microcornea Associated with Unilateral Irido-Fundal Coloboma

Rohit Gupta, Jitender Jinagal, Surbhi Khurana, Parul Chawla Gupta and Jagat Ram*

Department of Ophthalmology, Post Graduate Institute of Medical Education and Research (PGIMER), Chandigarh, India

*Corresponding author: Dr. Jagat Ram, Advanced Eye Center, Sector 12, Post Graduate Institute of Medical Education and Research, Chandigarh, India, E-mail: drjagatram@gmail.com

Received date: October 07, 2016; Accepted date: October 24, 2016; Published date: October 27, 2016

Copyright: © 2016 Gupta R, et al. This is an open-access article distributed under the terms of the Creative Commons Attribution License, which permits unrestricted use, distribution, and reproduction in any medium, provided the original author and source are credited.

Abstract

Purpose: To report a rare case of bilateral circumscribed posterior keratoconus in microcornea associated with unilateral irido-fundal coloboma.

Method: A case of bilateral circumscribed posterior keratoconus associated with unilateral irido-fundal coloboma presented to us with complaints of diminution of vision in both eyes since birth. The patient had undergone renal transplant for end stage renal disease secondary to chronic glomerulonephritis. Anterior segment examination including anterior segment optical coherence tomography, fundus evaluation and Scheimpflug imaging was done to confirm and document the findings of bilateral posterior keratoconus and irido-fundal coloboma.

Results: The diagnosis of bilateral posterior keratoconus was made by typical clinical findings and anterior segment optical coherence tomography. Thinning of posterior curvature of cornea was found on slit lamp examination and was confirmed on anterior segment optical coherence tomography (A/S OCT). Since the thinning was localised, diagnosis of bilateral circumscribed posterior keratoconus was made. Unilateral irido-fundal coloboma was documented on anterior segment and fundus photography.

Conclusions: This is the first case report documenting bilateral circumscribed posterior keratoconus along with unilateral irido-fundal coloboma. Further studies are required to look for any association between these two diseases and of these diseases with other ocular as well as systemic anomalies.

Keywords: Posterior keratoconus; Irido-fundal coloboma; Circumscribed posterior keratoconus

Introduction

Posterior keratoconus is a rare ectatic corneal disorder characterised by non-inflammatory thinning of the cornea. It is usually a developmental disorder but some case reports have mentioned trauma as a possible cause of posterior keratoconus too [1]. The thinning of the cornea leads to characteristic cone-like protuberance of the posterior cornea. It is an unusual abnormality of the cornea generally classified as one of the anterior chamber cleavage anomalies [2]. Posterior keratoconus can occur in two forms, generalised or localised, depending upon the curvature of posterior cornea. The generalised posterior keratoconus, also called as keratoconus posticus generalis, is characterized by regular increase of the curvature of the entire posterior cornea. In localised type of posterior keratoconus, also called as keratoconus posticus circumscriptus, there may be single or more, central or paracentral areas of posterior excavation [3]. Corneal stroma remains clear in the generalised posterior keratoconus, whereas, localised stromal opacities, which may be full thickness, may be present over the ectatic area of the posterior surface in the localised type of posterior keratoconus [4].

Posterior keratoconus is characterised by moderate and non-progressive visual loss due to lack of involvement of anterior corneal

surface [5]. Visual loss in this disorder is due to stromal scarring, amblyopia or any co-existing ocular disease [6].

Ocular coloboma is a malformation due to faulty closure of the embryonic fissure, in which there is absence of part of or an entire ocular structure, and may affect iris, ciliary body, choroid, optic nerve or all of the above [7-9].

We did not find any case report of bilateral posterior keratoconus in microcornea which is associated with unilateral coloboma of iris and fundus and we are the first to report such findings.

Material and Methods

A 34-year-old male presented to us with complaints of diminution of vision in both eyes. The decrease of vision was noted to be more in the left eye and was present since childhood. The patient also complained of inward deviation of left eye. He is a known case of type II diabetes mellitus for the past 5 years and hypertensive since 7 months. He was also diagnosed with chronic glomerulonephritis in the past which had progressed to end stage renal disease. He underwent renal transplant 7 months back. Best corrected visual acuity in the right eye was 20/100 and 20/400 in the left eye. Intraocular pressure by non-contact tonometer was 16 mm of Hg in the right eye and 14 mm of Hg in the left eye. Left eye had 15 degrees of esotropia on Hirschberg's test. Anterior segment examination on the slit lamp showed the presence of microcornea (corneal diameters of 10.5 and 10 in the horizontal and vertical meridian respectively), with localized

corneal haze involving central and paracentral cornea in both eyes along with iris coloboma in the left eye (Figures 1A and 1B). Magnified slit examination of the cornea showed indentation and central thinning in the posterior curvature of cornea of both eyes suggestive of posterior keratoconus (Figures 1C and 1D). Since the thinning was localised, circumscribed posterior keratoconus was diagnosed. Right eye was associated with refractive error of +2.50 DS and left eye with astigmatic error of 1.25@180 degrees. A/S OCT showed localised forward protrusion and thinning of central and paracentral area of posterior cornea with normal anterior cornea (Figures 2A and 2B). Scheimpflug imaging (Pentacam) was done to confirm the diagnosis of posterior keratoconus. Four map refractive showed highly significant back elevation in both the eyes. Posterior corneal astigmatism values were very high (5.0 D in right eye and 10.9 D in left eye) (Figures 3A and 3B). Fundus evaluation after pupillary dilatation with 0.8% tropicamide and 5% phenylephrine revealed left eye irido-fundal coloboma, which was sparing the optic disc and macula. Posterior segment examination of the right eye was unremarkable, suggestive of unilateral coloboma (Figures 4A and 4B). Fundus photography (OPTOS wide field photography system) was done for documentation of coloboma.

The localised corneal haze in the central and paracentral area of cornea on slit lamp examination in both eyes confirms the clinical findings of bilateral circumscribed posterior keratoconus in our patient. Since there is also presence of localised thinning of posterior cornea in central region, it further corroborates our diagnosis. Iris coloboma was seen on slit lamp examination in the left eye along with documentation of fundal coloboma on fundus photography of the same eye. Since there is presence of both iris and fundal coloboma in the left eye, final diagnosis of bilateral keratoconus posticus circumscriptus along with unilateral irido-fundal coloboma was made. This is the first case to report both clinical entities viz. bilateral circumscribed posterior keratoconus in microcornea and unilateral irido-fundal coloboma in the same patient. As posterior keratoconus is supposed to be one of the anterior chamber cleavage anomalies and irido fundal coloboma represent anomaly of incomplete closure of optic fissure, the presence of posterior keratoconus and fundus coloboma [9] might suggest a genetic linkage between these two clinical entities and this correlation might be a part of spectrum of syndrome with multiple ocular as well as systemic involvements.

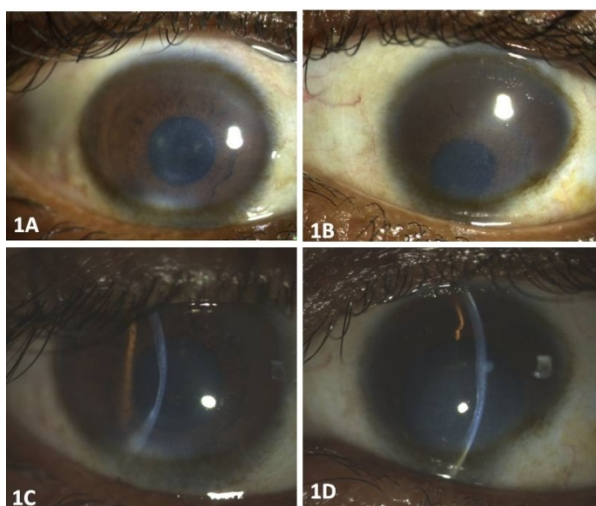


Figure 1: 1A and 1B: Diffuse slit lamp examination showing the presence of microcornea with localized corneal haze involving central and paracentral cornea in both eyes along with iris coloboma in the left eye. **1C and 1D:** Slit examination of the cornea showing indentation and central thinning in the posterior curvature of cornea of both the eyes suggestive of posterior keratoconus.

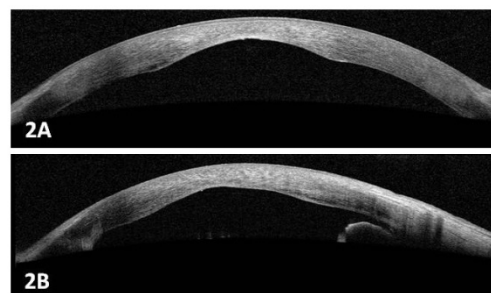


Figure 2: 2A & 2B: Anterior segment Optical Coherence Tomography showing localised forward protrusion and thinning of central and paracentral area of posterior cornea with normal anterior corneal surface.

This case is a diagnostic and management challenge since the clinical findings are very subtle and can be easily missed on slit lamp examination.

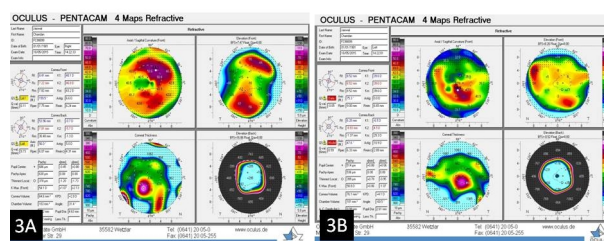


Figure 3: 3A & 3B: Four map refractive (Pentacam) of both the eyes showing highly significant posterior elevation with posterior corneal astigmatism.

Results and Discussion

Posterior keratoconus is a different entity from keratoconus, despite of having similar names [10]. Keratoconus is much more common than posterior keratoconus and is usually bilateral, progressive condition. Posterior keratoconus does not progress to keratoconus, even if steepening of anterior corneal surface occurs. It does not require treatment usually, except in cases involving the visual axis. Associated refractive error can be corrected by glasses. Visual rehabilitation with contact lens can be tried if the patient has irregular astigmatism. Penetrating keratoplasty may be considered in patients with poor vision, even after glasses and contact lens.

Moreover, this is the first case to report bilateral posterior keratoconus and unilateral irido-fundal coloboma in the same patient. Further genetic studies may be helpful in finding out genetic linkage between these clinical entities.

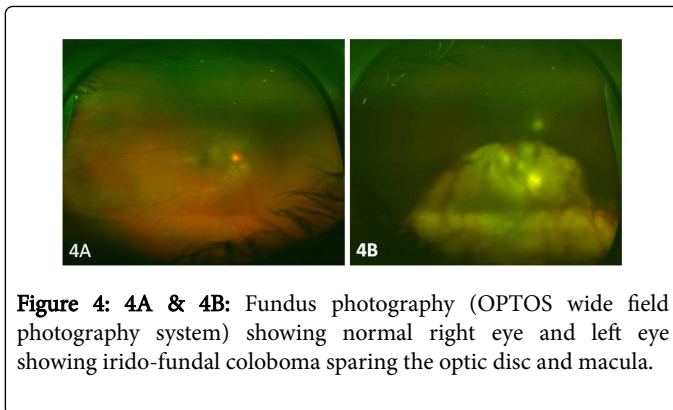


Figure 4: 4A & 4B: Fundus photography (OPTOS wide field photography system) showing normal right eye and left eye showing irido-fundal coloboma sparing the optic disc and macula.

Conflict of Interest

All authors certify that they have no affiliations with or involvement in any organization or entity with any financial interest (such as honoraria; educational grants; participation in speakers' bureaus; membership, employment, consultancies, stock ownership, or other equity interest; and expert testimony or patent-licensing arrangements), or non-financial interest (such as personal or professional relationships, affiliations, knowledge or beliefs) in the subject matter or materials discussed in this manuscript.

References

1. Williams R (1987) Acquired posterior keratoconus *Br J Ophthalmol* 71: 16-17.
2. Mannis MJ, Lightman J, Plotnik DR (1992) Corneal topography of posterior keratoconus *Cornea* 11:351-354
3. Duke-Elder S (1963) Part 2: Congenital deformities. *System of Ophthalmology: Normal and Abnormal Development* 3: 510-511.
4. al-Hazzaa SA, Specht CS, McLean IW, Harris DJ Jr (1995) Posterior keratoconus: case report with scanning electron microscopy *Cornea* 14: 316-320.
5. Karlin DB, Wise GN (1961) Keratoconus posticus. *Am J Ophthalmol* 52: 119-121.
6. Rejdak R, Nowomiejska K, Haszcz D, Jünemann AGM (2012) Bilateral circumscribed posterior keratoconus: visualization by ultrasound biomicroscopy and Slit-Scanning topography analysis. *J Ophthalmol* 2012: 587075.
7. Streeten BW, Karpik AG, Spitzer KH (1983) Posterior keratoconus associated with systemic abnormalities *Arch Ophthalmol* 101: 616-622.
8. Krachmer JH, Rodrigues MM (1978) Posterior keratoconus. *Arch Ophthalmol* 96: 1867-1873.
9. Kumar K, Tanwar M, Naithani P, Insaan R, Garg S, et al. (2011) PAX6 gene analysis in Irido-fundal-coloboma. *Mol Vis* 17: 1414-1419.
10. Vajpayee RB, Sharma N (1998) Association between anterior and posterior keratoconus. *Aust N Z J Ophthalmol* 26: 181-183.