

## A Randomized and Observer Blinded Comparison of Continuous Femoral Block and Fascia Iliaca Compartment Block in Hip Replacement Surgery

Thorsten Möller<sup>1,2</sup>, Sabine Benthaus<sup>2</sup>, Maria Huber<sup>2</sup>, Ingrid Bentrup<sup>2</sup>, Markus Schofer<sup>3</sup>, Leopold Eberhart<sup>2</sup>, Hinnerk Wulf<sup>2</sup> and Astrid Morin<sup>2\*</sup>

<sup>1</sup>Department of Anesthesiology and Intensive Care Medicine, Charité-Universitätsmedizin Berlin, Berlin, Germany

<sup>2</sup>Department of Anesthesiology and Critical Care Medicine, Philipps-University Marburg, Marburg, Germany

<sup>3</sup>Department of Orthopedy and Rheumatology, Philipps-University Marburg, Marburg, Germany

### Abstract

**Background:** Techniques, analgesic effects and functional outcome of continuous femoral nerve and fascia iliaca compartment blocks were compared in patients undergoing hip replacement surgery.

**Methods:** 80 patients were enrolled in this randomized and observer-blinded study. 40 patients received a femoral nerve catheter with a stimulating catheter (FEM group) and 40 patients a fascia iliaca compartment catheter (FIC group). Before surgery, the catheters were placed. 50 mL prilocaine 1% was administered and a continuous infusion of ropivacaine 0.2% was maintained for 24 hours. Postoperative pain management with non-steroidal anti-inflammatory agents was standardized during the first 24 hours. No bolus application of a local anesthetic was allowed during this period.

Intravenous opioide PCA with piritramide (comparable with morphin) was provided for 24 hours, and the patients were instructed to titrate their pain below a level of visual analogue scale of 3. We evaluated the catheter placement time, the time until complete sensory and motor block, the analgesic efficacy and functional outcome with WOMAC Index, Harris Hip Score, Lequesne Score and SF 36 questionnaire.

**Results:** Catheter placement was faster in the FIC group (3 minutes vs. 5 minutes in mean;  $p < 0.05$ ). Time until sensory and motor blockade was faster in the FEM group except for the lateral part of the thigh. No significant difference was noted between the groups regarding median VAS pain values and consumption of piritramide within 24 hours. No differences in functional outcome after 12 and 90 days of surgery could be observed.

**Conclusions:** The fascia iliaca compartment catheter can be placed more quickly than the femoral nerve catheter with the stimulating catheter technique, but onset time of sensory and motor blockade is longer when performing the fascia iliaca compartment technique. Both techniques have equivalent postoperative analgesic efficacy in hip replacement surgery without any difference in functional outcome. In case of contraindications for a classic femoral nerve block, the fascia iliaca compartment block is an equivalent procedure.

**Keywords:** Continuous femoral nerve block; Continuous fascia iliaca compartment block; Hip replacement surgery; Functional outcome; Regional anesthesia; Hip surgery; Postoperative pain management

### Introduction

Pain after hip replacement surgery may potentially hinder postoperative physiotherapy and early mobilisation. Regional anesthesia of the lower limb appears to be effective for postoperative pain control [1] in this setting and it has been shown that the lumbar plexus blockade provides high-quality analgesia [2], as the femoral nerve supplies the anterior hip joint capsule, as well as the proximal femur, the quadriceps, iliacus and pectineus muscles.

The most common approach is the femoral perivascular technique with a peripheral nerve stimulator [3]. Several studies have demonstrated that this approach does not achieve a reliable block of all three nerves (femoral nerve, obturator nerve, lateral femoral cutaneous (LFC) nerve) [2]. The femoral (FEM) block fails mostly in areas supplied by the LFC and the obturator nerve. Capdevila and Seeberger have seen a sufficient anesthesia of the LFC by using the femoral block in only 62% [2] respectively 44% [4]. But the LFC nerve may at least in part be responsible for pain in the incisional area of hip surgery.

An alternative approach to the FEM block is the fascia iliaca compartment (FIC) block. Anesthesia of the LFC is achieved in 90% by using the FIC block [5]. The puncture site is further from the femoral nerve, laterally, and two are perceived when piercing the fascia. Local anesthetic does not only reach the LFC nerve, but also the femoral

nerve because the needle tip and the femoral nerve are located in the same compartment (Figure1). Therefore, the FIC block could provide effective analgesia after hip surgery as an alternative to FEM-block.

No prospective trial has been reported yet comparing the two approaches in hip surgery in regard to procedural technique differences, analgesia and functional outcome.

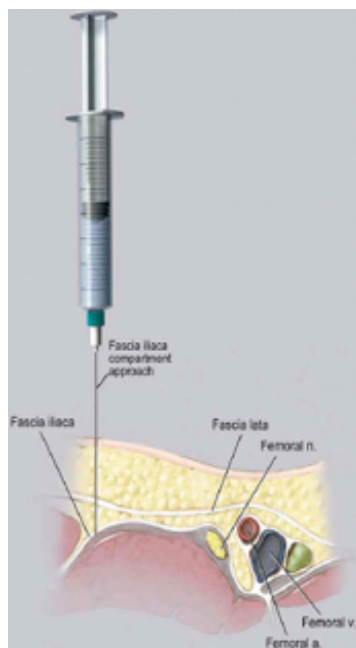
The goal of the study was to verify the assumption that the FIC block is less time-consuming to perform but provides equally effective analgesia compared to the FEM block, even with an ad hoc implementation in the clinical routine, as performing the fascia iliaca compartment block was a new procedure in our department and experience with it was barely existent compared to the perivascular FEM block.

**\*Corresponding author:** Astrid M. Morin, Department of Anesthesiology and Critical Care Medicine, Philipps-University Marburg, Baldingerstrasse, 35033 Marburg, Germany Tel: +49 6421/ 58-65984; Fax: +49 6421/ 58-66996; E-mail: [Astrid.Morin@staff.uni-marburg.de](mailto:Astrid.Morin@staff.uni-marburg.de)

**Received** October 20, 2011; **Accepted** December 01, 2011; **Published** December 06, 2011

**Citation:** Möller T, Benthaus S, Huber M, Bentrup I, Schofer M, et al. (2011) A Randomized and Observer Blinded Comparison of Continuous Femoral Block and Fascia Iliaca Compartment Block in Hip Replacement Surgery. J Anesthe Clinic Res 4:277. doi:10.4172/2155-6148.1000277

**Copyright:** © 2011 Möller T, et al. This is an open-access article distributed under the terms of the Creative Commons Attribution License, which permits unrestricted use, distribution, and reproduction in any medium, provided the original author and source are credited.



**Figure 1:** Schematic representation of the anatomy relevant to the fascia iliaca compartment block.

## Methods

Following approval by the research ethics committee of the medical faculty of the Philipps- University Marburg/Germany (registration number “17/07”, designed on 15<sup>th</sup> May 2007), we obtained written and informed consent from 80 adult patients (ASA I – III) undergoing scheduled unilateral hip replacement surgery under general anesthesia. Exclusion criteria included refusal of the perineural catheter, pregnancy, allergy to local anesthetics, local infection at the puncture site, age below 18 years, and opioid tolerance.

### Preoperative assessment

The day before operation, mobility of the hip and quality of life were examined using the WOMAC (= Western Ontario Mac Master University) Index, Harris Hip Score, Lequesne Score and SF 36 questionnaire (<http://www.sf36.org>).

The WOMAC Index assesses scores for pain, stiffness and functional capacity (0 = optimum, to a maximum value of 240 = worst condition).

Harris Hip Score evaluates the functional hip joint capacity in a range between 0 and 100 (optimal function).

The Lequesne Score is an index of severity for osteoarthritis and can be used to assess the effectiveness of therapeutic interventions. It includes maximum walking distance, activities of daily life, pain or discomfort, and sexual activity. The maximum score is 26, the minimum score is 0. A score of 14 and higher indicates a severe handicap.

The standard SF-36 test evaluates both the physical and mental health domain of patients with maximum values of 100 in each domain, which indicates good health.

All patients were premedicated with 20 mg Dikaliumchlorazepat (Tranxilium®) per os. The patients were randomized to one of the two groups (FEM vs FIC) prior to the procedure by computer generated

randomization and with sealed envelopes. The blocks were performed before induction of general anesthesia by one of four anesthesiologists (T.M., I.B., L.E., or A.M.) with considerable experience in femoral nerve blockade, but no or only limited experience in performing the fascia iliaca compartment blockade (less than 5 blocks before beginning of the study period).

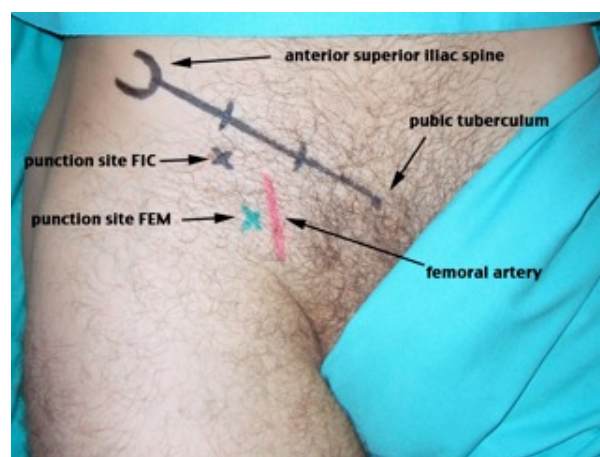
Performing the FEM block we used a StimuCath™ continuous nerve block set by ARROW with a 17 G touhy stimulation needle. The puncture site was 2.5 cm caudal to the inguinal ligament and ≤1 cm lateral to the femoral artery. We used a nerve stimulator Stimuplex® (Braun Melsungen, Germany). After eliciting quadriceps femoris muscle response at 0.3 – 0.5 mA; 2 Hz; 0.1 ms, a 19 G stimulation catheter was inserted and placed under stimulation control and redirected if necessary to obtain or regain a muscle response below 0.8 mA. The catheter was introduced three to five centimeters over the needle-tip.

For the FIC block, we used a KombiPlex B™ catheter set with an 18 G needle and 45° cut (Pajunk, Geisingen, Germany). To identify the puncture site, a line was drawn from the anterior superior iliac spine to the pubic tubercle and divided into three parts. The puncture site was at the junction of the lateral and medial part, and 1 cm caudal of this junction (Figure 2).

The needle was inserted perpendicularly and after 2 clicks (loss of resistance) when penetrating the fascia lata and the fascia iliaca (Figure 1) a catheter was inserted and advanced three to five centimeters. The procedural time required from the first penetration of the skin with the needle until correct catheter placement was defined as catheter placement time. The anesthesiologist rated the feasibility of the procedure on a 4-point Lickert scale (very easy = 8, rather easy = 6, rather difficult = 4, very difficult = 2). The patients rated the ease of the procedure on a VAS 0 - 10 (visual analog scale: 0 = very comfortable; 10 = unbearable).

After negative aspiration, 50 mL prilocaine (Xylonest®) were injected in both blocks over the catheter. This high bolus dose was chosen because the needle position in the FIC block is further away from the nerve and therefore the local anesthetic covers a longer distance to reach the femoral nerve.

After injection, a blinded observer (S.B. or M.H.) assessed the



**Figure 2:** Anatomical landmarks and puncture site of the FEM and the FIC Block.

sensory block with a cold cotton swab in the innervation territories of the femoral and LFC (Figure 3). Motor block was assessed by femoral and obturator nerve function (knee extension and thigh adduction). All assessments were undertaken approximately every two minutes for half an hour.

Sensory block was defined as a complete loss of cold sensation in the nerve territories; motor block was defined as a total paresis (Bromage score grade 4).

Following the final assessment, a continuous infusion pump was connected to the catheter with an infusion rate of 10 mL/h ropivacaine 2 mg/mL (Naropin® 0,2%) for 24 hours, without top ups.

### Intraoperative assessment

Induction of general anesthesia was performed using propofol and fentanyl, the amount at the ease of the anesthetist, maintenance of anesthesia with remifentanyl up to 200µg/h. It was at the ease of the anesthetist to use propofol or desflurane® to maintain anesthesia.

### Postoperative assessment

During the first 24 hours, patients were not mobilized out of bed. Postoperative care was standardized during the first 24 hours. In addition to the local anesthetic via the catheter all patients received a daily oral dose of 3 x 50 mg of diclofenac (in case of contra-indications: 4 x 1 g metamizol). Intravenous PCA (patient controlled analgesia) for 24 hours was provided with piritramide (10 mg morphine is equivalent to 15 mg piritramide), a standard bolus of 2 mg, and a lockout interval of 10 minutes. Patients were instructed to use the PCA in order to relieve pain to a maximum of VAS 3 at rest and during movement (VAS 0 = no pain, VAS 10 = maximal pain). The patients were visited by the two blinded observers (S.B. or M.H.), who assessed piritramide consumption and pain scores with the VAS scoring system at rest and during movement in the postoperative care unit (2 hours

postoperatively), after 24, 48 and 72 hours and before discharge. Patients were asked to rate their maximum pain score during the last observation period. The catheters and the PCA were removed after 24 hours. After catheter removal, the oral medication of diclofenac or metamizol was maintained. Furthermore, patients received oxycodon (Oxygesic®) if necessary.

Patients had to rate their satisfaction of overall pain management on a VAS (0 = not satisfied at all; 10 = very satisfied) before discharge.

### Functional outcome

Mobility of the hip and quality of life were examined using the WOMAC (= Western Ontario Mac Master University) Index, Harris Hip Score, Lequesne Score and SF 36 questionnaire one day before surgery, and at 12 and 90 days after surgery.

### Power calculation and statistical analysis

The primary goal of the study was to verify the assumption that the FIC block is less time-consuming to perform than the FEM block with a stimulating catheter technique under the assumption that both techniques provide equally effective analgesia [5]. Power calculation was based on the difference in procedure time.

Previous data showed that the average time to complete the FEM block was 5 minutes with a standard deviation of 5 [6]. Halvening the time and the variance performing the FIC block was considered clinically relevant. To detect this improvement with a power of 80% and a type I error of 5%, 80 patients (40 per group) were required. Sample size calculation was performed with PASS 2002 (Number Cruncher Statistical Systems, Kaysville, USA).

To maintain allocation concealment, randomization was performed after patients' arrival in the preoperative holding area, immediately before performing the block. Sealed opaque envelopes containing computer generated random numbers were used to determine group allocation.

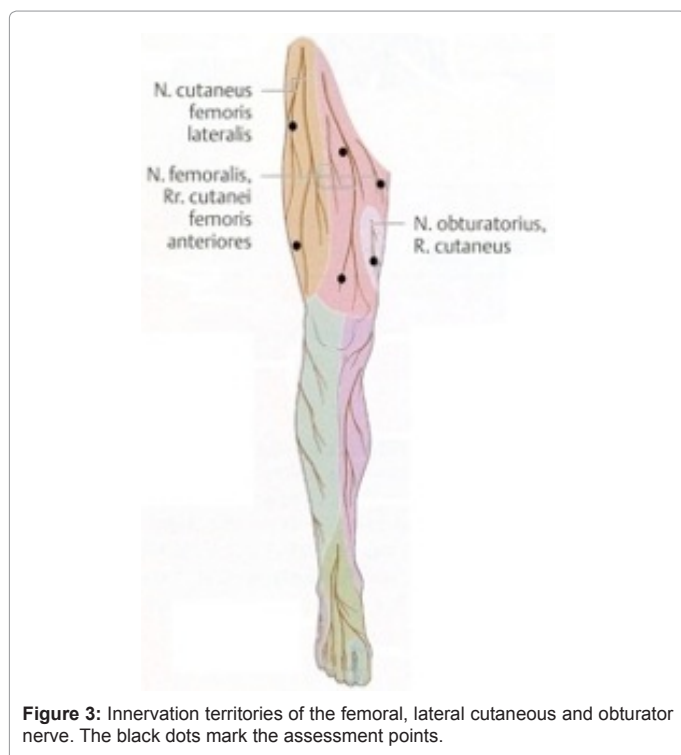
Results are presented in general with mean and standard deviation. To calculate differences between groups, the Mann-WhitneyU-Test was used.

### Results

During the observation period 129 patients with osteoarthritis were treated with primary hip replacement surgery. 17 patients could not be included because they received spinal anesthesia and 13 refused to have a catheter. 11 refused to take part in the trial. Eight of the 88 patients had to be excluded because surgery was cancelled or the study doctors were not available to perform the block on the day of surgery. 80 patients were assigned to one of the groups (FEM n=40; FIC n=40) (Figure 4). Patients in the groups did not differ significantly with regard to age, weight, body mass index (BMI), gender, type of hip replacement or intraoperative fentanyl consumption (Table 1).

### Preoperative results

Catheter placement time from needle insertion until definite catheter placement was longer in the FEM group (5 versus 3 minutes in mean). Patients felt comfortable with the procedure of catheter placement in both groups, measured on a VAS 0 - 10 (0 = very comfortable; 10 = unbearable). The difficulty of catheter placement was rated by the study doctors as "rather easy" in both groups (4-point Likert scale: very easy = 8, rather easy = 6, rather difficult = 4, very difficult = 2) (Table 2).



**Figure 3:** Innervation territories of the femoral, lateral cutaneous and obturator nerve. The black dots mark the assessment points.

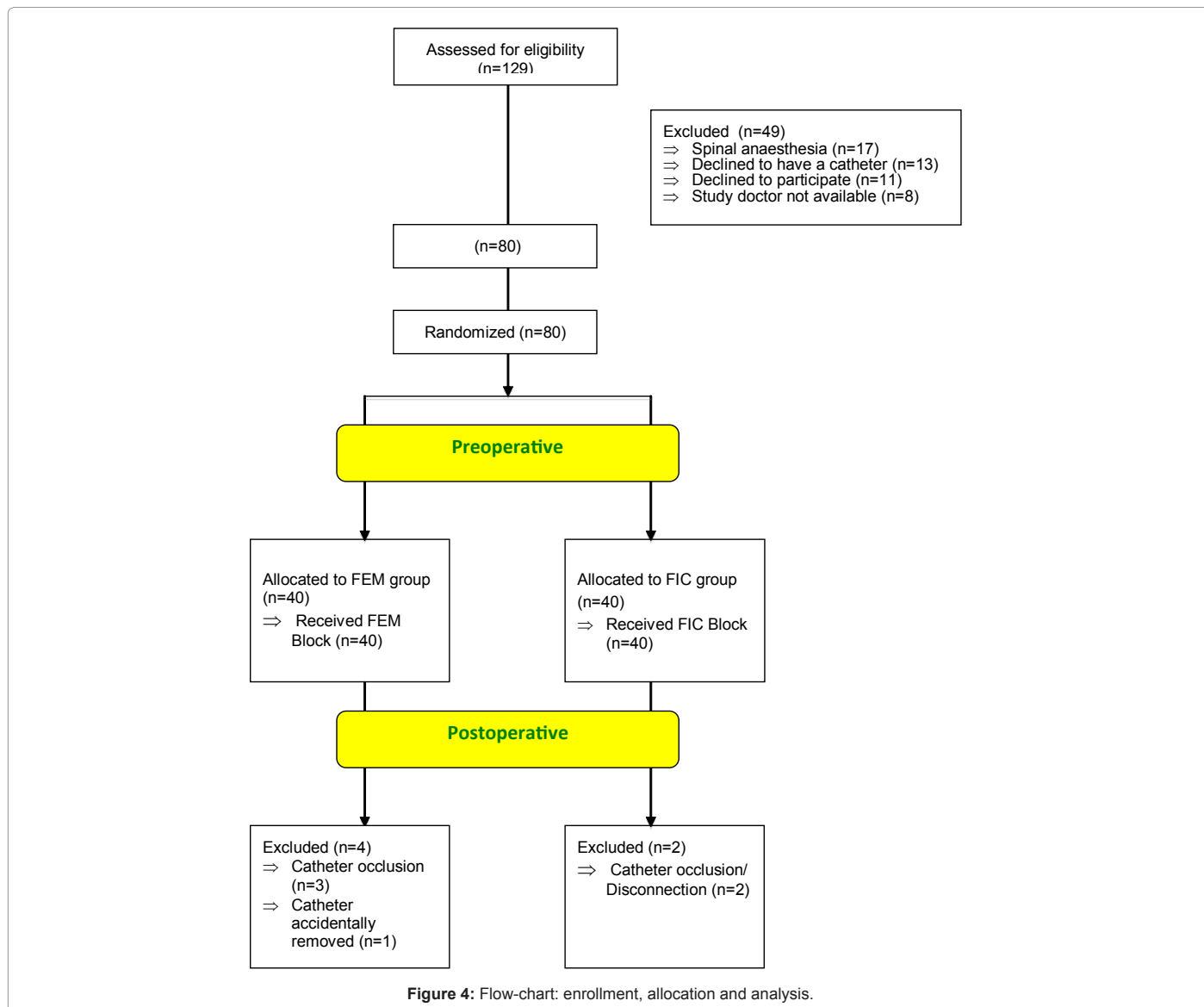


Figure 4: Flow-chart: enrollment, allocation and analysis.

The time until complete sensory and motor block after injection of the bolus dose (50 mL prilocaine 1%) differed in both groups (Table 3). The sensory block in the anterior aspect of the thigh was 2 min faster in the FEM group in mean, but equal at the lateral aspect in both groups. Loss of knee extension was significantly faster in the FEM group (difference of 3 minutes in mean). Loss of thigh adduction was faster in the FEM group as well, but without statistical significance (Table 3).

### Postoperative results

Six patients had to be excluded from the study (FEM = 4, FIC = 2) in the postoperative period due to catheter disconnection or catheter occlusion over a period of two to 4 hours, and one catheter was accidentally removed during operation (Figure 4).

Postoperative piritramide consumption via PCA within the first 24 hours differed between the study groups, but without statistical significance (FEM group 20 mg versus FIC group 26 mg in mean) (Table 2).

Postoperative pain scores at rest and during movement on the first

day, and during physiotherapy exercise on the following days did not differ between the groups at any observation period (Table 4).

Patient satisfaction (VAS 0 = not satisfied at all, 10 = very satisfied) with overall pain management, measured before discharge, was very good in both catheter groups (FEM = 10, FIC = 10).

### Functional outcome

The Lequesne questionnaire showed pre-surgery values of 16 (FEM) and 17 (FIC). The post-surgery values were 16 after 12 days and 8 after 90 days in the FEM group; 15 and 9 in the FIC group. Pre-surgery and follow-up values were statistically not different between the groups.

The WOMAC index showed pre-operative values of 120 (FEM) and 140 (FIC). 12 days postoperatively the values improved in both groups (FEM: 98; FIC: 103) and again after 90 days postoperative (FEM: 50; FIC: 62). The values were statistically not different between the groups.

Pre-surgery values of the Harris Hip Score were 57 in the FEM group and 51 in the FIC group. Postoperative function improved in



both groups 12 days after (FEM: 66; FIC: 69) and 90 days after surgery (FEM: 83; FIC: 83), but again without significant differences between the groups.

The standard SF-36 test in the physical health domain pre-surgery (FEM: 26; FIC: 26) did not improve 12 days after surgery (FEM: 23; FIC: 24) but in the 90 days follow-up (FEM: 49; FIC: 37).

In the preoperative mental health domain, we found a somewhat higher value in the FEM group (58) compared to the FIC (47). 12 days after surgery mental health improved, but no differences could be seen between the two groups (FEM: 58; FIC: 56). Interesting findings can be seen in the 90 days follow-up, when the values in both groups declined (FEM: 51, FIC: 52). A decline by more than 5 points is considered to be clinically relevant.

Discharge from hospital did not differ between groups, it was 8 days in mean in both groups.

### Discussion

In this study, we demonstrated that a continuous fascia iliaca compartment blockade is as effective as a femoral nerve blockade with regard to pain control after hip replacement surgery, measured by piritramide consumption via an intravenous PCA. This finding is especially remarkable as performing the fascia iliaca compartment block was a new procedure in our department and experience with it was

	FEM (n = 40)	FIC (n = 40)	p - values
Gender (male/female)	23/17	21/19	n.s.
Age (y)	64 (13)	62 (15)	n.s.
Body mass index (kg/m <sup>2</sup> )	28 (5)	29 (5)	n.s.
Intraoperative fentanyl consumption (mg)	0.6 (0.2)	0.6 (0.2)	n.s.
TEP non cemented	17 (42.5%)	18 (45%)	n.s.
TEP cemented	7 (17.5%)	4 (10%)	n.s.
TEP Hybrid	12 (30%)	15 (37.5%)	n.s.
Cap Prothesis	4 (10%)	3 (7.5%)	n.s.

**Table 1:** Biometrical data (FEM: Femoral nerve group; FIC: Fascia iliaca group; TEP: Total endoprothesis; n.s.: not statistically significant). Values are expressed as mean (standard deviation) or n (%).

	FEM (n = 40)	FIC (n = 40)	p - values
Catheter placement time (minutes)	5.2 (3.3)	3.1 (3.6)	0.0001*
Patients satisfaction with catheter placement (VAS 0 = very comfortable; VAS 10 = unbearable)	3.1 (1.9)	2.7 (2)	0.22
Study-Doctors evaluation of difficulty of catheter placement (8=very easy, 6=rather easy, 4=rather difficult, 2=very difficult).	5.6 (1.8)	5.6 (2)	0.84
Piritramide consumption during 24 hours (mg) (FEM n = 36, FIC n = 38)	20.3 (18)	26.3 (18.9)	0.26

**Table 2:** Main results. Values are expressed as mean (standard deviation) or n (%). \*Statistically significant (<0.05).

barely existent compared to the perivascular FEM block. The catheter placement time was faster in the FIC than in the FEM group. But we have to acknowledge that the technique of placing a stimulating catheter takes longer than simply placing the needle with a nerve stimulator and then placing the catheter blindly without further stimulation. Probably there would have been no significant time difference if we had compared the FIC block with the classical FEM block technique with no stimulating catheter. Furthermore, the onset time of the sensory and motor blockade was shorter in the FEM group, so there was no overall time saving with the FIC block.

Multiple studies about the fascia iliaca compartment block have been reported, mostly so far in patients with hip fracture [7-9] or with lower limb surgery (i.e. knee ligament reconstruction or femur surgery) [14,15], but also in children [5,10-13,16].

Our study was designed to compare the analgesic effect of FIC blocks with FEM blocks in hip surgery, because we needed a model where

	FEM (n=40)	FIC (n=40)	p - values
<b>Onset time of sensory block</b>			
Anterior cranial (minutes)	3 (3)	5 (5)	0.04*
Anterior knee (minutes)	4 (3)	7 (6)	0.002*
Lateral cranial (minutes)	6 (4)	6 (6)	0.99
Lateral knee (minutes)	5 (4)	7 (6)	0.20
<b>Onset time of motor block</b>			
Knee extension (minutes)	6 (6)	9 (6)	0.0002*
Thigh adduction (minutes)	7 (7)	10 (7)	0.08

**Table 3:** Onset time of complete sensory and motor blockade after bolus injection of 50 ml prilocaine 1%  
Values are expressed as mean (standard deviation). \*Statistically significant (<0.05).

Pain (VAS 0-10)	FEM (n=36)	FIC (n=38)	p - values (p)
PACU 2 h postoperative at rest	3 (3)	3 (3)	0.62
PACU 2 h postoperative at movement	5 (4)	5 (4)	0,73
24h postoperative at rest	3 (3)	2 (2)	0.62
24h postoperative at movement	5 (3)	4 (3)	0.87
48h postoperative at rest	1 (2)	1 (2)	0.2
48h postoperative at movement	3 (3)	4 (2)	0.34
72h postoperative at rest	1 (1)	1 (1)	0.71
72h postoperative at movement	3 (3)	3 (2)	0.47
day of discharge at rest	1 (1)	1 (1)	0.71
day of discharge at movement	2 (2)	2 (2)	0.49
bei Entlassung bei Belastung	2 (0 / 3)	1 (0 / 3)	0,49 / 0,47

**Table 4:** Pain scores  
VAS: visual analogue scale, VAS 0 = no pain, VAS 10 = maximal pain  
Values are expressed as mean (standard deviation). \*Statistically significant (0.05).

the sciatic nerve does not play an important role in pain development compared to major knee surgery for example, and therefore makes a comparison of the two techniques possible without interference of other pain sources. The area of the hip joint is mainly innervated by the femoral nerve (anterior hip joint capsule, proximal femur, quadriceps, iliacus and pectineus muscles).

One may criticize that hip surgery in general is not considered to be a very painful procedure and therefore makes a comparison of the two techniques difficult. This is true in part, but during at least the first 12 hours up to 24 hours, pain control was shown to be more effective with a form of lumbar plexus anesthesia than with systemic analgesia, demonstrating the higher pain levels of hip replacement surgery during the first postoperative day [1,17,18].

In this trial catheter placement procedure was rated as "rather easy" on a Four-Point-Lickert-Scale by the anesthetists in the FEM and the FIC group. The block is in general easy to perform without the need for further equipment (nerve stimulator, stimulating catheter) [8]. But we still believe that performing the FIC block has to be learned properly and is not as easy as other publications suggest [8]. We had to perform more than one skin puncture in 5.6% of cases in the FEM, but 21% in the FIC group. Feeling the fascia-clicks can be difficult. Hence, more than one attempt can be necessary.

The onset time of sensory and motor blockade in the territories of the femoral nerve (loss of cold sensation at the anterior aspect of the thigh, knee extension) was significantly shorter in the FEM group. This indicates a more adjunct position of the catheter to the femoral nerve when using the classic approach. In the FIC approach, the local anesthetic needs more time to reach the nerve, although it is injected in the compartment of the femoral nerve [19].

The sensory block of the lateral thigh (LFC nerve) was achieved in the same time in both groups. FIC blocks should be more effective than femoral nerve blocks in blocking the lateral femoral cutaneous nerve [10] because the injection point is closer to the LFC nerve. Capdevilla reported a faster and more consistent sensory blockade of the LFC nerve [2]. We presume that the mean delayed onset of sensory and motor blockade in the FIC group (although not always significant) is due to an incorrect placement of the catheters in some cases. Dolan et al. note that subcutaneous fascia in certain regions may consist of several layers. Blind penetration of any of these fascial planes may have been wrongly perceived as that of the fascia iliaca [20].

No significant differences between the FEM and the FIC group were noted regarding the piritramide consumption in the postoperative period, but it was slightly higher in the FIC group (FEM: 20 mg, FIC 26 mg). The LFC nerve innervates the skin in which the incision for hip replacement is made, which should theoretically make the FIC block more favorable for postoperative pain relief in hip replacement patients. We noticed at the catheter injection area that there was a leak with local anesthetic in 18.4% of the patients in the FIC group, compared to only 5.6% in the FEM group. The loss of local anesthetic may as well be a reason for additional demand of analgetics via PCA in the FIC group.

According to the comparable action on pain of the two catheters, we also did not find any influence on functional outcome 12 and 90 days after surgery measured with WOMAC Index, Harris Hip Score, Lequesne Score and SF 36 questionnaire.

## Conclusion

The fascia iliaca compartment block is easy to perform even with an ad hoc implementation of the new technique in our department, with a smaller theoretical risk of direct vascular or neural injury. The FIC block was less time-consuming to perform compared to the stimulating catheter technique. This result may not hold true for a nonstimulating catheter technique or an ultrasound guided fascia iliaca compartment or femoral nerve catheter technique. The onset time for sensory and motor blockade was slower in the FIC group, but postoperative analgesia measured with opioide PCA consumption and VAS score was equally effective, as well as functional outcome over three months. In case of contraindications for a classic femoral nerve block (e.g. vascular prosthesis, local infection), the fascia iliaca compartment block is an equivalent procedure.

## References

1. Singelyn FJ, Ferrant T, Malisse MF, Joris D (2005) Effects of intravenous patient-controlled analgesia with morphine, continuous epidural analgesia, and continuous femoral nerve sheath block on rehabilitation after unilateral total-hip arthroplasty. *Reg Anesth Pain Med* 30: 452-457.
2. Capdevila X, Biboulet PH, Bouregba M, Barthelet Y, Rubenovitch J, et al. (1998) Comparison of the three-in-one and fascia iliaca compartment blocks in adults: clinical and radiographic analysis. *Anesth Analg* 86: 1039-1045.
3. Winnie AP, Ramamurthy S, Durrani Z (1973) The inguinal paravascular technic of lumbar plexus anesthesia: the "3-in-1 block". *Anesth Analg* 52: 989-996.
4. Seeberger MD, Urwyler A (1995) Paravascular lumbar plexus block: block extension after femoral nerve stimulation and injection of 20 vs. 40 ml mepivacaine 10 mg/ml. *Acta Anaesthesiol Scand* 39: 769-773.
5. Dalens B, Vanneville G, Tanguy A (1989) Comparison of the Fascia Iliaca Compartment Block with the 3-in-1-Block in Children. *Anesth Analg* 69: 705-713.
6. Morin AM, Kratz CD, Eberhart LHJ, Dinges G, Heider E, et al. (2005) Postoperative analgesia and functional recovery after total-knee replacement: comparison of a continuous posterior lumbar plexus (psoas compartment) block, a continuous femoral nerve block, and the combination of a continuous femoral and sciatic nerve block. *Reg Anesth Pain Med* 30: 434-445.
7. Foss NB, Kristensen BB, Bundgaard M, Bak M, Heiring C, et al. (2007) Fascia iliaca compartment blockade for acute pain control in hip fracture patients: a randomized, placebo-controlled trial. *Anesthesiology* 106: 773-778.
8. Høgh A, Dremstrup L, Jensen SS, Lindholt J (2008) Fascia iliaca compartment block performed by junior registrars as a supplement to pre-operative analgesia for patients with hip fracture. *Strategies Trauma Limb Reconstr* 3: 65-70.
9. Monzon DG, Iserson KV, Vazquez JA (2007) Single fascia iliaca compartment block for post-hip fracture pain relief. *J Emerg Med* 32: 257-262.
10. Lako SJ, Steegers MA, van Egmond J, Gardeniers J, Staals LM, et al. (2009) Incisional continuous fascia iliaca block provides more effective pain relief and fewer side effects than opioids after pelvic osteotomy in children. *Anesth Analg* 109: 1799-1803.
11. Paut O, Sallabery M, Schreiber-Detumeny E, Rémond C, Bruguerolle B, et al. (2001) Continuous fascia iliaca compartment block in children: a prospective evaluation of plasma bupivacaine concentrations, pain scores, and side effects. *Anesth Analg* 92: 1159-1163.
12. Stevens M, Harrison G, McGrail M (2007) A modified fascia iliaca compartment block has significant morphine-sparing effect after total hip arthroplasty. *Anaesth Intensive Care* 35: 949-952.
13. Wathen JE, Gao D, Merritt G, Georgopoulos G, Battan FK (2007) A randomized controlled trial comparing a fascia iliaca compartment nerve block to a traditional systemic analgesic for femur fractures in a pediatric emergency department. *Ann Emerg Med* 50: 162-171.
14. Farid IS, Heiner EJ, Fleissner PR (2010) Comparison of femoral nerve block and fascia iliaca block for analgesia following reconstructive knee surgery in adolescents. *J Clin Anesth* 22: 256-259.

15. Morau D, Lopez S, Biboulet P, Bernard N, Amar J (2003) Comparison of continuous 3-in-1 and fascia iliaca compartment blocks for postoperative analgesia: feasibility, catheter migration, distribution of sensory block, and analgesic efficacy. *Reg Anesth Pain Med* 28: 309-314.
16. Yun MJ, Kim YH, Han MK, Kim JH, Hwang JW (2009) Analgesia before a spinal block for femoral neck fracture: fascia iliaca compartment block. *Acta Anaesthesiol Scand* 53: 1282-1287.
17. Stomberg MW, Oman UB (2006) Patients undergoing total hip arthroplasty: a perioperative pain experience. *J Clin Nurs* 15: 451-458.
18. Singelyn FJ, Gouverneur JM (1999) Postoperative analgesia after total hip arthroplasty: i.v. PCA with morphine, patient-controlled epidural analgesia, or continuous "3-in-1" block?: a prospective evaluation by our acute pain service in more than 1,300 patients. *J Clin Anesth* 7: 550-554
19. Kizelshteyn G, Crevecoeur E (1990) Anatomic consideration of the fascia iliaca compartment block. *Anesth Analg* 71: 210-212
20. Dolan J, Williams A, Murney E, Smith M, Kenny GN (2008) Ultrasound guided fascia iliaca block: a comparison with the loss of resistance technique. *Reg Anesth Pain Med* 33: 526-531.

This article was originally published in a special issue, **Pain Management Anesthesia** handled by Editor(s), Dr. Howard Smith, Albany Medical Center, USA