

A pachymeningitis as an unusual cause of headache in systemic lupus erythematosus

Thara Larbi^{1*}, Saloua B'chir Hamzaoui¹, Maroua Mrouki¹, Amira Manamani², Amira Ouni¹, Kamel Bouslama¹, Skander M'rad¹

¹Department of internal medicine, Mongi Slim Hospital, La Marsa, Tunisia

²Department of Radiology, Mongi Slim Hospital, La Marsa, Tunisia

*Corresponding author: Thara Larbi, Department of internal medicine, Mongi Slim Hospital, La Marsa, Tunis Tunisia, Tel: 00 216 70 109 181; E-mail: L_thara@hotmail.com

Received date: December 4, 2015; Accepted date: December 15, 2015; Published date: January 22, 2016

Copyright: © 2016 Thara Larbi. This is an open-access article distributed under the terms of the Creative Commons Attribution License, which permits unrestricted use, distribution, and reproduction in any medium, provided the original author and source are credited.

Abstract

We report a case of systemic lupus erythematosus (SLE) complicated by hypertrophic pachymeningitis (HP) four year after the onset of SLE. A 25-year-old woman with a previous diagnosis of SLE was admitted for severe headaches and vomiting without signs of meningeal irritation or papilloedema on fundus examination. Brain magnetic resonance imaging showed diffuse thickening of the dura matter with hyperintense signal on fluid-attenuated inversion recovery sequence and gadolinium contrast enhancement. There was no sinus thrombosis on MR venography. Both clinical symptoms and imaging findings improved after steroid therapy.

Introduction

Hypertrophic pachymeningitis (HP) is a rare clinical disorder characterised by focal or diffuse thickening of the dura matter [1,2]. It is classified as either idiopathic or secondary HP, depending on the presence of concurrent disorders as infections (tuberculosis, syphilis, and fungal infections), autoimmune diseases or neoplasms (lymphoma and carcinoma). The association between systemic lupus erythematosus (SLE) and HP is extremely rare. Herein, we report the case of a young woman with SLE complicated four years later by HP.

Case report

A 21-year-old tunisian woman was diagnosed with SLE in July 2009, after presentation with facial erythema, mouth ulcerations, Raynaud's phenomenon, pleuropericarditis and oligoarthritis. She had no proteinuria. Immunological evaluation revealed positive antinuclear antibodies by indirect immunofluorescence method with a speckled pattern at a titre of 1/1280 and positive antibodies direct against extractable nuclear antigens type Ro/SSA, anti-ribonucleoprotein (anti-RNP) and anti-Smith (anti-Sm). Anti-double-stranded DNA antibodies, anticardiolipin and anti-β2 glycoprotein antibodies were negative. She was treated with oral steroids (prednisone 0.5 mg/kg/day) with tapering dose and hydroxychloroquine 400 mg daily with a satisfactory clinical response. Between July 2009 and October 2013, she had been regularly followed up and was admitted five times for mild flares or infectious episodes.

On October 2013, while she was on hydroxychloroquine 200 mg daily, she presented with severe headache for 3 days associated with vomiting. On admission, her blood pressure was 95/59 mm Hg and her body temperature was normal. Neurological examination revealed no signs of meningeal irritation nor neurological deficits and there was no papilloedema on fundus examination. Laboratory tests showed normal blood cell count, elevated C-reactive protein at 43 mg/l and elevated erythrocyte sedimentation rate at 85 mm. Tests of renal and liver functions were normal.

Anti-nuclear antibodies were positive at 1/1280 and antibodies directed against extractable nuclear antigens type anti-Sm, anti-SSA and anti-RNP were detected. Brain magnetic resonance imaging (MRI) showed a generalized and regular thickening of the dura matter with hyperintense signal on fluid-attenuated inversion recovery (FLAIR) sequence and gadolinium contrast enhancement (figure 1). MR venography showed no venous sinus thrombosis.

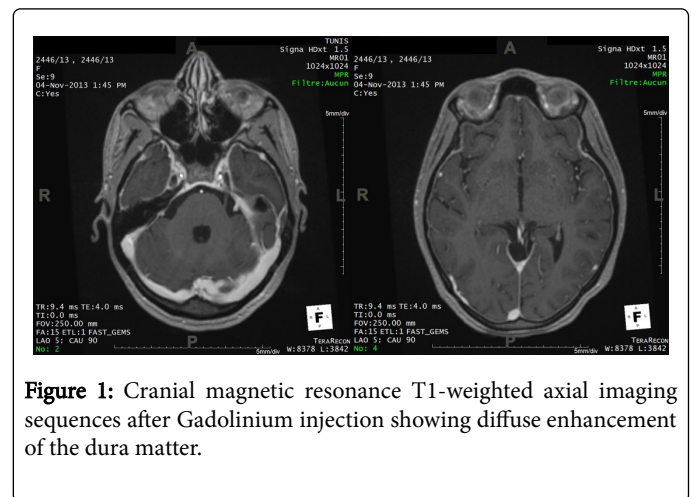


Figure 1: Cranial magnetic resonance T1-weighted axial imaging sequences after Gadolinium injection showing diffuse enhancement of the dura matter.

Lumbar puncture revealed a normal pressure. Cerebrospinal fluid (CSF) biochemistry (white cell count, protein, glucose) was within normal limits. The CSF was negative for bacterial and tuberculous culture. The serum was negative for VDRL, Lyme and HTLV1 tests. Tuberculin skin test was negative.

The patient was treated with prednisone 20 mg daily (0.5 mg/kg/day). The headache gradually resolved by the 5th day after the initiation of steroid therapy, which was tapered after 6 weeks. A follow-up brain MRI was performed one year later and showed complete resolution of meningeal thickness and gadolinium enhancement

(figure 2). When last seen, she was still receiving a maintenance dose of 2.5 mg prednisone on alternate days. She had no further headache.

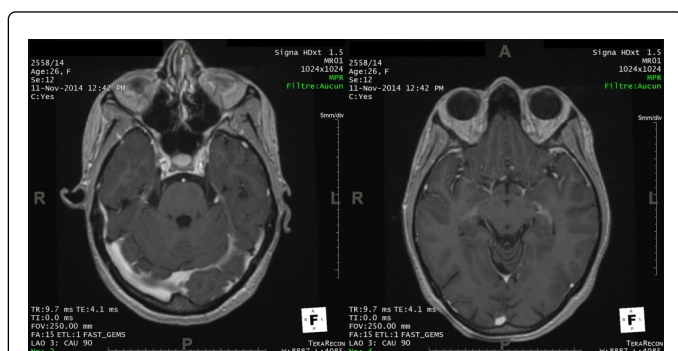


Figure 2: Control cranial magnetic resonance T1- weighted axial imaging sequences after Gadolinium injection showing complete resolution of the dura matter enhancement.

Discussion

We describe the case of a 25-year-old woman with SLE fulfilling ACR classification criteria, who later developed PM. Our patient presented with severe headache, which is the most common presentation of HP [3,4]. Other neurological manifestations depend on the site of involvement, including cranial neuropathies, pituitary dysfunction, cerebellar ataxia, seizure, myelopathy and neuro-ophthalmic complications. The diagnosis of HP is based on the imaging finding of enhancing pachymeningeal thickening, as seen in our case. In our case, HP occurred in a patient with a previous diagnosis of SLE. Based on the negative bacteriological examinations and rapid clinical improvement after steroid therapy, we considered that HP is caused by SLE itself. When HP is the sole manifestation, diagnosis may be more difficult and a dural biopsy is usually required to establish the diagnosis of idiopathic PM and to exclude other causes.

An increasing number of case reports suggested an association of HP with autoimmune diseases, most commonly Wegener's granulomatosis and ANCA-positive vasculitis [5,6]. An association with connective tissue diseases, such as undifferentiated connective tissue disease [7], mixed connective tissue disease [8], rheumatoid arthritis [9], Sjogren's syndrome [10,11], antiphospholipid syndrome [12] had also been reported.

To our knowledge, there are only five case reports suggesting the association of HP and SLE [13-17]. The delay between the diagnosis of SLE and HP was variable. In one case, the patient developed HP after 20 years of SLE [14]. Whereas, in two cases, HP was the first manifestation of the SLE [16,17]. In the case of Sanchez Garcia et al, cranial MRI revealed besides a generalized thickening of the dura mater, the presence of subdural collections very suggestive of CSF hypotension, which is a differential diagnosis of HP. But, in that case, persistent dura matter thickening and resolution of subdural collections after immunosuppressive therapy made the authors consider that PM was secondary to both entities: CSF hypotension and LES. They hypothesised that meningeal inflammation would lead to a meningeal disruption causing a CSF leak and intracranial hypotension. In the case of Ochi et al, worsening of headache and hearing loss by head up position was also suggestive of intracranial hypotension.

Dural biopsy was performed in one case of HP in LES and showed thickened dura with foci of dystrophic calcification and small number of chronic inflammatory cells [16]. No histological diagnosis was obtained in the other cases. All cases improved after steroid therapy, even one patient who received only 10 mg daily of prednisone. One patient had mycophenolate mofetil for lupus nephritis.

Conclusion

HP is a rare complication in SLE. There are only five case reports suggesting the association of HP and SLE in the medical literature. In our case, HP presented in a patient with a previous diagnosis of SLE. In some cases, HP can be the initial presentation and even the sole clinical manifestation of underlying autoimmune disease. Even if rare, HP should be considered in SLE patients with severe and persistent headache. Steroids must be considered as first-choice treatment.

References

1. Fain O, Seror O, Wirth J, Heron C, Mathieu E, et al. (1999) Les pachyméningites crâniennes. *Rev Médecine Interne* 20 : 234-246.
2. Brüggemann N, Gottschalk S, Holl-Ulrich K, Stewen J, Heide W, et al. (2010) Cranial pachymeningitis: a rare neurological syndrome with heterogeneous aetiology. *J Neurol Neurosurg Psychiatry* 81: 294-298.
3. Mamelak AN, Kelly WM, Davis RL, Rosenblum ML (1993) Idiopathic hypertrophic cranial pachymeningitis. Report of three cases. *J Neurosurg* 79: 270-276.
4. Kupersmith MJ, Martin V, Heller G, Shah A, Mitnick HJ (2004) Idiopathic hypertrophic pachymeningitis. *Neurology* 62: 686-694.
5. Nagashima T, Maguchi S, Terayama Y, Horimoto M, Nemoto M, et al. (2000) P-ANCA-positive Wegener's granulomatosis presenting with hypertrophic pachymeningitis and multiple cranial neuropathies: case report and review of literature. *Neuropathology* 20: 23-30.
6. Yokoseki A, Saji E, Arakawa M, Kosaka T, Hokari M, et al. (2014) Hypertrophic pachymeningitis: significance of myeloperoxidase anti-neutrophil cytoplasmic antibody. *Brain* 137: 520-536.
7. Lampropoulos CE, Zain M, Jan W, Nader-Sepahi A, Sabin IH, et al. (2006) Hypertrophic pachymeningitis and undifferentiated connective tissue disease: a case report and review of the literature. *Clin Rheumatol* 25: 399-401.
8. Fujimoto M, Kira J, Murai H, Yoshimura T, Takizawa K, et al. (1993) Hypertrophic cranial pachymeningitis associated with mixed connective tissue disease : a comparison with idiopathic and infectious pachymeningitis. *Intern Med* 32: 510-512.
9. Yuh WT, Drew JM, Rizzo M, Ryals TJ, Sato Y, et al. (1990) Evaluation of pachymeningitis by contrast-enhanced MR imaging in a patient with rheumatoid disease. *AJNR Am J Neuroradiol* 11: 1247-1248.
10. Li JY, Lai PH, Lam HC, Lu LY, Cheng HH, et al. (1999) Hypertrophic cranial pachymeningitis and lymphocytic hypophysitis in Sjögren's syndrome. *Neurology* 52: 420-423.
11. Abouzaid CH, Kissani N, Essaoudouni L (2011) [Cranial pachymeningitis and primary Sjögren's syndrome]. *Rev Neurol (Paris)* 167: 348-351.
12. Tokushige S, Matsumoto H, Takemura T, Igeta Y, Hashida H (2012) Secondary hypertrophic pachymeningitis in antiphospholipid syndrome. *J Neuroimmunol* 250: 115-117.
13. Okano R, Kuroki M, Otsuka M, Yamada A, Ueki A (1993) [Leptomeningeal abnormality on Gd-DTPA enhanced MRI in a case of SLE presenting diffuse organic brain syndrome]. *Rinsho Shinkeigaku* 33: 78-82.
14. Ochi S, Nanki T, Komano Y, Suzuki F, Ogawa J, et al. (2007) [A case report of hypertrophic pachymeningitis associated with systemic lupus erythematosus, showing a headache and hearing loss resembling intracranial hypotension]. *Nihon Rinsho Meneki Gakkai Kaishi* 30: 55-60.

-
15. Takahashi T, Koji H, Isomura A, Komagata Y, Kaname S, Arimura Y, et al. (2012) [Case report: a case of medial longitudinal fasciculus syndrome and hypertrophic pachymeningitis in an elderly-woman with systemic lupus erythematosus]. *Nihon Naika Gakkai Zasshi* 101: 2055-2058.
 16. Yu WL, Bhatia KSS, Wang K (2012) Hypertrophic Pachymeningitis as the First Manifestation of Systemic Lupus Erythematosus. *Hong Kong J Radiol* 15: 119-122.
 17. Sanchez-Garcia M, Gomez-Delgado F, Gomez-Garduno A, Blanco-Molina A, Puebla RA (2014) Hypertrophic pachymeningitis associated with cerebral spinal fluid hypovolemia as initial presentation of systemic lupus erythematosus. *Lupus* 23: 197-200.