

## A Mnemonic for Neck Triangles

Abdulrauf Badr MI\*



Department of Surgery, King Faisal Specialist Hospital and Research Center Jeddah, Saudi Arabia

### ABSTRACT

Anatomical Neck Triangles are imaginary to some extent. Their significance to many surgical specialties is invaluable. Among all basic Medical sciences subjects, Anatomy is most prone to be forgotten. None of the other subjects has the amount of mnemonics described or invented compared to it. Junior years students of Medical schools need to memorize anatomy with no or very little knowledge of its clinical applications. Relatively speaking, that can be quite cumbersome for them compared to those who are already involved in surgical residency training program, when anatomy knowledge is concerned. Surgeons who specialize or exclusively work in a selected anatomic region, they become experts and famous in their field and in that particular operation, mostly because they subconsciously become oriented to that region's anatomy. However, those who work on various anatomical areas, frequently need to refresh their anatomy knowledge. Mnemonics, therefore are helpful for various level medical professionals. The Neck represents a relatively limited transition zone or passage of various tissue structures besides great vessels and nerves between Head, Chest and Upper extremities, very much like a three-way connector. Unless the concept of Neck triangles was there, it would have been very difficult to discuss or communicate about neck related procedures. The theory of simulating Neck triangles to a Bird like creature was long thought and utilized by the author. Here we are describing and sharing this imaginary mnemonic to help in the ability of recalling and drawing those triangles. An analogy of a flying Bat is used.

**Keywords:** Neck; Triangles; Anterior; Posterior; Digastric; Mnemonics; Drawing; Image; Surgical; Residents; Students

*"Imagination is more important than knowledge"* Albert Einstein

### INTRODUCTION

Knowledge of Neck Triangles is critical for many surgical specialties, including otolaryngology head and neck surgery; general surgery; pediatric surgery; vascular surgery; neurosurgery; plastic, aesthetic and reconstructive surgery [1]. The neck is such an interesting junction where various structures have to travel in a compact manner to and from different territories, Head; Upper extremities; and the Trunk [2,3], very much like a 3 way connector. There is no such an area of anatomical complexity in rest of the body where structures related to almost all physiologic systems are present in one limited area. The two major triangles of the neck, anterior and posterior are beautifully partitioned by the Sternocleidomastoid (STCM) muscle on either side, the mirror image of which with the posterior belly of digastric muscles gives the impression of wings (Figure 1). The STCM

muscle and posterior belly of Digastric are such important muscles because of the vital structures they overlap and related to, namely the great vessels and the cranial nerves. The Posterior triangle's significance however, is mostly due to the Brachial plexus and Phrenic nerve. The reason why specifically anatomy literature has abundant mnemonics is the fact it has the tendency to be easily forgotten [4,5]. By definition, Mnemonic is a technique that helps remembering relatively large amount of important information. Mnemonics can be auditory or visual, people have used expressions; names; rhymes; music notes; models; and images [4,6]. In this article, an image Mnemonic that would help remembering the main anatomical outlines for the neck triangles has been innovated.

**Correspondence to:** Abdulrauf BMI, Program Director, Plastic Reconstructive Surgery, Department of Surgery, Section of Plastic and Reconstructive Surgery, King Faisal Specialist Hospital and Research Center Jeddah, Saudi Arabia, Telephone: (44)7778029219; E-mail: badrplastics@gmail.com

**Received date:** May 1, 2020; **Accepted date:** May 10, 2020; **Published date:** May 24, 2020

**Citation:** Abdulrauf BMI (2020) A Mnemonic for Neck Triangles. *Anat Physiol* 10:323. doi:10.35248/2161-0940.2020.10.323

**Copyright:** ©2020 Abdulrauf BMI. This is an open-access article distributed under the terms of the Creative Commons Attribution License, which permits unrestricted use, distribution, and reproduction in any medium, provided the original author and source are credited.

## METHODS

The Author at first sketched a full-frontal view drawing of the major muscles that divide the neck into its major triangles symmetrically (Figure 1). The Author has long thought of this theory: This fullfrontal view, very much resembles a bird like creature, spreading its wings. After doing a pilot project of experimenting with sketches of various creatures, a Bat was found to be the perfect match. Next, the Author drew a detailed body, extremities, wings and the Bat's head (Figure 2) and used it to define the muscles that create the borders for the Anterior triangle of the neck and its divisions, Muscular and Carotid; the Digastric triangle and partly the Posterior triangle with its subdivisions, the Subclavian and Occipital triangles (Figures 1 and 2).

## RESULT

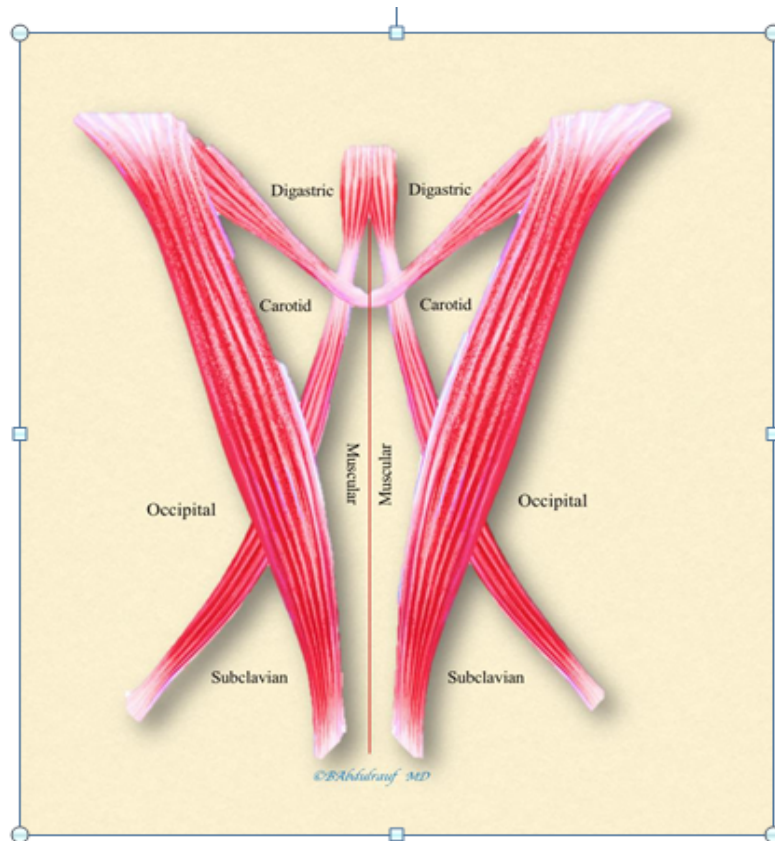
The Bat's arms stretch semi abducted representing the posterior belly of Digastric muscles. Bat's head and neck represent anterior belly of Digastric muscles. Bat's wings lateral borders represent the STCM muscles and divide the Anterior and Posterior triangles medially and laterally respectively. The body of the Bat represents midline and divides the Muscular triangles on either side. Bat's lower extremity up to the knee represents the superior belly of Omohyoid muscle making a boundary between the Muscular and Carotid triangles. The lower leg of the Bat which is in semi flexed position is represented by the inferior belly of Omohyoid muscle, divides the Posterior triangle into a large Occipital triangle above and a smaller Subclavian triangle below. Bat's knee somewhat represents the tendinous junction of the two bellies of Digastric muscle (Figure 3).

## DISCUSSION

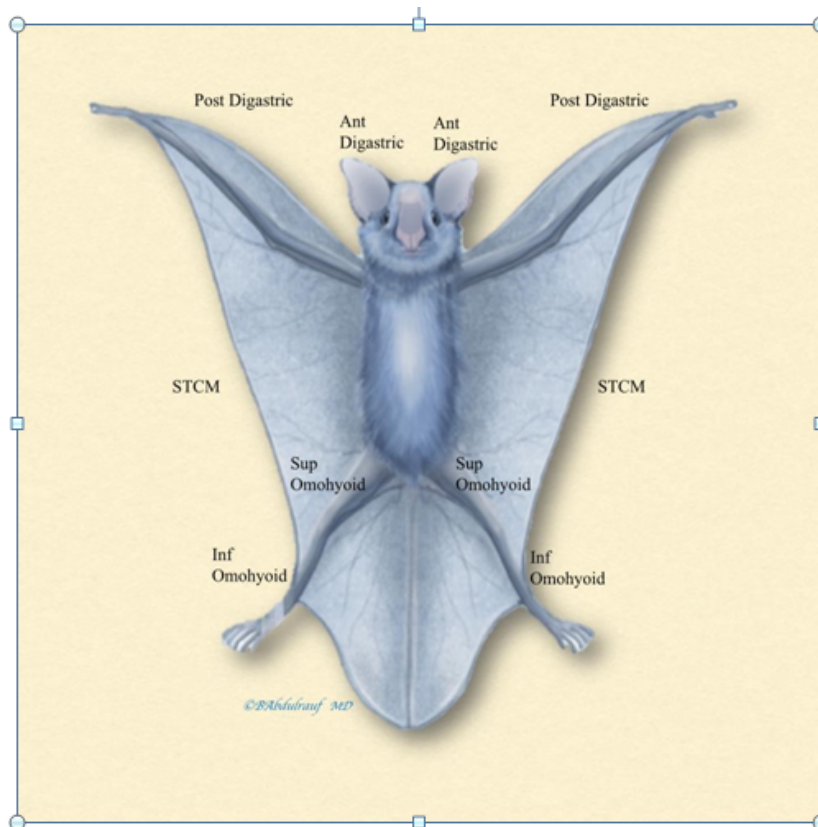
Triangles or spaces in anatomy literature are made for the sake of their clinical or surgical importance. Very often the muscle(s) that are forming a border or more of such a space is probably not that significant in size or function, and it may not even be noticed during dissection. A typical example would be the omohyoid muscle being used as a border. A more obvious or larger structure may theoretically form an obvious structure but geometrically it would not contribute to a specific shape. Anatomists came up with such geometrical spaces and borders for the sake of remembering made easier, and for the sake of signifying certain structures within that space. Therefore, many of these geometrical spaces are imaginary to some extent. Other examples of geometrical spaces include Femoral triangle in the upper thigh and the Quadrangular space in the lateral upper

back and arm. *For non-anatomists, anatomy is probably the most easily forgettable basic science*, this is especially true for non-surgeons. As surgeons, we need to revise anatomy on regular basis particularly in preparation for an unusual surgical procedure or whenever there is a need to visit a less frequently encountered anatomic region. Examples include general surgeons and specifically plastic surgery north American training program residents, with an extensive syllabus, requiring them to learn on anatomy and procedures from head to toes. Medical students who do not yet realize the significance of anatomical details, are in much more difficult situation in terms of recalling. Neck is obviously the primary territory for Otolaryngologists Head and Neck surgeons. Many general surgeons do tracheostomies, thyroid surgery and neck dissections. Surgery to the Carotids is been performed by Vascular surgeons and Neurosurgeons. Pediatric surgeons work on neck masses in children beside lymph nodes biopsies. Brachial plexus surgery is performed by sub specialized Reconstructive plastic surgeons, some Neurosurgeons, and very unusually by some Orthopedic surgeons. The Brachial plexus trunks and the Spinal accessory nerve are essentially the two major contents of the Posterior triangle. Iatrogenic injuries to any of these critical nerve structures are not uncommon, such incidents might happen when procedures apparently seem simple, such as lymph node biopsies are taken lightly or with inadequate knowledge of the anatomical borders and three-dimensional relations [7]. Aesthetic surgeons work on neck rejuvenation surgeries, and Reconstructive microsurgeons do tissue transfer of any component like muscle flaps, fascio-cutaneous flaps or, osteo-cutaneous flaps following cancer resection in Head and Neck region and reestablish blood flow in the neck [8]. For all those reasons, the neck is a common place and such a critical zone for many disciplines. Some may argue that mnemonics promote surface rather than deep approach to learning [4]. However, for subjects that are easily forgotten, any means of remembering a general outline is in fact invaluable [5,6]. "Little bit of oxygen is better than no oxygen" would be an appropriate proverb to support such an argument. We believe the image analogy of a Bat can be of great help for students and surgical residents in training, enabling them to quickly draw the main outlines of neck triangles. knowledge of anatomy, imagination, artistry and delicacy in handling tissues, all go hand in hand. Those are excellent surgeon's traits that are welcomed [9,10].

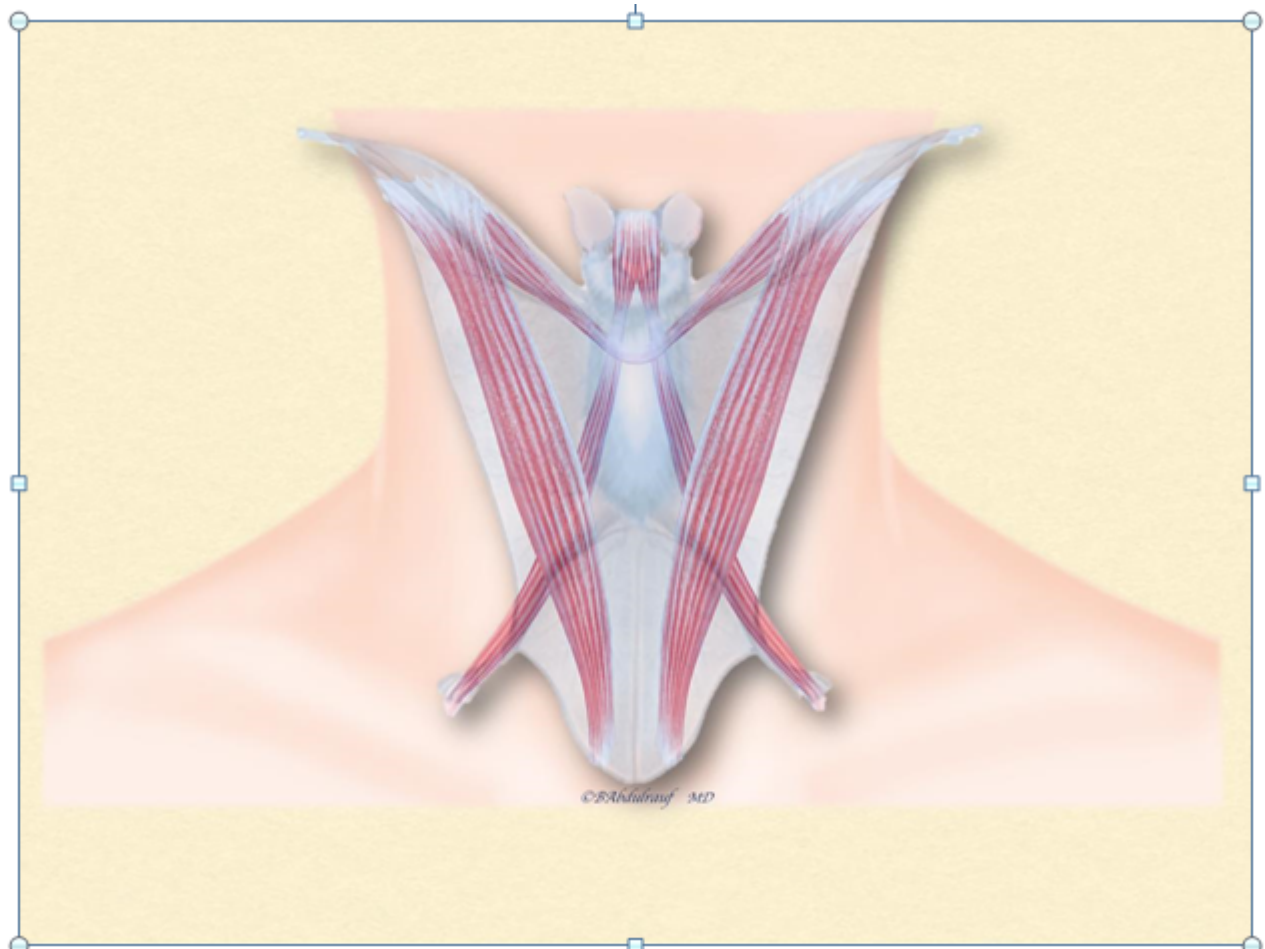
Finally, Albert Einstein has also stated: "*Education is what remains after one has forgotten what one has learned in school*".



**Figure 1:** Mirror image frontal view of the Neck triangles, Anterior with its subdivisions: Carotid triangle and Muscular triangle; Digastric triangles and partly the Posterior triangles with its subdivisions: Occipital triangle and Subclavian triangle. The overall view simulates a living being with wings.



**Figure 2:** An Analogy of a Bat is used to represent various muscles and Neck triangles. Bat's arms are semi abducted representing Posterior Digastric muscle; its head and neck represent the Anterior Digastric muscle; Bat's wings lateral borders represent the wide STCM muscle; Bat's thigh is represented by the superior belly of Omohyoid muscle, and its leg is represented by the inferior belly of Omohyoid muscle.



**Figure 3:** An overlap of topographical illustration of the Neck triangles with the Bat, demonstrating the similarity between the two, and suggesting sketch of the Bat as image mnemonic for the Neck triangles.

## CONCLUSION

Anatomical spaces and the borders that make them, unless been reviewed on a frequent basis, are prone to be easily forgotten. An imagination in one's mind or a simple sketch of the shape of a Bat, would easily and quickly allow one to symbolize major triangles of the neck in a mirror image representation. This image mnemonic is dedicated to all generations of medical students and young surgeons around the globe. It can be promised; Anatomical Neck triangles will be remembered unlike many other lessons.

## REFERENCES

- Hollinshead WH. The nose and paranasalsinuses. The Head and Neck. *Anat Surg.* 1982;1:ed3rd
- Singh M, Vashistha A, Chaudhary M, Kaur G. Forgotten triangles of neck. *Ann Maxillofac Surg.* 2016;6:91-93.
- Kohan EJ, Wirth GA. Anatomy of the neck. *Clin Plast Surg.* 2014;41:1-6.
- Smith CF, Border S. The twelve cranial nerves of christmas: mnemonics, rhyme, and anatomy-seeing the lighter side. *Anat Sci Educ.* 2019;12:673-677.
- Hoefflin SM. Anatomy of the platysma and lip depressor muscles: A simplified mnemonic approach. *Dermatol Surg.* 1998;24:1225-1231.
- Chung BS, Koh KS, Oh CS, Park JS, Lee JH, Chung MS. Effects of reading a free electronic book on regional anatomy with schematics and mnemonics on student learning. *J Korean Med Sci.* 2020;35:e42.
- Nason RW, Abdulrauf BM, Stranc MF. The anatomy of the accessory nerve and cervical lymph node biopsy. *Am J surg.* 2000;180:241-243.
- Disa JJ. Grabb's Encyclopedia of Flaps. Head and Neck. *Plastic and Reconstructive Surgery.* 2010;125:747-748.
- Rohrich RJ, Sullivan D. So you want to be like Leonardo da Vinci or Michelangelo? Which one are you? *Plast Reconstr Surg.* 2011;128:1309-1311.
- Toledo-Pereyra LH. Leonardo da Vinci: the hidden father of modern anatomy. *J Invest Surg.* 2002;15:247 -249.