

A Contemporary Review of Acute Aortic Dissection

Subhi J Al'Aref¹, Leonard N Girardi², Richard Devereux¹, Christopher Lau², Bobby D Ghosh¹, Rajesh V Swaminathan¹, Dmitriy N Feldman¹, Luke K Kim¹, Geoffrey Bergman¹, Robert M Minutello¹, S Chiu Wong¹, Harsimran S Singh^{1*}

¹Division of Cardiology, Department of Medicine. NewYork Presbyterian Hospital – Weill Cornell Medical Center. New York, NY 10065.

²Department of Cardiothoracic Surgery. NewYork Presbyterian Hospital – Weill Cornell Medical Center. New York, NY 10065.

*Corresponding author: Harsimran S. Singh, M.D., Assistant Professor of Medicine, Assistant Professor of Medicine in Pediatrics, Greenberg Cardiology Division, Cardiac Catheterization Laboratory, Weill Medical College of Cornell University, 525 East 68th Street, Starr-4, New York, NY 10021, USA, Tel: (212) 746-4644; Fax: (212) 746-8295; E-mail: has9028@med.cornell.edu

Received date: June 03, 2015; Accepted date: July 07, 2015; Published date: July 14, 2015

Copyright: © 2015 Singh HA. This is an open-access article distributed under the terms of the Creative Commons Attribution License, which permits unrestricted use, distribution, and reproduction in any medium, provided the original author and source are credited.

Abstract

Acute aortic dissection is one of the most rapidly fatal clinical entities that can be encountered in the emergency department setting. Prompt establishment of the diagnosis, through focused physical examination and non-invasive imaging, followed by rapid medical and surgical therapy, are the only effective methods to alter survival in patients with acute aortic dissection. The aim of this paper is to perform an up-to-date clinical review of acute aortic dissection including its epidemiology, risk factors, clinical presentation, algorithms in establishing the diagnosis, and of available medical and surgical therapies.

Keywords: Aortic dissection; Emergency department; Echocardiography; Computed tomography; Endovascular intervention

Abbreviation

AD: Aortic dissection; ED: Emergency department; CT: Computed tomography

Introduction

Chest pain is a common presentation and diagnostic challenge in the emergency department (ED) setting [1]. In the US, chest pain accounted for 11.4 million ED visits in 2005 (approximately 10% of the estimated 109 to 116 million annual ED visits) [2]. Part of the diagnostic challenge of chest pain syndrome includes variability in patient presentation associated with age, gender, and comorbidities in addition to a wide spectrum of other potential diagnoses ranging from the benign to life threatening. While the majority of chest pain cases presenting to the ED are eventually diagnosed as non-cardiovascular in etiology (such as gastro-esophageal reflux disease or musculoskeletal problems) [3], it is important to exclude acute life-threatening conditions, including acute myocardial infarction, pulmonary embolism, visceral perforation, and aortic dissection (AD).

The term AD is commonly used to describe several different mechanisms of acute aortopathy that can include intimal arterial tears with extension of blood flow into the medial space, abrupt aneurysmal dilation, penetrating atherosclerotic ulcers (PAU), and intramural hematomas (IMH) [4]. Historically, Galen is credited with the first recorded description of aortic dissections and aneurysms during the 2nd century. In 1761, Giovanni Morgagni comprehensively described the anatomic and basic pathologic changes in a patient with aortic rupture. The first reported successful management of acute AD was performed by DeBakey in 1955 [5].

The combination of low incidence rate and its clinical mimicry of multiple other common diagnoses contribute to the difficulty in establishing the diagnosis of AD. In a nationwide population-based

study of more than 14,000 patients in Sweden between 1987 and 2002, where autopsies were obligatory for all unexpected deaths, only 78% of thoracic aortic aneurysm and dissection diagnoses were made before death [6]. From an ED perspective, a high index of suspicion for AD must be maintained, considering the diagnosis in high-risk patients presenting with unexplained chest or back pain and suspicious physical examination findings. Making a timely diagnosis and instituting appropriate medical and surgical therapy are essential to improve survival in these patients. This review discusses epidemiological aspects, risk factors, classification schemes, clinical presentations, diagnostic modalities, and standard-of-care medical and surgical treatment options for acute AD.

Definitions and Classification

Acute aortic syndrome encompasses a spectrum of life-threatening aortic conditions with pathologic overlap, with severity of characteristic symptoms and rapid mortality risk in common. Acute aortic syndromes typically include AD, aortic intramural hematoma, and penetrating atherosclerotic ulcer (Figure 1). AD implies the formation of an intimal tear with separation in the media and subsequent antegrade blood flow into the false lumen. AD is present in approximately 90% of acute aortic syndromes. Localized bleeding in the aortic wall thought to occur from the vasa vasorum without evidence of intimal tear is known as an intramural hematoma; this occurs in 5 to 10% of acute aortic syndromes. Penetrating atherosclerotic ulcers are the rarest form of acute aortopathy. Penetrating ulcers typically occur when pre-existing atherosclerotic plaques acutely ulcerate and erode through the internal elastic lamina into the aortic media.

The DeBakey and Stanford classification systems for AD were based on anatomical description of the location and extent of the dissection flap (Figure 2). In the simpler and more commonly used Stanford classification, type A dissections involve the ascending aorta (regardless of the site of the primary intimal tear) while type B dissections include all other anatomic aortic locations beyond the

ascending aorta. In the DeBakey classification scheme, type I dissections involve the ascending aorta with distal extension; type II dissections are limited to the ascending aorta alone; and type III dissections are limited to the descending aorta (type IIIa dissections are confined to the descending thoracic aorta while type IIIb extend to the abdominal aorta). These classifications systems allow for a standard language in describing aortic pathology, and also reflect the importance of anatomic location of AD in dictating treatment and determining prognosis.

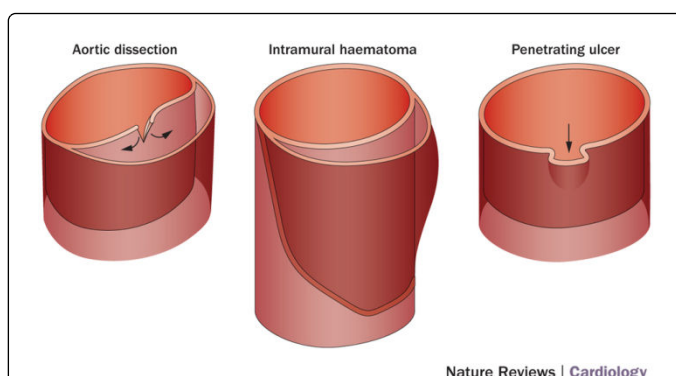


Figure 1: Acute aortic syndrome subtypes: (A): Aortic dissection with an associated intimal flap, (B) aortic intramural hematoma with an intact intima and (C) penetrating atherosclerotic ulcer. (Reprinted with permission, Nature Publisher Group).

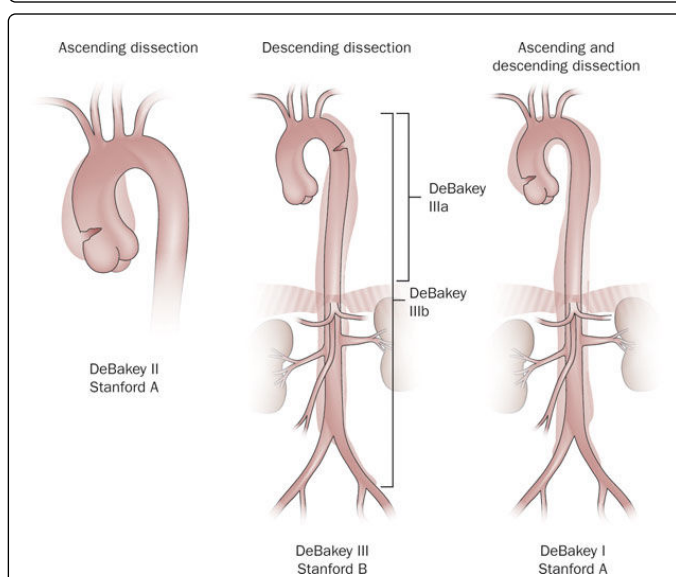


Figure 2: Classification scheme of aortic dissection, with the Stanford and the associated DeBakey type listed for each illustration. (Reprinted with permission, Nature Publisher Group).

Epidemiology

AD of the ascending aorta is twice as common as descending AD. Ascending AD occurs most commonly in patients between the ages of 50 and 60 years, while descending AD has a slightly later onset between 60 and 70 years. Determining true disease prevalence of AD is

challenging as many patients present with sudden death prior to first medical encounter. In the United States and Western Europe, the incidence of AD has been approximated to range between 2.9 and 3.5 cases per 100,000 person-years [7,8]. In the past several decades, there has been a notable increase in reported incidence of thoracic aortic disease (aneurysms and/or dissections) – though it is unclear if this is a consequence of better diagnostic imaging, disease recognition, or a true change in disease epidemiology. The Swedish population, in which autopsies are routinely required on all unexpected out-of-hospital deaths, gives the most accurate estimate of the overall incidence of AD. There was a reported 52% increase in the incidence of thoracic aortic aneurysm and dissection in Swedish men between 1987 and 2002 (from 10.7 per 100,000 per year in 1987 to 16.3 per 100,000 per year in 2002) [6]. In England and Wales, admission for thoracic AD increased from ~ 10 to ~ 12 per 100,000 in individuals 75 ≥ years old from 1999-2001 to 2008-2010 [9], with parallel increases among younger adults, and in other areas [10]. Wittram et al. [11] retrospectively investigated the use of thoracic imaging modalities (chest radiographs, chest CT, pulmonary angiograms, chest and cardiac MRIs and FDG-PET scans) between 1992 and 2011 at a large tertiary care center. They documented a significant increase in thoracic imaging use over the past two decades. In the Oxford Vascular Study (OXVASC), Howard et al. [12] reviewed mortality cause in 92,728 cases from Oxfordshire, UK. They concluded that hospital-based data underestimated the true incidence of AD, as approximately 50% of patients with acute AD died out-of-hospital. Improvements in emergency medical services may contribute to the reported rise in incidence of AD.

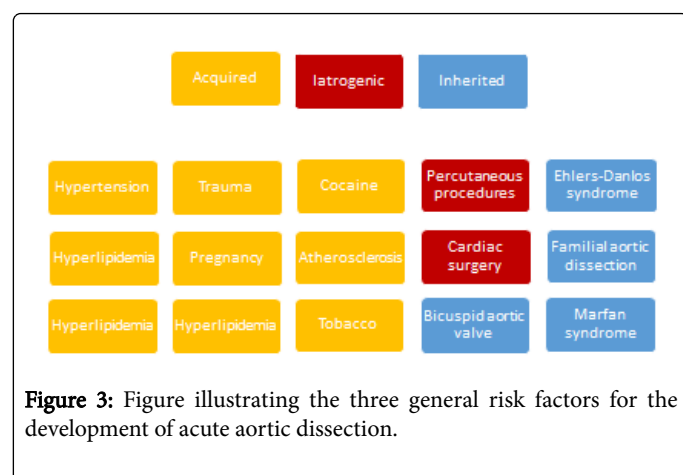
Given the relatively low numbers in most individual institutions, a multicenter, multinational collaboration was established in 1996 to study AD through the International Registry of Acute Aortic Dissection (IRAD). An IRAD review of 1078 patients with AD found that ~ 32% of patients were women and that women with AD were older than men, with 50% of women and 29% of men were ≥ 70 years old [13].

Pathophysiology and risk factors

The wall of the aorta has three components: intima, media, and adventitia. There are two leading theories regarding the primary pathological changes of AD [14]. The first ascribes primacy to the development of an intimal tear, followed by penetration of blood from the aortic lumen into a weakened, susceptible medial space (characterized by elastic degeneration and smooth muscle cell loss). The second hypothesis is that initial rupture of the vasa vasorum leads to hemorrhage within the aortic wall and subsequent intimal disruption and propagation of a dissection flap. AD usually propagates in an antegrade fashion, due to the pressure waveform propagating from the left ventricle through the aorta, though retrograde dissections can occur. Distention of the false lumen with blood causes compression of the true lumen leading to under-perfusion of vital organs and subsequent clinical adverse events. Life-threatening clinical complications of AD include development of pericardial effusion causing tamponade, frank exsanguination from aortic rupture, or malperfusion syndromes such as disruption of coronary artery flow, cerebrovascular accident, mesenteric ischemia, ischemic colitis, or spinal ischemia.

Risk factors for the development of AD can be divided into acquired, iatrogenic, and inherited categories (Figure 3). The two most important acquired risk factors are hypertension (present in ~ 75%) [15,16] and atherosclerosis (present in ~ 30%) [4]. Hypertension [17],

amphetamine abuse/dependency [18], pregnancy [19], and high-intensity weightlifting or heavy-exercise [20] are all acquired conditions that increase the intra-aortic pressure or stroke volume and can weaken the arterial wall predisposing to acute AD. Hypertension is a more common finding in patients with type B dissections (70%) than in type A dissections (36%) [4]. Tobacco use [21] and hyperlipidemia are additional risk factors for AD by promoting medial wall degeneration (through breakdown of collagen and elastin) with increased risk for aortic disruption. Furthermore, increased heart rate, primarily governed by the Hyperpolarization and Cyclic Nucleotide gated channel 4 (HCN4), has been suggested to increase cardiovascular risk, primarily through endothelial shear stress and activation of biochemical pathways, and could play a role in the development of aortic dissections [22,23].



Genetic diseases and connective tissue disorders play a large role in AD prevalence. Syndromes such as Marfan, Ehlers-Danlos, Loeys-Dietz, familial aortic dissection, and annulo-aortic ectasia are all implicated in the development of thoracic aortic aneurysm and dissection [24]. Patients with Marfan syndrome and an aortic diameter 5.0 - 5.4 cm have an annual risk of AD or death >1%, which rises to ~8% annually for aortic diameters ≥ 5.5 cm [25]. AD is six times more common in Turner syndrome than in the general population, and accounts for approximately 8% of all Turner syndrome deaths [26]. Many forms of congenital heart disease are linked with aortic aneurysm development and variable risk for AD – particularly in patients with bicuspid aortic valves and/or aortic coarctation [27]. Aortopathies associated with congenital heart disease and cystic medial necrosis include persistent truncus arteriosus, transposition of the great arteries, hypoplastic left heart syndrome, and Tetralogy of Fallot [28,29].

Finally, iatrogenic AD is a rare occurrence, accounting for approximately 5% of all AD, and is estimated to occur in 0.02% of cardiac catheterization procedures, with a higher incidence during percutaneous coronary intervention (0.03%) than during elective diagnostic procedures (<0.01%) [30]. Incidence after percutaneous placement of an intra-aortic balloon pump has been estimated to be ~0.9 – 4% [31,32]. Patients with open-heart surgery have an increased risk of iatrogenic AD with on-pump (~0.04%), off-pump CABG (~1%) [33] or previous aortic valve replacement (~5%) [16]; these are typically type A ADs [34].

Clinical Manifestations

Clinical manifestations of AD can be variable and may mimic those of more common diseases, emphasizing the importance of a high index of suspicion. The importance of history taking in making the diagnosis of AD was highlighted in a retrospective chart review of 83 patients who had confirmed diagnoses of AD [35]. When patients were asked about the [1] quality [2], location [3] and onset of their pain, 91% of patients were correctly suspected of having AD, while only 49% of patients were suspected of carrying the diagnosis if less than three of these elements were asked.

Sudden onset of severe, sharp chest pain is the classic presenting symptom in type A dissections (79% versus 63 % in patients with type B dissection). Type B dissections are more commonly associated with abdominal pain (43% versus 22%) and back pain (64% versus 47%) than type A dissections. Most patients presenting with acute AD describe their pain as “sharp” or “stabbing” and less commonly as “tearing” or “ripping” [4]. Some patients can present with symptoms due to complications of the dissection, such as myocardial infarction, heart failure, syncope, or focal neurological deficits that may mask the underlying pathology and result in delays in establishing the correct diagnosis. Painless AD has been observed to occur in ~6% of patients with AD [36]. Patients with painless AD are typically older, and tend to carry a prior history of diabetes mellitus, aortic aneurysm, or cardiovascular surgery. Patients with painless AD have significantly higher in-hospital mortality compared to patients who experience pain. Iatrogenic AD, on the other hand, often does not present with the classic symptoms of dissection (chest or abdominal pain). Similar to patients with painless AD, patients with iatrogenic AD tend to be older with a higher prevalence of risk factors for vascular disease, reflective of selection bias.

Gender differences have been noted in patients presenting with AD. Women are more likely to present with complications of heart failure or altered mental status and less likely to present with abrupt onset chest or back pain compared to men [37]. Gender and cultural differences in perception and communication of pain add to the challenge of diagnostic accuracy.

Physical examination findings are present in less than 50% of patients with thoracic AD [38]. The presence of a diminished or absent pulse in certain vascular beds, such as carotid, brachial or femoral arteries results from compression of the true lumen by blood in the false lumen, and has been observed in 19% to 30% of patients with type A dissection and 9% to 21% in patients with type B dissections. The presence of a unilateral pulse deficit in a vascular bed has a positive likelihood ratio (LR) of 5.7 (95% CI 1.4 – 23.0) for the presence of an AD [39,40].

Other physical examination findings that can suggest the diagnosis of AD include:

Focal neurological deficits (positive LR of 6.6 – 33.0) or altered sensorium due to cerebral hypoperfusion. Neurologic manifestations occur in 17% to 40% of patients with AD and, as expected, are more common with type A dissections. In addition, up to 50% of neurologic deficits are transient. Neurological syndromes include transient ischemic attacks, spinal cord ischemia leading to paralysis, ischemic neuropathy, hypoxic encephalopathy, syncope, and seizures [41,42].

An early diastolic, decrescendo murmur typically best heard along the right sternal border suggestive of acute aortic valvular regurgitation associated with signs and symptoms of heart failure and/or

hemodynamic compromise. Aortic regurgitation may result from a number of mechanisms including incomplete valvular coaptation due to aortic root or annular dilatation, aortic leaflet prolapse due to extension of the dissection flap into the commissures causing commissural prolapse, large intimal flap prolapsing into the left ventricular outflow tract during diastole or a pre-existing acquired or genetically influenced condition such as a bicuspid aortic valve or aortic aneurysm that subsequently leads to the development of an AD. Unfortunately, the presence of a diastolic murmur has a positive LR of 1.4 and a negative LR of 0.9, indicating that it is not very useful in making the diagnosis of AD [39,40].

Pulsus paradoxus in addition to hemodynamic compromise in patients with hemo-pericardium and rupture of the aorta into the pericardial space. The development of hemo-pericardium complicates approximately ~ 9% of type A dissections and is associated with worse outcomes. In addition, acute pericarditis may develop with the characteristic symptoms and EKG changes [4,39,40].

Hypoxia, tachypnea, and decreased breath sounds associated with hemorrhage into the pleural space (hemothorax). In addition, AD may lead to the development of a left-sided pleural effusion in approximately 20% of patients, as a result of an inflammatory response.

Hoarseness due to compression of the left recurrent laryngeal nerve and subsequent vocal cord paralysis.

Ptosis, meiosis, and anhidrosis if there is compression of the superior cervical sympathetic ganglion.

EKG findings are not helpful in establishing the diagnosis of AD, as 7% of EKGs show ST-segment elevations or new Q waves, while normal EKGs are seen in 8% to 31% of patients with AD [39].

Von Kodolitsch et al. [40] investigated clinical predictors for the development of acute AD in 2137 German patients with type A AD. Aortic pain with immediate onset (described as a tearing or ripping sensation, or both), mediastinal widening, aortic widening (or both), pulse differential, blood pressure differential (or both) were all independent predictors of acute AD. The probability of dissection was low in the absence of all variables (7%), intermediate with isolated findings of aortic pain or mediastinal widening (31 – 39%), and high with isolated pulse or blood pressure differential or any combination of the clinical predictors ($\geq 83\%$).

Diagnostic Strategies

Laboratory studies

Although there are no firmly established, clinically available serum biomarker tests that are specific for AD, there is considerable interest in developing biomarkers that may aid in early diagnosis or exclusion of AD. In theory, measurement of serum levels of smooth muscle proteins, soluble elastin fragments, myosin heavy chain and creatine kinase-BB isoform could achieve that goal since circulation of blood in the medial space may result in release of such peptides into the systemic circulation [43,44]. Most recently, circulating transforming growth factor-beta levels has shown promise in distinguishing non-Marfan patients with AD [45].

The IRAD sub-study on biomarkers (IRAD-Bio) investigated the use of D-dimer, a fibrin degradation product of fibrinolysis, in ruling out acute AD. This was based on previous observations that the D-dimer level tends to be elevated in patients with acute AD. 220 patients

with initial suspicion for AD were followed prospectively, out of which 87 were confirmed to have AD and the remaining 133 patients had a different diagnosis (e.g. myocardial infarction, pulmonary embolism). D-dimer levels were markedly elevated in patients with AD, and when a cutoff level of 500 ng/mL was used to rule out AD, negative predictive value was $>90\%$ in the first 24 hours [46]. However, in patients with intermediate or high risk of having an AD, a negative D-dimer was not sufficient to rule out an AD. On the other hand, D-dimer did not perform well in ruling in AD, as it only had a positive predictive value of $<50\%$. This is explained by the fact that a normal D-dimer level could be seen in AD patients with a thrombosed false lumen, as well as patients with IMH and PAU. In addition, some patients present >24 hours of symptom onset, and as a result may have lower D-dimer levels.

Imaging

The key element in choosing an imaging modality is to obtain rapid and accurate confirmation of the diagnosis, minimizing delay to appropriate urgent therapy. Echocardiography and contrast-enhanced CT are the most commonly performed imaging modalities to assess AD. A review from IRAD showed that AD patients had multiple imaging studies performed on initial encounter, with a mean of 1.83 tests per patient. The initial study was computed tomography (CT) in 61%, trans-esophageal echocardiography (TEE) in 33%, aortography in 4% and magnetic resonance imaging (MRI) in 2% of patients [4,47]. When the pretest likelihood of AD is high and an initial imaging test is equivocal or negative, a second diagnostic test should be performed.

Other than establishing the diagnosis of AD, imaging modalities provide ancillary information of potential complications [48], including extent of dissection; sites of entry and reentry; presence of thrombus in the false lumen; branch vessel involvement, including coronary artery involvement; aortic valve involvement; and pericardial effusion.

Imaging - Chest radiograph

A chest radiograph is commonly the first imaging modality performed in the workup of an ED patient presenting with chest pain. Although chest radiographs may reveal classic findings of AD, in most instances it is non-diagnostic. Up to 15% of chest radiographs are normal in acute AD. The most common finding seen on chest radiograph is an abnormal aortic contour or widening of the aortic silhouette, which appears in 83% of type A and 72% of type B dissections [4]. The clinically rare “calcium sign” describes aortic knob calcification as a means to detect the separation of the calcified intima from the outer aortic wall edge.

Imaging – Echocardiography

Transthoracic echocardiography (TTE) and trans-esophageal echocardiography TEE play a central role in diagnosing AD. Despite its limited sensitivity, TTE has the advantage of being simple, rapid, and readily available in the ED. TTE has a reported sensitivity of 59% to 83% and a specificity of 63% to 93% for the diagnosis of AD [49]. These numbers are based on dated studies and contemporary numbers investigating improved imaging transducers and enhanced processing are needed. TTE has higher sensitivity in diagnosing type A (78% – 100%) compared to type B dissections (31% – 55%). Nevertheless, TTE is operator dependent, and there is a significant variability of image

quality due to body habitus, patient position, or respiratory status that make it an unreliable test in ruling out AD.

Even when TTE fails to visualize a dissection flap, it can provide important information regarding associated findings that could increase suspicion for AD: presence of aortic insufficiency, inferior wall hypokinesis (indicating right coronary artery involvement), presence of pericardial effusion, or a dilated ascending aorta or aortic root. In patients in whom a dissection flap is visualized, TTE can help stratify high-risk patients: patients with proximal root involvement and associated pericardial effusion suggestive of imminent rupture.

TEE offers direct visualization of all segments of the thoracic aorta in addition to direct visualization of branch vessels. It has reported sensitivity of 94% – 100% and specificity of 77% – 100% for identifying an intimal flap [50,51]. The lower described specificity of TEE in early studies relates to the false-positive interpretation of reverberation artifacts in the aorta [47]. In 2006, Shiga et al. [50] systematically reviewed the diagnostic accuracy of TEE, CT, and MRI in patients with suspected thoracic AD. They pooled sixteen studies with a total of 1,139 patients, and found a comparable pooled sensitivity (98% - 100%) and specificity (95% - 98%) between the three imaging modalities. As a result, the authors suggested that if a patient had a 50% pretest likelihood of having a dissection (stratified as a high-risk patient), a positive result using either imaging modality would translate into a 93% to 96% post-test probability of having a thoracic AD, and if a patient had a 5% pretest likelihood (stratified as a low-risk patient) of disease, then a negative result would translate into a 0.1% to 0.3% post-test probability of having a dissection.

Imaging - Contrast-Enhanced Computed Tomography

Contrast-enhanced CT is the modality used most frequently for examining the aortic wall for an intimal flap due to its diagnostic accuracy and the rapidity with which it can be obtained. It is highly sensitive in distinguishing between the three subtypes of acute aortic syndrome. EKG-gated, multi-detector scanners tend to be most accurate as a result of elimination of pulsation motion artifacts [52]. In addition, spiral contrast CT allows for three-dimensional reconstruction in order to evaluate for branch vessel involvement, a critical step when planning surgery. Malperfusion of the arch vessels, abdominal viscera and lower extremities is easily discernable with CT angiography. The radiographic features required to establish the diagnosis of AD on CT are either the presence of two distinct lumens with a visible intimal flap (most common finding), or by detection of two lumens by differing rates of contrast material opacification. Intramural hematoma, on the other hand, appears as diffuse thickening of the aortic wall often with areas of contrast enhancement within the hematoma. In a retrospective study of 365 patients evaluated at the Massachusetts General Hospital ED, multi-detector row CT was found to have a sensitivity of 99% and a specificity of 100% [53]. Major limitations of CT include the inability to evaluate the aortic valve reliably, motion artifacts from cardiac movement and streak artifacts in patients with implanted devices, and the administration of contrast agents that have a potential risk of contrast-induced nephropathy.

Imaging - Magnetic Resonance Imaging

MRI has a similar sensitivity and specificity profile to that of contrast-enhanced CT in diagnosing AD, with the advantage of sparing the patient exposure to ionizing radiation. In addition, MRI

permits multiplanar imaging with 3-D reconstruction and cine-MRI, which results in better sensitivity for the detection of an intimal flap (88% sensitivity for MRI versus less than 75% sensitivity for CT) [49,50]. Furthermore, gadolinium-enhanced images can show slow flow from thrombus in the false lumen. However, MRI requires patients to lay motionless in a relatively unmonitored environment for a prolonged period of time, and as a result is usually not the procedure of first choice. Contrast-enhanced magnetic resonance angiography (MRA) has the additional advantage of significantly lower time for image acquisition while providing better imaging quality of the aorta and branch vessels [54].

Management

Despite its inherent challenges, diagnosis and treatment of acute aortic syndromes have improved over time, mainly driven by increased clinical experience and improvement in diagnostic modalities. DeBakey and colleagues were the first to establish surgical intervention as a treatment modality [55]; however in the initial years, there were discouraging surgical outcomes from other medical centers. Some groups, such as Wheat et al. [56] even recommended “avoiding surgical therapy” for some patients with acute AD.

In the 1970s, it became clear that there was a difference in patient prognosis depending upon whether the AD originates in the ascending aorta (Stanford A or DeBakey I-II) or in the descending aorta (Stanford B or DeBakey III). Appelbaum et al. [57] reviewed outcomes of 108 patients with spontaneous thoracic AD at the University of Alabama Hospital between 1966 and 1973. They found that the in-hospital mortality for patients with DeBakey type I-II AD treated medically was 88% compared with 32% in patients with type III dissections. Patients who underwent surgical intervention had 24% in-hospital mortality for type I-II dissection and 36% for type III dissections. Their conclusion was that surgical treatment had a significantly lower in-hospital mortality rate than medical therapy in patients with type I-II dissections ($p < 0.0002$) while patients with type III dissections had similar in-hospital mortality rates with either surgical or medical therapy. Contemporary data published by IRAD [58] evaluating outcomes in 384 patients with acute type B AD showed that in-hospital mortality was 32% for surgical patients compared with 10% for patients treated medically (as type B dissection is treated medically and surgery is reserved for patients with complication, hence partially explaining worsened outcomes). Chiappini et al. [59] analyzed outcomes in 487 patients with type A AD and found a 22% in-hospital mortality for patients treated surgically. In-hospital mortality for type A AD, with and without malperfusion, is even lower in hospitals with large volume aortic surgery, approaching 4 – 5% [60].

Evaluation for Coronary Artery Disease

Patients with acute AD often have coronary artery disease. The role of pre-operative coronary angiography and its effect on in-hospital mortality was investigated through a retrospective analysis of 122 patients who underwent emergency aortic surgery between 1982 and 1992 at the Cleveland Clinic [61]. In-hospital mortality was not significantly different between patients who underwent coronary angiography on the day of surgery compared with those who did not (22% versus 16% respectively, p value = 0.46). Furthermore, coronary angiography did not affect the incidence of coronary artery bypass grafting during aortic surgery (17% in patients who had coronary angiography versus 25% in patients who had not undergone angiography), explained by the fact that 74% of bypass grafting was

performed because of intra-operative evidence of coronary dissection, and not atherosclerotic coronary disease. As a result, management of AD should be initiated immediately once the diagnosis is established, without need for coronary angiography.

Ascending (type A) aortic dissection

Patients with a confirmed diagnosis of an ascending AD should be treated as a surgical emergency due to the high early mortality (mortality rate of 1% per hour over the first twenty-four hours [62] and increased rates of complications, such as aortic insufficiency and subsequent heart failure, cardiac tamponade, myocardial infarction, and aortic rupture. Figure 3 summarizes the 2010 ACCF/AHA/AATS/ACR/ASA/SCA/SCAI/SIR/STS/SVM guidelines for the management of acute AD [63].

Step 1: The initial step after stabilizing a patient is initiating an emergency transfer to a tertiary care medical facility with access to advanced imaging modalities and specialized care with in-house cardiothoracic surgery and other advanced surgical services

Step 2: Initial medical management is stratified according to hemodynamic status. In hemodynamically stable patients, initial therapy should be aimed at controlling pain (usually through the administration of opioids), lowering blood pressure (to a goal systolic blood pressure between 100 and 120 mmHg) and reducing myocardial contractility (with intravenous beta-blockers to a goal heart rate < 60 bpm)

Step 3: Lowering blood pressure and reducing the cardiac output may help prevent further propagation of the dissection and lower the risk for aortic rupture.

Patients who are hemodynamically unstable or with airway compromise should be urgently intubated, and an immediate workup for the cause of instability should be undertaken. TTE is usually the modality of choice, as it is quick, readily available, can be performed at the bedside and can rule out complications of proximal AD. Inotropic agents should be avoided since they will increase aortic wall shear stress and worsen the dissection. In addition, pericardiocentesis should be avoided in patients with cardiac tamponade. In a series of 10 patients with both proximal AD and cardiac tamponade [64], 4 patients underwent emergent pericardiocentesis for cardiac tamponade while awaiting surgical intervention. 5 to 40 minutes after the pericardiocentesis, 3 out of 4 patients (75%) experienced cardiac arrest and died, the fourth patient survived and underwent surgical repair. A proposed theory behind this finding is the possibility that an increased cardiac output, after alleviating the hemodynamic effects of cardiac tamponade, would cause an acute rise in systemic blood pressure and cause further extension of the dissection.

Goals of surgical intervention in type A dissections (Step 3) include reapproximation of the intimal flap to the adventitial layer, eradication of the false lumen, reconstitution of the aorta, and replacement of the entire ascending aorta with a synthetic vascular graft. In patients with aortic valvular insufficiency, restoration of aortic valvular competence can be achieved through re-suspension of the native valve commissures or aortic valve replacement. Furthermore, immediate aortic reconstruction coupled with peripheral intervention for persistent peripheral malperfusion resulting in restoration of antegrade blood flow in patients with type A AD and pre-operative end-organ malperfusion has been shown to further improve in-hospital outcomes [60].

The ESC guidelines published in 2014 [65] and the ACC/AHA guidelines published in 2010 [63] agree that thoracic endovascular aortic repair (TEVAR) should be reserved for treatment of complicated type B AD. However, the ESC guidelines place greater emphasis on the use of TEVAR in patients with uncomplicated type B AD, with a Class IIa recommendation (weight of evidence/opinion is in favor of usefulness/efficacy) compared with the ACC/AHA class IIb recommendation (usefulness/efficacy is less well established by evidence/opinion). Furthermore, both European and North American guidelines give TEVAR a class I recommendation in patients with traumatic aortic injury and suitable anatomy. Patients with Marfan syndrome or other genetic conditions have been excluded from TEVAR trials, but this therapy has been beneficial in patients at extreme risk for conventional surgery.

Open Surgery

A median sternotomy is generally performed, followed by cannulation of the axillary or femoral artery for cardiopulmonary bypass. Recent trials investigating transapical aortic cannulation found identical post-operative mortality and morbidity compared to femoral cannulation with the advantage of easier and faster cannulation [66].

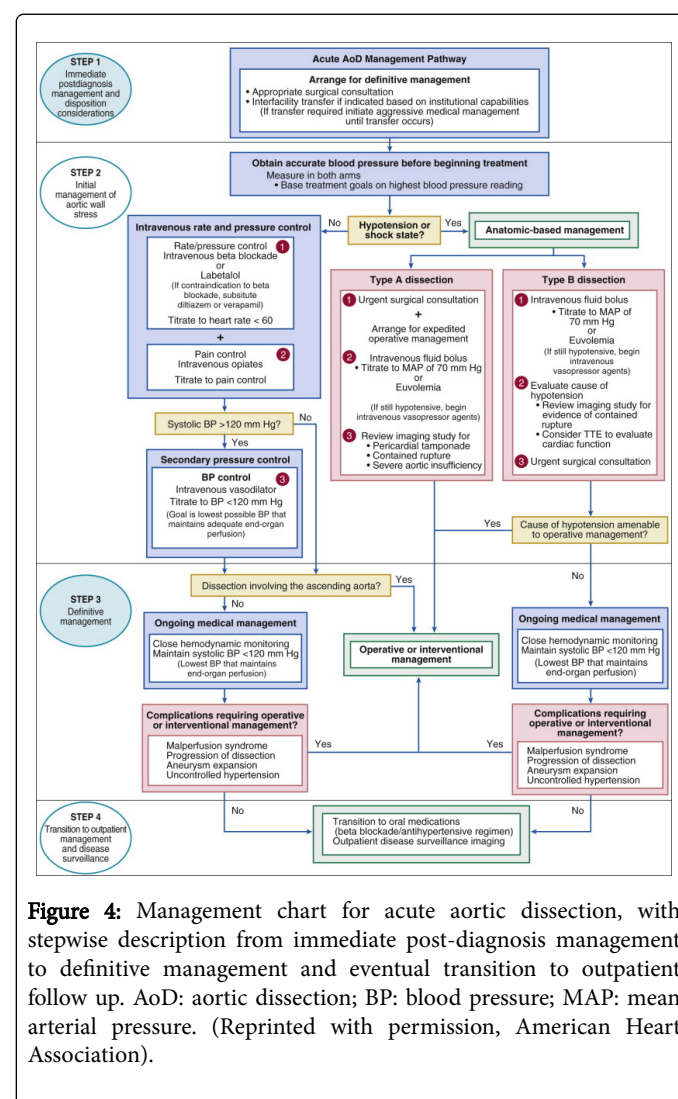


Figure 4: Management chart for acute aortic dissection, with stepwise description from immediate post-diagnosis management to definitive management and eventual transition to outpatient follow up. AoD: aortic dissection; BP: blood pressure; MAP: mean arterial pressure. (Reprinted with permission, American Heart Association).

Access to the true lumen must be ensured as perfusion into the false lumen would likely cause severe malperfusion and circulatory collapse. The patient is then actively cooled in preparation for deep hypothermic circulatory arrest in order to reconstruct the aorta. The most conservative approach, with the lowest reported peri-operative risk, is isolated supra-commissural replacement of the ascending aorta (Figure 4A). The disadvantage is that that pure ascending aorta replacement increases the risk of later complications such as aneurysmal dilatation of the remaining aorta, in addition to the fact that the arch vessels are less well protected [67]. Dissections extend into the aortic arch in > 70% of patients with acute ascending aorta dissections [68], in which case a hemi-arch replacement is usually the surgery of choice (Figure 4B); the distal graft edge is resected with a bevel, replacing the inner curvature of the arch, which typically contains the primary tear, while preserving the continuity of the supra-aortic branch vessels with the descending aorta. Total arch replacement (Figure 4C) requires re-implantation of the supra-aortic vessels as a single patch or less commonly as separate branches. The trifurcated graft technique (Figure 4D) is a successful alternative for aortic arch re-construction with the goal of minimizing brain ischemic time [69]. Initially, the right subclavian artery is cannulated, followed by a short period of circulatory arrest. Subsequently, the supra-aortic vessels are anastomosed to a trifurcated graft. Finally, the aortic arch is replaced while the brain is perfused through the graft. The frozen elephant trunk, which is an extension of the aortic arch replacement, involves implantation of a stent-graft-reinforced hybrid prosthesis into the descending thoracic aorta for anastomosis to a subsequent descending aortic graft [70].

Descending (type B) aortic dissection

Patients with uncomplicated dissection of the descending aorta (Stanford type B or DeBakey type III) are treated with medical therapy, unless there are signs of persistent or recurrent pain, early expansion, malperfusion of peripheral organs or rupture (Class I) [62]. Medical therapy in patients with acute type B AD should begin with intravenous beta-blockers such as labetalol (20 mg bolus, followed by 20 to 80 mg every 10 minutes for a total dose of 300 mg or an infusion of 0.5 to 2 mg/min). Non-dihydropyridine calcium channel blockers (such as verapamil or diltiazem) are alternatives in patients with contraindications for beta-blockers (Class IC). Beta-blockers should be used with great caution in patients with acute onset severe aortic insufficiency as they can cause hemodynamic instability due to blocking of compensatory tachycardia. If, despite aggressive heart rate control, systolic blood pressure remains greater than 120 mmHg, then intravenous vasodilators such as nitroprusside (at a dose of 0.25 to 0.5 mcg/Kg/min) or an intravenous angiotensin converting enzyme inhibitor should be used to further lower blood pressure (Class IC). Intravenous vasodilators should not be used prior to aggressive heart rate control due to the development of reflex tachycardia and increased aortic wall stress (Class IIIC).

In a series of 384 patients enrolled in IRAD [58], 56 patients (15%) had received surgical intervention, 45 patients (12%) received percutaneous intervention, while 282 patients (73%) received medical therapy. In-hospital mortality was significantly higher in patients undergoing surgical intervention (32%, p -value <0.0001) compared to medical therapy (10%) and percutaneous intervention (7%).

Thoracic Endovascular Aortic Repair

Percutaneous treatment for patients with type B AD is a rapidly increasing. Endovascular grafts can be used to treat most complications of type B dissections with relatively low adverse surgical outcomes [71]. The reasoning behind the use of this technique is that covering the area of the primary intimal flap with the endovascular graft prevents circulating blood from entering the false lumen, and as a result, leads to thrombosis and remodeling of the false lumen (Figure 5).

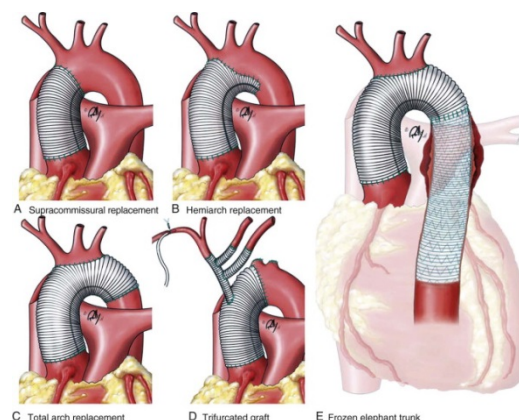


Figure 5: Surgical treatment options for acute ascending aortic dissection. (A) Supra-commissural replacement of the ascending aorta. (B) Hemi-arch replacement. (C) Total arch replacement. (D) Trifurcated graft technique. (E) Frozen elephant trunk procedure. (Reprinted with permission, Elsevier Inc.).

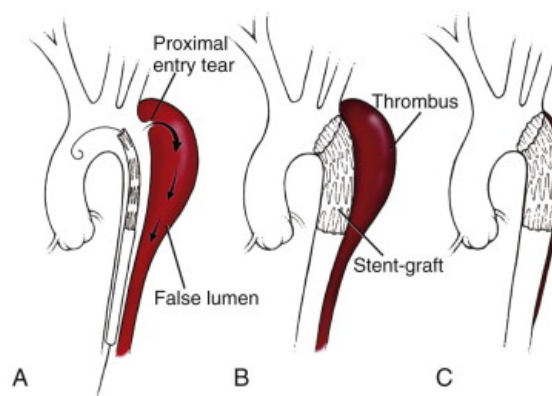


Figure 6: Illustration of the steps in endovascular repair of a descending aortic dissection associated by an expanding false lumen: (A) An endograft is advanced to cover the proximal entry site, (B) sealing of the entry site leads to halting of antegrade blood flow and thrombosis of the false lumen, (C) subsequent remodeling of the aorta due to expansion of the true lumen and shrinkage of the thrombosed false lumen. (Reprinted with permission, Elsevier Inc.).

However, up to two-thirds of patients treated with endovascular stenting have persistence of a perfused false lumen via distal fenestrations that are inevitably present (Figure 6). These may later

require re-intervention with open surgery. Retrograde ascending AD is a potentially early but lethal complication of thoracic endovascular aortic repair, with 33% 30-day in-hospital mortality [72]. Patients with uncomplicated type B dissection treated with endovascular grafting experience fewer late adverse events than those treated with medical therapy, without differences in 5-year mortality rates [73]. This finding was further confirmed in the INSTEAD trial [74] and the INSTEAD-XL (5-year follow up) [75] showed positive effect of TEVAR on aortic remodeling but no difference in clinical outcomes and mortality (at 2 years, survival in the medical arm was $95.6 \pm 2.5\%$ versus $88.9 \pm 3.7\%$ in the TEVAR arm, $p = 0.15$).

Hypertension is a common finding in the post-intervention period in patients with acute AD, and is a predictor of late complications [76]. Recent trials investigating renal sympathetic denervation in hypertensive patients after endovascular therapy for AD achieved significant and sustained reductions in systolic and diastolic blood pressure without significant complications [77].

Conclusions

AD, the most common subtype of acute aortic syndrome, is a rapidly lethal though infrequent clinical presentation in the emergency department. Although most patients present with typical aortic pain, many can present with atypical features or even remain asymptomatic, which can delay institution of appropriate therapy? Multiple imaging modalities that is available to confirm the diagnosis – though echocardiography and CT are most commonly utilized. The imaging preference should depend on the experience of the institution, availability, and hemodynamic stability of the patient. In general, acute AD involving the ascending aorta (Stanford type A or DeBakey type I-II) are considered surgical emergencies. Dissections confirmed to the descending aorta (Stanford type B or DeBakey type III) are treated medically, unless there is evidence of end organ ischemia from malperfusion or continued hemorrhage into the pleural or retroperitoneal space, for which surgical and endovascular options are available.

References

- Gerber TC, Kontos MC, Kantor B (2010) Emergency department assessment of acute-onset chest pain contemporary approaches and their consequences. *Mayo Clin Proc* 85:309-13.
- Owens PL, Barrett ML, Gibson TB, Andrews RM, Weinick RM, et al. (2010) Emergency department care in the United States: a profile of national data sources. *Ann Emerg Med* 56: 150-165.
- Fass R, Achem SR (2011) Noncardiac chest pain: epidemiology, natural course and pathogenesis. *J Neurogastroenterol Motil* 17: 110-123.
- Hagan PG, Nienaber CA, Isselbacher EM, Bruckman D, Karavite DJ, et al. (2000) The International Registry of Acute Aortic Dissection (IRAD): new insights into an old disease. *JAMA* 283: 897-903.
- Svensson LG, Crawford ES (1997) Cardiovascular and Vascular Disease of the Aorta Philadelphia. PA WB Saunders Co 1-6.
- Olsson C, Thelin S, Ståhle E, Ekblom A, Granath F (2006) Thoracic aortic aneurysm and dissection: increasing prevalence and improved outcomes reported in a nationwide population-based study of more than 14,000 cases from 1987 to 2002. *Circulation* 114: 2611-2618.
- Mészáros I, Mórocz J, Szlávi J, Schmidt J, Tornóci L, et al. (2000) Epidemiology and clinicopathology of aortic dissection. *Chest* 117: 1271-1278.
- Clouse WD, Hallett JW Jr, Schaff HV, Spittell PC, Rowland CM, et al. (2004) Acute aortic dissection: population-based incidence compared with degenerative aortic aneurysm rupture. *Mayo Clin Proc* 79: 176-180.
- von Allmen RS, Anjum A, Powell JT (2013) Incidence of descending aortic pathology and evaluation of the impact of thoracic endovascular aortic repair: a population-based study in England and Wales from 1999 to 2010. *Eur J Vasc Endovasc Surg* 45: 154-159.
- Pacini D, Di Marco L, Fortuna D, Belotti LM, Gabbieri D, et al. (2013) Acute aortic dissection: epidemiology and outcomes. *Int J Cardiol* 167: 2806-2812.
- Wittram C, Meehan MJ, Halpern EF, Shepard JA, McLoud TC, et al. (2004) Trends in thoracic radiology over a decade at a large academic medical center. *J Thorac Imaging* 19: 164-170.
- Howard DP, Sideso E, Handa A, Rothwell PM (2014) Incidence, risk factors, outcome and projected future burden of acute aortic dissection. *Ann Cardiothorac Surg* 3: 278-284.
- Nienaber CA, Fattori R, Mehta RH, Richartz BM, Evangelista A, et al. (2004) Gender-related differences in acute aortic dissection. *Circulation* 109: 3014-3021.
- Mann DL, Zipes DP, Libby P, Bonow RO, Braunwald E (2015) Braunwald's Heart Disease A Textbook of Cardiovascular Medicine (10th ed.). Philadelphia, PA Saunders, 57.
- Braverman AC (2010) Acute aortic dissection: clinician update. *Circulation* 122: 184-188.
- Januzzi JL, Isselbacher EM, Fattori R, Cooper JV, Smith DE, et al. (2004) Characterizing the young patient with aortic dissection: results from the International Registry of Aortic Dissection (IRAD). *J Am Coll Cardiol* 43: 665-669.
- Tolenaar JL, Froehlich W, Jonker FH1, Upchurch GR Jr1, Rampoldi V1, et al. (2014) Predicting in-hospital mortality in acute type B aortic dissection: evidence from International Registry of Acute Aortic Dissection. *Circulation* 130: S45-50.
- Westover AN, Nakonezny PA (2010) Aortic dissection in young adults who abuse amphetamines. *Am Heart J* 160: 315-321.
- Nasiell J, Norman M, Lindqvist PG, Malmstedt J, Bottinga R, et al. (2009) Aortic dissection in pregnancy: a life-threatening disease and a diagnosis of worth considering. *Acta Obstet Gynecol Scand* 88: 1167-1170.
- Hatzaras I, Tranquilli M, Coady M, Barrett PM, Bible J, et al. (2007) Weight lifting and aortic dissection: more evidence for a connection. *Cardiology* 107: 103-106.
- Takeuchi T, Adachi H, Ohuchida M, Nakamura T, Satoh A, et al. (2004) A case-control study found that low albumin and smoking were associated with aortic dissection. *J Clin Epidemiol* 57: 386-391.
- Scicchitano P, Carbonara S, Ricci G, Mandurino C, Locorotondo M, et al. (2012) HCN channels and heart rate. *Molecules* 17: 4225-4235.
- Scicchitano P, Cortese F1, Ricci G1, Carbonara S1, Moncelli M1, et al. (2014) Ivabradine, coronary artery disease, and heart failure: beyond rhythm control. *Drug Des Devel Ther* 8: 689-700.
- Halme T, Savunen T, Aho H, Vihersaari T, Penttinen R (1985) Elastin and collagen in the aortic wall: changes in the Marfan syndrome and annuloaortic ectasia. *Exp Mol Pathol* 43: 1-12.
- Jondeau G, Detaint D, Tubach F, Arnoult F, Milleron O, et al. (2012) Aortic event rate in the Marfan population: a cohort study. *Circulation* 125: 226-232.
- Turtle EJ, Sule AA2, Webb DJ3, Bath LE4 (2015) Aortic dissection in children and adolescents with Turner syndrome: risk factors and management recommendations. *Arch Dis Child* 100: 662-666.
- Michelena HI, Khanna AD, Mahoney D, Margaryan E, Topilsky Y, et al. (2011) Incidence of aortic complications in patients with bicuspid aortic valves. *JAMA* 306: 1104-1112.
- Niwa K (2013) Aortopathy in Congenital Heart Disease in Adults: Aortic Dilatation with Decreased Aortic Elasticity that Impacts Negatively on Left Ventricular Function. *Korean Circ J* 43: 215-220.
- Niwa K, Perloff JK, Bhuta SM, Laks H, Drinkwater DC, et al. (2001) Structural abnormalities of great arterial walls in congenital heart disease: light and electron microscopic analyses. *Circulation* 103: 393-400.

30. Wyss CA, Steffell J, Lüscher TF (2008) Isolated acute iatrogenic aortic dissection during percutaneous coronary intervention without involvement of the coronary arteries. *J Invasive Cardiol* 20: 380-382.
31. Meco M, Gramegna G, Yassini A, Bellisario A, Mazzaro E, et al. (2002) Mortality and morbidity from intra-aortic balloon pumps. Risk analysis. *J Cardiovasc Surg (Torino)* 43: 17-23.
32. Hurwitz LM, Goodman PC (2005) Intraaortic balloon pump location and aortic dissection. *AJR Am J Roentgenol* 184: 1245-1246.
33. Chavanon O, Carrier M, Cartier R, Hébert Y, Pellerin M, et al. (2001) Increased incidence of acute ascending aortic dissection with off-pump aortocoronary bypass surgery? *Ann Thorac Surg* 71: 117-121.
34. Januzzi JL, Sabatine MS, Eagle KA, Evangelista A, Bruckman D, et al. (2002) Iatrogenic aortic dissection. *Am J Cardiol* 89: 623-626.
35. Rosman HS, Patel S, Borzak S, Paone G, Retter K (1998) Quality of history taking in patients with aortic dissection. *Chest* 114: 793-795.
36. Park SW, Hutchison S, Mehta RH, Isselbacher EM, Cooper JV, et al. (2004) Association of painless acute aortic dissection with increased mortality. *Mayo Clin Proc* 79: 1252-1257.
37. Nienaber CA, Fattori R, Mehta RH, Richartz BM, Evangelista A, et al. (2004) Gender-related differences in acute aortic dissection. *Circulation* 109: 3014-3021.
38. Klompas M (2002) Does this patient have an acute thoracic aortic dissection? *JAMA* 287: 2262-2272.
39. Armstrong WF, Bach DS, Carey LM, Froehlich J, Lowell M, et al. (1998) Clinical and echocardiographic findings in patients with suspected acute aortic dissection. *Am Heart J* 136: 1051-1060.
40. von Kodolitsch Y, Schwartz AG, Nienaber CA (2000) Clinical prediction of acute aortic dissection. *Arch Intern Med* 160: 2977-2982.
41. Conzelmann LO, Hoffmann I, Blettner M, Kallenbach K, Karck M, et al. (2012) Analysis of risk factors for neurological dysfunction in patients with acute aortic dissection type A: data from the German Registry for Acute Aortic Dissection type A (GERAADA). *Eur J Cardiothorac Surg* 42: 557-565.
42. Sullivan PR, Wolfson AB, Leckey RD, Burke JL (2000) Diagnosis of acute thoracic aortic dissection in the emergency department. *Am J Emerg Med* 18: 46-50.
43. Suzuki T, Katoh H, Tsuchio Y, Hasegawa A, Kurabayashi M, et al. (2000) Diagnostic implications of elevated levels of smooth-muscle myosin heavy-chain protein in acute aortic dissection. The smooth muscle myosin heavy chain study. *Ann Intern Med* 133: 537-541.
44. Suzuki T, Katoh H, Kurabayashi M, Yazaki Y, Nagai R (1997) Biochemical diagnosis of aortic dissection by raised concentrations of creatine kinase BB-isozyme. *Lancet* 350: 784-785.
45. Suzuki T, Trimarchi S, Sawaki D, Grassi V, Costa E, et al. (2011) Circulating transforming growth factor-beta levels in acute aortic dissection. *J Am Coll Cardiol* 58: 775.
46. Suzuki T, Distant A, Zizza A, Trimarchi S, Villani M, et al. (2009) Diagnosis of acute aortic dissection by D-dimer: the International Registry of Acute Aortic Dissection Substudy on Biomarkers (IRAD-Bio) experience. *Circulation* 119: 2702-2707.
47. Tsai TT, Nienaber CA, Eagle KA. Acute aortic syndromes. *Circulation* 2005;112:3802.
48. Cigarroa JE, Isselbacher EM, DeSanctis RW, Eagle KA (1993) Diagnostic imaging in the evaluation of suspected aortic dissection. Old standards and new directions. *N Engl J Med* 328: 35-43.
49. Meredith EL, Masani ND (2009) Echocardiography in the emergency assessment of acute aortic syndromes. *Eur J Echocardiogr* 10: i31-39.
50. Shiga T, Wajima Z, Apfel C, Inoue T, Ohe Y (2006) Diagnostic accuracy of transoesophageal echocardiography, helical computed tomography, and magnetic resonance imaging for suspected thoracic aortic dissection systematic review and meta-analysis. *Arch Int Med* 166:1350-6.
51. Nienaber CA, von Kodolitsch Y, Nicolas V, Siglow V, Piepho A, et al. (1993) The diagnosis of thoracic aortic dissection by noninvasive imaging procedures. *N Engl J Med* 328: 1-9.
52. Schertler T, Glücker T, Wildermuth S, Jungius KP, Marincek B, et al. (2005) Comparison of retrospectively ECG-gated and nongated MDCT of the chest in an emergency setting regarding workflow, image quality, and diagnostic certainty. *Emerg Radiol* 12: 19-29.
53. Vasile N, Mathieu D, Keita K, Lellouche D, Bloch G, et al. (1986) Computed tomography of thoracic aortic dissection: accuracy and pitfalls. *J Comput Assist Tomogr* 10: 211-215.
54. Prince MR, Narasimham DL, Jacoby WT, Williams DM, Cho KJ, et al. (1996) Three-dimensional gadolinium-enhanced MR angiography of the thoracic aorta. *AJR Am J Roentgenol* 166: 1387-1397.
55. DEBAKEY ME, HENLY WS, COOLEY DA, MORRIS GC Jr, CRAWFORD ES, et al. (1965) SURGICAL MANAGEMENT OF DISSECTING ANEURYSMS OF THE AORTA. *J Thorac Cardiovasc Surg* 49: 130-149.
56. WHEAT MW Jr, PALMER RF, BARTLEY TD, SEELMAN RC (1965) TREATMENT OF DISSECTING ANEURYSMS OF THE AORTA WITHOUT SURGERY. *J Thorac Cardiovasc Surg* 50: 364-373.
57. Appelbaum A, Karp RB, Kirklin JW (1976) Ascending vs descending aortic dissections. *Ann Surg* 183: 296-300.
58. Suzuki T, Mehta RH, Ince H, Nagai R, Sakomura Y, et al. (2003) Clinical profiles and outcomes of acute type B aortic dissection in the current era: lessons from the International Registry of Aortic Dissection (IRAD). *Circulation* 108 Suppl 1: II312-317.
59. Chiappini B, Schepens M, Tan E, Dell' Amore A, Morshuis W, et al. (2005) Early and late outcomes of acute type A aortic dissection: analysis of risk factors in 487 consecutive patients. *Eur Heart J* 26: 180-186.
60. Girardi LN, Krieger KH, Lee LY, Mack CA, Tortolani AJ, et al. (2004) Management strategies for type A dissection complicated by peripheral vascular malperfusion. *Ann Thorac Surg* 77: 1309-1314.
61. Penn MS, Smedira N, Lytle B, Brener SJ (2000) Does coronary angiography before emergency aortic surgery affect in-hospital mortality? *J Am Coll Cardiol* 35:889-94.
62. HIRST AE Jr, JOHNS VJ Jr, KIME SW Jr (1958) Dissecting aneurysm of the aorta: a review of 505 cases. *Medicine (Baltimore)* 37: 217-279.
63. Hiratzka LE, Bakris GL, Beckman JA, Bersin RM, Carr VF, et al. (2010) American College of Cardiology Foundation/American Heart Association Task Force on Practice Guidelines; American Association for Thoracic Surgery; American College of Radiology; American Stroke Association; Society of Cardiovascular Anesthesiologists; Society for Cardiovascular Angiography and Interventions; Society of Interventional Radiology; Society of Thoracic Surgeons; Society for Vascular Medicine. 2010 ACCF/AHA/ATS/ACR/ASA/SCA/SCAI/SIR/STS/SVM guidelines for the diagnosis and management of patients with Thoracic Aortic Disease a report of the American College of Cardiology Foundation/American Heart Association Task Force on Practice Guidelines, American Association for Thoracic Surgery, American College of Radiology, American Stroke Association, Society of Cardiovascular Anesthesiologists, Society for Cardiovascular Angiography and Interventions, Society of Interventional Radiology, Society of Thoracic Surgeons, and Society for Vascular Medicine. *Circulation* 121: e266-369.
64. Isselbacher EM, Cigarroa JE, Eagle KA (1994) Cardiac tamponade complicating proximal aortic dissection. Is pericardiocentesis harmful? *Circulation* 90: 2375-2378.
65. Erbel R, Aboyans V, Boileau C, Bossone E, Bartolomeo RD, et al. (2014) 2014 ESC Guidelines on the diagnosis and treatment of aortic diseases: Document covering acute and chronic aortic diseases of the thoracic and abdominal aorta of the adult. The Task Force for the Diagnosis and Treatment of Aortic Diseases of the European Society of Cardiology (ESC). *Eur Heart J* 35: 2873-2926.
66. Suenaga E, Sato M, Fumoto H, Kawasaki H, Koga S (2015) Impact of Transapical Aortic Cannulation for Acute Type A Aortic Dissection. *Ann Thorac Cardiovasc Surg*.
67. Halstead JC, Meier M, Etz C, Spielvogel D, Bodian C, et al. (2007) The fate of the distal aorta after repair of acute type A aortic dissection. *J Thorac Cardiovasc Surg* 133: 127-135.

-
68. Ehrlich MP, Ergin MA, McCullough JN, Lansman SL, Galla JD, et al. (2000) Results of immediate surgical treatment of all acute type A dissections. *Circulation* 102: III248-252.
 69. Chen CC, Hsieh SR (2007) Modified trifurcated graft in acute type A aortic dissection with the least brain ischemic time. *Ann Thorac Surg* 83: e6-8.
 70. Sun L, Qi R, Zhu J, Liu Y, Zheng J (2011) Total arch replacement combined with stented elephant trunk implantation: a new "standard" therapy for type a dissection involving repair of the aortic arch? *Circulation* 123: 971-978.
 71. Slonim SM, Miller DC, Mitchell RS, Semba CP, Razavi MK, et al. (1999) Percutaneous balloon fenestration and stenting for life-threatening ischemic complications in patients with acute aortic dissection. *J Thorac Cardiovasc Surg* 117: 1118-1126.
 72. Williams JB, Andersen ND, Bhattacharya SD, Scheer E, Piccini JP, et al. (2012) Retrograde ascending aortic dissection as an early complication of thoracic endovascular aortic repair. *J Vasc Surg* 55: 1255-1262.
 73. Qin YL, Deng G, Li TX, Wang W, Teng GJ (2013) Treatment of acute type-B aortic dissection thoracic endovascular aortic repair or medical management alone JACC. *Cardiovasc Interv* 6185-6191.
 74. Nienaber CA, Rousseau H, Eggebrecht H, Kische S, Fattori R, et al. (2009) Randomized comparison of strategies for type B aortic dissection: the INvestigation of STEnt Grafts in Aortic Dissection (INSTEAD) trial. *Circulation* 120: 2519-2528.
 75. Nienaber CA, Kische S, Rousseau H, Eggebrecht H, Rehders TC, et al. (2013) Endovascular repair of type B aortic dissection: long-term results of the randomized investigation of stent grafts in aortic dissection trial. *Circ Cardiovasc Interv* 6: 407-416.
 76. Akin I, Kische S, Ince H, Nienaber CA (2009) Indication, timing and results of endovascular treatment of type B dissection. *Eur J Vasc Endovasc Surg* 37: 289-296.
 77. Divchev D, Turan G, Rehders T, Nienaber CA (2014) Renal sympathetic denervation in patients with aortic dissection. *J Interv Cardiol* 27: 334-339.