

A Combined Spinal Epidural Anesthetic (CSE) for Cesarean Section in a Patient with Achondroplasia. Can MRI be Helpful?

Antonio Gonzalez Fiol^{1*}, Mark Escudero², Sherelle Laifer-Narin² and Richard Smiley³

¹Department of Anesthesiology, New Jersey Medical School, Newark, USA

²Department of Radiology, Columbia University College of Physicians and Surgeons, Newark, USA

³Department of Anesthesiology, Columbia University College of Physicians and Surgeons, Newark, USA

*Corresponding author: Antonio Gonzalez Fiol, Department of Anesthesiology, Rutgers, New Jersey Medical School, 185 South Orange Ave., MSB E-538; Newark, NJ, 07103, Tel: 413-386-9415; Fax: 973-972-3835; E-mail: ajantoni@gmail.com

Received date: Dec 27, 2014, Accepted date: Jan 19, 2015, Published date: Jan 25, 2015

Copyright: © 2014 Fiol, et al. This is an open-access article distributed under the terms of the Creative Commons Attribution License, which permits unrestricted use, distribution, and reproduction in any medium, provided the original author and source are credited.

Abstract

The anatomic features of achondroplastic patients pose many challenges for anesthesiologists. The achondroplastic parturient has a high likelihood of delivery by cesarean section due to cephalopelvic disproportion. Hence, anesthesiologist involvement is crucial. It is not uncommon for these patients to have a narrow spinal canal and areas of spinal stenosis. These features might prove a challenge for a neuraxial technique and potentially result in unpredictable spread of local anesthetic. We present a case in which an abnormal Magnetic Resonance Imaging (MRI) was used to tailor the anesthetic plan for an achondroplastic parturient and possibly explain some of our intraoperative observations.

Keywords: Achondroplasia; Neuraxial anesthesia; MRI; Cesarean delivery; Anesthesia technique

Introduction

Achondroplasia is the most common form of non-lethal skeletal dysplasia, short-limb dwarfism. The achondroplastic parturient often poses a challenge to obstetric anesthesiologists. Difficulties during airway management for general anesthesia and regional anesthesia have been described. We present the management of an achondroplastic patient in which her antepartum lumbar spine MRI helped us to tailor our anesthetic plan and possibly to explain some of our intraoperative observations.

Case

A 35 year old nulliparous achondroplastic patient was referred to our high risk anesthesia consult service at 35 weeks gestational age. She denied any medical problems. She was 122 cm, 52 kg, with a Mallampati 2 airway, suitable mouth opening and full range of motion of the neck. No neurologic symptoms were elicited upon neck extension, and she denied any back pain, claudication symptoms or radiculopathy on the lower extremities. Cardiorespiratory exam was unremarkable. The patient's surgical history included an exploratory laparoscopy several years prior performed under general anesthesia using an awake fiberoptic intubation to secure the airway, with no attempt at direct laryngoscopy.

The patient was very interested in regional anesthesia for the scheduled cesarean delivery and for that reason an MRI of the lumbar spine without contrast had been ordered at 26 weeks gestational age, prior to her anesthetic consult. MRI findings were as follows: "Diffuse congenital spinal stenosis consistent with achondroplasia. Early degenerative disc disease at L1-L2. Severe central canal stenosis at L1-L2, L2-L3, moderate to marked central stenosis L3-L4, L4-L5 and mild stenosis at L5-S1; Right small posterior lateral epidural collection

identified from L1-L2 through L2-L3 of uncertain etiology." A chronic epidural hematoma or ruptured synovial cysts were considered as possibilities for this collection (Figure 1).

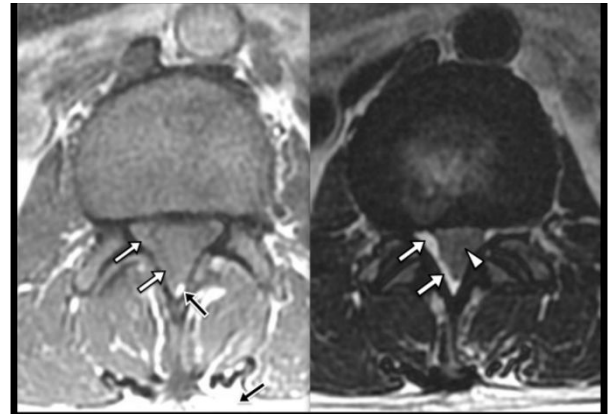


Figure 1: Magnetic Resonance Imaging- Axial T1 (left) and T2 (right) images obtained without fat saturation at the level of L1/L2 demonstrate severe spinal canal stenosis with a paucity of normal CSF signal within the subarachnoid space (arrowhead). An extradural T1 isointense and T2 hyperintense fluid collection (white arrows) compresses the thecal sac. The isointense T1 signal within the collection differs from the normal epidural fat and subcutaneous fat (black arrows).

After reviewing the MRI, the anesthesia team had a lengthy, detailed conversation with the patient regarding the anesthetic plan. It was explained to the patient that the MRI did suggest some technical difficulties in entering the epidural space, but that an epidural or low-dose combined spinal epidural anesthetic was reasonable to attempt.

She understood that there was a risk that we would need to convert to general anesthesia if the CSE failed to provide a good surgical level or if the epidural space could not be entered. A moderately increased chance of neurologic injury when compared to a parturient with normal lumbar spine anatomy and MRI (but still a very small chance) was acknowledged. At the time of the consult, her airway exam suggested no serious problem with direct laryngoscopy should that be necessary.

The patient presented to our labor floor in preterm labor at 36 weeks and 5 days gestational age. Equipment for difficult intubation was mobilized to the operating room and a second anesthesiologist attending was called for help. The patient was placed on the sitting position, skin was prepared and draped in the usual fashion, and the L4-L5 area was identified using the usual anatomic landmarks. Subcutaneous lidocaine 1% was infiltrated and a 17-gauge Tuohy needle was used to obtain access to the epidural space. The needle was advanced using a continuous pressure loss of resistance (LOR) to saline technique; at the 4.5 cm mark, a change of resistance was noted, somewhat less sudden and clear than the usual LOR felt upon epidural space entry. A 27-gauge Whitacre needle was inserted and cerebrospinal fluid (CSF) was noted to flow freely. 2.5 mg 0.25 % bupivacaine and 5 mcg fentanyl were injected into the intrathecal space, with aspiration of CSF before and after injection. Of note, the epidural was obtained upon first attempt using a midline approach, and the catheter was secured at the 9.5 cm mark at skin.

The Whitacre needle was then removed and the epidural catheter threaded. The patient experienced a transient paresthesia of her left lower extremity while the catheter was placed, resolving spontaneously. Despite the patient receiving a normal intrathecal "labor dose" there was no resolution of her contractions pain ~8 minutes after the spinal injection. A sensory level was assessed and it was found to be at T12. After negative aspiration of CSF and/or heme, lidocaine 1.5% with epinephrine 1:200,000 (3 ml) was then injected via the epidural catheter. After 5 min the motor and sensory level was assessed and the patient had a T12 level without significant motor blockade. At this point the patient stated that her contractions were feeling shorter and less painful. The epidural catheter was slowly bolused, 3ml of 2% lidocaine at a time at 4-5 min intervals, until a T4 level was obtained. The patient received a total of 15 ml of 2% lidocaine to obtain the surgical level. Surgery commenced and 9 minutes later the patient delivered a 3020 g healthy baby boy, Apgars 9/9. The patient received 2 mg of epidural morphine for post-operative pain control. The surgery lasted approximately one hour. The rest of the surgical and postoperative recovery of the patient was unremarkable.

Discussion

Achondroplasia is the most common non-lethal skeletal dysplasia [1]. This disorder is caused by a mutation in the gene encoding the type 3 receptor for fibroblast growth factor (FGFR3) [1,2] and it is inherited as an autosomal dominant condition, with 80-85% of the cases being de novo mutations [1-4]. The achondroplastic pelvic inlet is characterized by having a narrow anteroposterior diameter. Hence, cephalopelvic disproportion is common and further aggravated if the fetus inherited the condition, since macrocephaly is very common [2,4]. Consequently, cesarean section is the most common form of delivery for these patients [4].

General anesthesia may present some challenges. Mask ventilation may be difficult secondary to macroglossia, poor dental occlusion and flat nasal bridge; these classic characteristics of achondroplastic patients makes face mask fitting difficult [5]. Mather described a case in which direct laryngoscopy was impossible secondary to a patient's inability to extend his neck [6]. Limited neck extension might be explained by premature fusion of the bones at the base of the skull, this making direct laryngoscopy difficult if not impossible in some instances [5]. Monedero et al. reviewed their experience providing general anesthesia to 15 achondroplastic patients for 53 surgical procedures. Only one patient was classified as presenting a difficult intubation [5].

On the other hand, changes on the thoracolumbar anatomy and the stature of these patients makes neuraxial anesthesia challenging as well. Endochondral ossification occurs prematurely in this patients leading to shortened pedicles and a decreased interpedicular distance [7]. These changes result in a narrow spinal canal and areas of spinal stenosis [7,8]. The stenosis is further accentuated by age-related degenerative hypertrophy of the ligaments and facet joints of the spine and by the characteristic lumbar hyperlordosis especially when these patients are standing [2,8].

In our case we decided to use a CSE technique, placed at the L4-L5 interspace because MRI findings implied that there was moderate to marked central spinal stenosis but no gross anatomical abnormality at that interspace that would prevent the passage of our epidural catheter or cause neurologic injury to the patient (i.e. the epidural collection present at L1-L2, L2-L3). Epidural entry was achieved without any difficulty, but the loss of resistance (LOR) was questionable. It is possible that since this patient was suffering from diffuse spinal stenosis and the epidural space was somewhat less distensible with somewhat higher epidural space pressure than "usual," resulting in what was thought to be a questionable LOR.

The spinal component of the anesthetic was going to be used mainly to control labor pain while awaiting to obtain a surgical level, as we thought that the diffuse areas of spinal stenosis and the overall short stature would make the intrathecal distribution of local anesthetic unpredictable and hence a poor idea as a sole anesthetic. We did think it would be safe to administer a 2.5 mg dose of bupivacaine. Interestingly, despite giving this usual intrathecal dose for patients in labor, the patient did not obtain relief. We speculate that the lack of pain relief might have been secondary to the severe central stenosis reported at L1-L2, L2-L3 on MRI, limiting the spread of our local anesthetic and hence the inability to cover the T10-L1 pathway of pain associated with first stage of labor [9]. Since spinal stenosis is not uncommon in achondroplasts [7,8] and this phenomenon of spinal stenosis restricting intrathecal drug distribution may explain several case reports of unusual distribution of spinal anesthesia in achondroplastic patients.

Although neuraxial anesthesia has been used for cesarean delivery of a parturient with achondroplasia [3,4,10-15] the dose for spinal anesthesia or the volume needed for extending an epidural catheter for cesarean delivery is uncertain. Spinal anesthesia may be complicated by technical difficulties; the inability to obtain CSF if the spinal needle is directed close to an area of spinal stenosis [3] and by the fact that the distribution of the local anesthetic might be unpredictable [10], as in our case. The placement and management of an epidural catheter might be technically difficult, since spinal stenosis and engorgement of epidural veins during pregnancy might make the threading of the catheter difficult, puncture of an epidural vein more likely and the

block unreliable or patchy [3]. For these reasons it is important to improve the chances of successful block. We hoped that using the MRI to suggest where to attempt our procedure would improve our chances of success, and limit the risks to the patient. The MRI did provide some objective information such as which areas were affected the most by spinal stenosis, how straight is the spine, and confirmed the conus medullaris ended well above the low lumbar area. The images suggested relatively normal anatomy at L4/5 and L5/S1.

To the best of our knowledge there has been only one prior case in which the MRI was used on a patient with dyastrophic dwarfism to determine the best approach for an epidural technique [16,17]. We acknowledge our limitations in identifying the desired interspace by the use of anatomic landmark and in this case the use of an ultrasound technique as proposed by Wight et al. [10] would have been a more accurate method to correctly identify the targeted interspace. The ultrasound technique is still used only rarely in our practice.

We believe that an MRI performed during pregnancy might aid in evaluating the changes that pregnancy imposes on the achondroplastic lumbar spine, and may facilitate the identification of the optimal interspace for lumbar epidural or spinal placement. The combination of MRI and ultrasound for procedural direction could further improve success of neuraxial techniques for the achondroplastic parturient. Despite the fact that we did not use ultrasound, and hence, we cannot guarantee that we sited our epidural and spinal dose at the proposed L4-L5 level, we believe that the MRI gave us good anatomic information.

We suspect that some of the cases in which abnormal spread of local anesthetic occurred might be related to the lumbar interspace chosen by the anesthesiologist and the presence of spinal stenosis near that area. That is, if local anesthetic is injected at L2-L3 and the patient has spinal stenosis at L4 a somewhat higher level of anesthesia than expected could result. On the other hand, if the stenosis is above the areas where local anesthetic was injected (as we believe happened in our case) a lower than expected level of anesthesia might result.

References

1. Baujat G, Legeai-Mallet L, Finidori G, Cormier-Daire V, Le Merrer M (2008) Achondroplasia. *Best Pract Res Clin Rheumatol* 22: 3–18.
2. Chetty SP, Shaffer BL, Norton ME (2011) Management of Pregnancy in Women With Genetic Disorders, Part 1: Disorders of the Connective Tissue, Muscle, Vascular, and Skeletal Systems. *Obstet Gynecol Surv* 66: 699–709.
3. Morrow MJ, Black IH (1998) Epidural anaesthesia for caesarean section in an achondroplastic dwarf. *Br J Anaesth* 81: 619–621.
4. Carstoniu J, Yee I, Halpern S (1992) Epidural anaesthesia for caesarean section in an achondroplastic dwarf. *Can J Anaesth* 39: 708–711.
5. Monedero P, Garcia-Pedrajas F, Coca I, Fernandez-Liesa JI, Panadero A, et al. (1997) Is management of anesthesia in achondroplastic dwarfs really a challenge? *J Clin Anesth* 9: 208–212.
6. Mather JS (1966) Impossible direct laryngoscopy in achondroplasia. A case report. *Anaesthesia* 21: 244–248.
7. Jeong ST (2006) MRI study of the lumbar spine in achondroplasia: A morphometric analysis for the evaluation of stenosis of the canal. *J Bone Joint Surg Br* 88: 1192–1196.
8. Misra SN, Morgan HW (2003) Thoracolumbar spinal deformity in achondroplasia. *Neurosurg Focus* 14: e4.
9. Eltzschig HK, Lieberman ES, Camann WR (2003) Regional Anesthesia and Analgesia for Labor and Delivery. *N Engl J Med* 348: 319–332.
10. Wight JM, Male D, Combeer A (2013) Ultrasound-guided combined spinal-epidural anaesthesia for elective caesarean section in a patient with achondroplasia. *Int J Obstet Anesth* 22: 168–169.
11. Huang J, Babins N (2008) Anesthesia for cesarean delivery in an achondroplastic dwarf: a case report. *AANA J* 76: 435–436.
12. DeRenzo JS, Vallejo MC, Ramanathan S (2005) Failed regional anesthesia with reduced spinal bupivacaine dosage in a parturient with achondroplasia presenting for urgent cesarean section. *Int J Obstet Anesth* 14: 175–178.
13. Ravenscroft A, Govender T, Rout C (1998) Spinal anaesthesia for emergency Caesarean section in an achondroplastic dwarf. *Anaesthesia* 53: 1236–1237.
14. Beilin Y, Leibowitz AB (1993) Anesthesia for an achondroplastic dwarf presenting for urgent cesarean section. *Int J Obstet Anesth* 2: 96–97.
15. Cohen SE (1980) Anesthesia for Cesarean Section in Achondroplastic Dwarfs. *Anesthesiology* 52: 264–246.
16. Porter M, Mendonca C (2007) Anaesthesia for caesarean section in a patient with diastrophic dwarfism. *Int J Obstet Anesth* 16: 145–148.
17. Hirabayashi Y, Shimizu R, Fukuda H, Saitoh K, Furuse M (1995) Anatomical configuration of the spinal column in the supine position. II. Comparison of pregnant and non-pregnant women. *Br J Anaesth* 75: 6–8.