

A Case of Very Late Bare-Metal Coronary Stent Thrombosis Two Weeks after Aspirin Discontinuation, Histopathologic Thrombus Findings and Clinical Considerations

Gaetano Tanzilli*, Nicola Viceconte, Giovanni Truscilli*, Massimiliano Scappaticci and Enrico Mangieri

Department of Heart and Great Vessels "Attilio Reale", "Sapienza" University, Rome, Italy

*Corresponding authors: Gaetano Tanzilli, Department of Heart and Great Vessels "Attilio Reale", "Sapienza" University, Rome, Italy, Tel +39 06 49972660; Fax +39 06 49970178; E-mail: gaetano.tanzilli@uniroma1.it

Giovanni Truscilli, Department of Heart and Great Vessels "Attilio Reale", "Sapienza" University, Rome, Italy, Tel +39 06 49972660; Fax +39 06 49970178; E-mail: giovanni.truscilli@uniroma1.it

Received date: June 12, 2017; Accepted date: June 14, 2017; Published date: June 20, 2017

Copyright: © 2017 Tanzilli G, et al. This is an open-access article distributed under the terms of the Creative Commons Attribution License, which permits unrestricted use, distribution, and reproduction in any medium, provided the original author and source are credited.

Abstract

There have been consistent evidences that atherosclerotic changes occur inside bare metal stents (BMS) during an extended period after implantation. This report describes the histopathologic features of aspirated material harvested from a patient with definite very late stent thrombosis of a BMS implanted 18 years prior. The patient presented with a recurrent anterior acute myocardial infarction 14 day after aspirin discontinuation. We suggest that vulnerable neointimal tissue inside the stent struts of BMS may be one potential trigger of thrombosis when the protection of aspirin treatment is ceased.

Keywords: Bare-metal stent; Very late stent thrombosis; Intrastent neoatherosclerosis

Introduction

In-stent restenosis after bare-metal stent (BMS) implantation has long been considered a stable process characterized by early lumen narrowing related to intimal hyperplasia followed by neointimal remodeling and fibrotic stabilization [1]. On the contrary, later after BMS placement, the disease progression with formation of vulnerable yellow neointima is a common feature [2] suggesting that a longer time is needed to develop intrastent neoatherosclerosis. Accordingly, disruption of in-stent neoatherosclerotic lesions resulting in stent thrombosis has been reported to occur beyond three years after BMS implantation [3,4]. We present a case of a male patient with very late thrombosis (VLST) occurred 18 years after BMS implantation and 14 days after aspirin discontinuation that underwent primary percutaneous coronary intervention (pPCI) with thrombus aspiration for anterior ST elevation myocardial infarction (STEMI).

In November 2016, a 55 years old male patient was admitted to our university hospital for anterior STEMI. He had undergone pPCI for anterior STEMI with BMS implantation (NIR 3.5 × 18 mm, Boston Scientific, Galway, Ireland) at the proximal tract of left anterior descending artery (LAD) in March 1999 and had prescribed dual antiplatelet therapy consisting of daily dose of 100 mg aspirin (lifelong) and ticlopidine 250 mg two times day for 1 month, statins and beta-blockers. While on his medical treatment, he remained asymptomatic at the subsequent clinical follow-up without evidence of inducible ischemia at exercise stress tests. In April 2016, he started to feel resting chest pain of a variable duration. Based on the persistence of precordial symptoms accompanied by atypical ECG changes, the patient underwent coronary angiography that revealed on quantitative coronary analysis a diffuse intrastent diameter stenosis of 40% without any significant atherosclerotic involvement of left circumflex and right

coronary artery. Then he was discharged and advised to continue aspirin therapy and to take higher dosage of statin (atorvastatin, 80 mg daily). Eight months later, due to gastritis, he spontaneously decided to discontinue aspirin therapy and 14 days later he experienced abrupt chest pain for 90 minutes and shortness of breath. At the present admission, after receiving loading doses of 300 mg aspirin and 180 mg ticagrelor, the patient underwent an urgent coronary angiography which showed the thrombotic occlusion of the stent (Figure 1). After crossing the lesion with a floppy guidewire, the patient received a successful aspiration thrombectomy and intracoronary abciximab administration. After that, a new generation DES (Resolute Onyx™ stent 4 × 26 mm, Medtronic Inc, Minneapolis, USA) was deployed to cover the previously stented lesion. The in-hospital course was uneventful and after a week the patient was discharged. We recommended dual antiplatelet therapy with ticagrelor, for 12 months, and aspirin, indefinitely.

Studies after elective PCI have shown a small but significant increase of rates of late stent thrombosis (LST) with drug-eluting stent (DES) compared with BMS and it has mainly been related to different time course of re-endothelialization and vascular inflammation of the implanted devices [5,6]. Noteworthy, two aspects of the cellular response that the stents elicit need to be considered. BMSs show a decreasing inflammatory reaction with time, while DESs show a persistent, even increasing, inflammatory reaction due to the presence of the polymer as drug vehicle. In addition, different cellular and non-cellular (e.g. fibrin) structures contribute to the coverage of the stent struts. The long persistence of partially endothelialized, fibrin-rich, sites remain a potent thrombogenic stimulus and constitute the critical pathologic substrate underlying the phenomenon of LST. From a registry of autopsies [5], 23 cases of DES implantation for >30 days were compared with 25 matched autopsies of BMS. At 120 days there was a focal fibrin deposition and inflammatory cells response around DES. At this time point, BMS showed circumferential neointimal growth with complete coverage of the stent struts without evidence of

eosinophilic infiltrate and peristut fibrin deposition. Despite that, the presence of intimal regeneration does not necessarily mean in stent endothelial recovery of function. In fact, in stent atherosclerosis and restenosis processes are strongly associated with impaired endothelial function [7]. Furthermore, in iliac artery rabbit study, Joner et al. [8] found that, despite varying degrees of endothelial coverage, the staining of thrombomodulin, a physiologically relevant regulator of platelets and coagulation, was absent or only weakly expressed in 14- and 28-day DES, and was even reduced in BMS control stents compared with non-stented segments. This finding may be of clinical importance because the occurrence of the strut coverage with dysfunctional endothelium could play a primary role in determining a local thrombosis in absence of antiplatelet regimen.

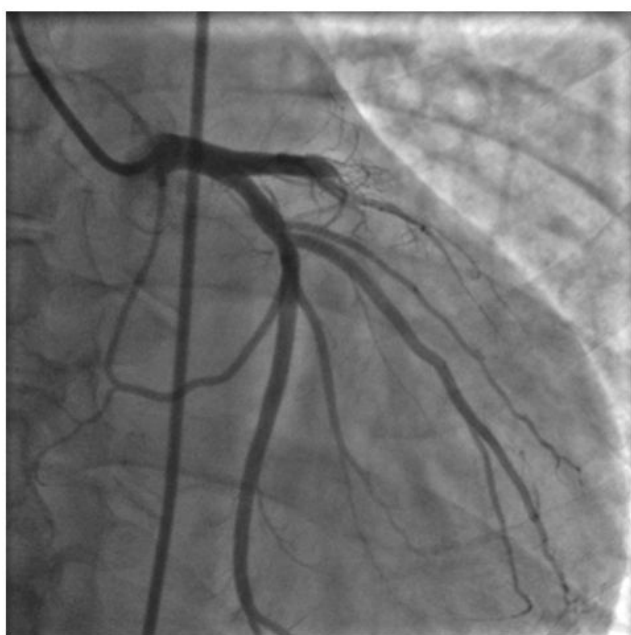

Figure 1: Coronary angiography at the present admission. Stent thrombosis occurred in the proximal tract of the left anterior descending artery 18 years after indexed procedure.

Our patient had a BMS implanted 12 years before and suffered from VLST shortly after voluntary discontinuation of ASA therapy that could have favoured thrombosis in area unable to maintain fully functional endothelialized in-stent luminal surface. Undoubtedly, aspirin still remain the most commonly prescribed drug for prevention of atherothrombotic events. This is due not only to its potent inhibition of thromboxane A2 pathways, which is crucial for platelet activation and aggregation, but also for pleiotropic effects [9]. Furthermore, the endothelium normally provides an efficient barrier against the excessive uptake of lipids. Based on this concept, intracoronary imaging studies have demonstrated that neointima within the BMS often transforms into lipid-laden tissue during an extended period of time [2,10]. The expression of lipid laden intima is closely related to in-stent restenosis, intimal disruption and thrombus formation, as typically observed at the culprit lesion of acute coronary syndrome [10,11]. Therefore, the expansion of neovascularization to neointima may play a key role in atherosclerotic progression and surrounding tissue instability. In the clinical setting, neointimal growth presenting with later in-stent restenosis is significantly associated with adverse

cardiac events [12], confirming the vulnerability of such complex plaques (Figure 2).

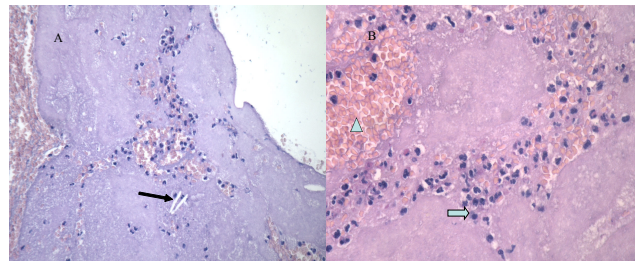


Figure 2: Histopathologic features of aspirated thrombus. A (20x), fresh thrombus displays the presence of soft plaque material (cholesterol needles, arrow). B (40x), coarse fibrin framework that entraps erythrocytes (arrow head) and neutrophils (arrow), sometimes in clusters (hematoxylin and eosin stain).

Conclusion

In our case, histopathological features of aspirated thrombus showed the presence of both soft plaque material consisting of cholesterol needles and thrombus characterized by a course of fibrin framework entrapping large amounts of erythrocytes and neutrophil infiltration (Figure 2). These results allow us to hypothesize that thrombus formation originating from atherosclerotic intimal disruption of stented segment in the late phase after BMS implantation along with dysfunctioning endothelium could represent the potential causes of very late thrombosis in our patient.

Finally, our case suggests that:

- 1) Neointima within the BMS can have a natural history comparable with the history of plaques occurring in the native untreated coronary arteries;
- 2) Very long term follow-up of patients treated with BMS along with lifelong antiplatelet therapy are required before the relative safety of these devices can be assessed definitely;
- 3) Every clinician should be vigilant of the possible occurrence of VLST in patients undergoing previously BMS implantation.

References

1. Komatsu R, Ueda M, Naruko T, Kojima A, Becker AE (1998) Neointimal tissue response at sites of coronary stenting in humans: macroscopic, histological, and immunohistochemical analyses. *Circulation* 98: 224-233.
2. Takano M, Yamamoto M, Inami S, Murakami D, Ohba T, et al. (2009) Appearance of lipid-laden intima and neovascularization after implantation of bare-metal stents extended late-phase observation by intracoronary optical coherence tomography. *J Am Coll Cardiol* 55: 26-32.
3. Celik T, Iyisoy A, Celik M, Isik E (2009) A case of very late stent thrombosis after bare metal coronary stent implantation: a neglected complication. *Int J Cardiol* 134: 111-113.
4. Ando H, Ishii H, Yoshikawa D, Uetani T, Amano T, et al. (2012) Disruption of atherosclerotic neointima as a cause of very late stent thrombosis after bare metal stent implantation. *Am J Cardiol* 109: 448-449.

5. Joner M, Finn AV, Farb A, Mont EK, Kolodgie FD, et al. (2006) Pathology of drug-eluting stents in humans: delayed healing and late thrombotic risk. *J Am Coll Cardiol* 48: 193-202.
6. Finn AV, Nakazawa G, Joner M, Kolodgie FD, Mont EK, et al. (2007) Vascular responses to drug eluting stents: importance of delayed healing. *Arterioscler Thromb Vasc Biol* 27: 1500-1510.
7. Thanyasiri P, Kathir K, Celermajer DS, Adams MR (2007) Endothelial dysfunction and restenosis following percutaneous coronary intervention. *Int J Cardiol* 119: 362-367.
8. Joner M, Nakazawa G, Finn AV, Quee SC, Coleman L, et al. (2008) Endothelial cell recovery between comparator polymer-based drug-eluting stents. *J Am Coll Cardiol* 52: 333-342.
9. Chakraborty K, Khan GA, Banerjee P, Ray U, Sinha AK (2003) Inhibition of human blood platelet aggregation and the stimulation of nitric oxide synthesis by aspirin. *Platelets* 14: 421-427.
10. Jang IK, Tearney GJ, Mac Neill, Takano M, Moselewski F, et al. (2005) In vivo characterization of coronary atherosclerotic plaque by use of optical coherence tomography. *Circulation* 111: 1551-1555.
11. Kimura T, Abe K, Shizuta S, Odashiro K, Yoshida Y, et al. (2002) Long-term clinical and angiographic follow-up after coronary stent placement in native coronary arteries. *Circulation* 105: 2986-2991.
12. Doyle B, Rihal CS, O'Sullivan CJ, Lennon RJ, Wiste HJ, et al. (2007) Outcomes of stent thrombosis and restenosis during extended follow-up of patients treated with bare-metal coronary stents. *Circulation* 116: 2391-2398.