

A Case of Primary Adrenal Tuberculosis - A Diagnostic Quandary

Nakaoka K^{1*}, Branch J², Yamaguchi M¹, Ozeki T¹, Hazi Y³, Tomino T³, Shimizu H¹ and Fujita Y³

¹Department of Nephrology, Chubu-Rosai Hospital, Nagoya, Japan

²Director of Medical Education, Shonan Kamakura General Hospital, Kamakura, Japan

³Department of Rheumatology, Chubu-Rosai Hospital, Nagoya, Japan

Abstract

Addison's disease refers to a chronic endocrine disorder characterized by primary adrenal insufficiency. The disease can occur due to various causes including autoimmune disease, infection, tumor and vascular disease. In the past, *Mycobacterium tuberculosis* (TB) infection was a major cause of adrenal failure and was associated primarily with early co-pulmonary infection. In the present era however, Addison's disease secondary to primary adrenal TB infection is somewhat rare. We describe a patient who was admitted to our hospital and was diagnosed with Addison's disease secondary to TB proven only following laparoscopic adrenalectomy.

Case Report

A 61-year-old woman was admitted our hospital complaining of weight loss and general fatigue. She had lost approximately 20 kg during the preceding six months and had undergone diagnostic esophagogastroduodenoscopy, which had revealed no abnormalities. She had also noticed an increasing degree of skin pigmentation over her entire body over the previous several months. There was no significant previous medical history, including no history of TB infection and no history of exposure to other individuals with this infection. On the admission day, the patient was confused, with a blood pressure of 83/56 mmHg, heart rate of 65 beats per minute and regular, temperature of 36.6°C and respiratory rate of 30 per minute respectively. The physical findings included a body mass index (BMI) of 16.6. Her skin, in addition to the oral and lip mucous membranes, were darkly pigmented. The cardiac, respiratory, abdomen and neurological examinations revealed no abnormalities.

Blood results revealed the following: red blood cell count $419 \times 10^4/\mu\text{L}$ (normal range 400 - $450 \times 10^4/\mu\text{L}$), hemoglobin 11.6 g/dL (normal range 12.0 - 16.0 g/dL), hematocrit 34.7% (normal range 37.0 - 42.0%), white blood cell count 7,200/ μL (normal range 4,000 - 9,000/ μL), platelet count $31.2 \times 10^4/\mu\text{L}$ (normal range 12.0 - $30.0 \times 10^4/\mu\text{L}$), serum sodium 126 mEq/L (normal range 138 - 146 mEq/L), serum potassium 4.4 mEq/L (normal range 3.6 - 4.9 mEq/L), serum chloride 93 mEq/L (normal range 99 - 109 mEq/L), serum aspartate aminotransferase 41 IU/L (normal range 13 - 33 mEq/L), serum alanine aminotransferase 19 IU/L (normal range 6 - 27 mEq/L), serum lactate dehydrogenase 148 IU/L (normal range 119 - 229 IU/L), plasma glucose 70 mg/dL (normal range 80 - 112 mg/dL), blood urea nitrogen 20.0 mg/dL (normal range 8 - 22.0 mg/dL), serum creatinine 0.53 mg/L (normal range 0.4 - 0.7 mg/dL), serum C-reactive protein 2.96 mg/dL (normal range <0.3 mg/dL) and serum osmolality 260 mOsm/kg (normal range 270 - 288 mOsm/kg). Serum adrenal cortex (AC) and 21-hydroxylase (21 OH) autoantibodies were both negative respectively. The results of serological tests for other autoimmune diseases were all negative and the antibody tests for human immunodeficiency virus (HIV) and cytomegalovirus (CMV) were also negative, respectively. The plasma ACTH was 568.5 pg/ml (normal range 7.2 - 66.3 pg/ml), the plasma cortisol 1.8 $\mu\text{g}/\text{dl}$ (normal range 4.0 - 22.3 $\mu\text{g}/\text{dl}$) and the serum aldosterone was 60.9 pg/ml (normal range 30 - 159 pg/ml). A rapid ACTH challenge test showed the following serum cortisol profile: Pre-challenge was 2.2 $\mu\text{g}/\text{dl}$ and 30 minutes post-challenge was 2.0 $\mu\text{g}/\text{dl}$ and the extended 60 minute challenge value was 2.3 $\mu\text{g}/\text{dl}$, respectively. Normal response shows an increase of more than 7 $\mu\text{g}/\text{dl}$ and a maximal level >20 $\mu\text{g}/\text{dl}$ at 30 minutes. The above results were diagnostic of primary adrenal insufficiency. A chest radiograph

and chest computed tomographic (CT) images obtained at admission revealed no abnormalities (Figure 1A & 1B). However, abdominal CT and magnetic resonance imaging (MRI) revealed bilateral enlargement of the adrenal glands without calcification (Figure 2A & 2B). Sputum polymerase chain reaction (PCR) test was negative for *M. tuberculosis*, but the initial and repeated Quanti FERON-TB Gold tests were both positive, leading to a suspected diagnosis of primary adrenal TB.

Clinical course of the patient

Intravenous hydrocortisone was administered at 300 mg/day for acute hypoadrenalism, along with 0.9% saline infusion for slow correction of the sodium levels. With this therapy alone, the patient's general symptoms greatly improved. Subsequently, antituberculous therapy was also commenced as follows: rifampicin 450 mg/day, isoniazid 300 mg/day, pyrazinamide 1500 mg/day, pyridoxal 30 mg/day and ethambutol 750 mg/day, respectively. With further clinical improvement, the hydrocortisone dose was reduced to 40 mg/day. However, since adrenal malignancy could not be excluded as the cause of the bilateral adrenal enlargement, laparoscopic adrenalectomy was performed for definitive diagnosis. Postoperative pathological

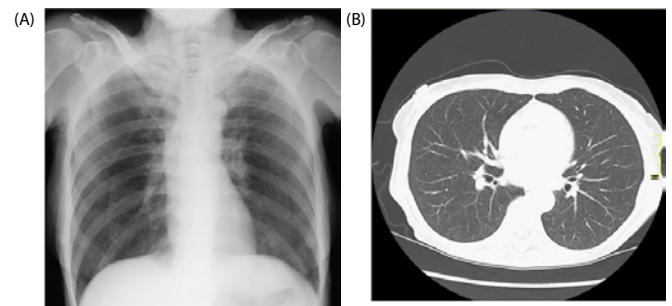


Figure 1: No normal findings on the chest X-ray or on chest CT (A and B).

*Corresponding author: Nakaoka K, Department of Nephrology, Chubu-Rosai Hospital, Nagoya, Japan, E-mail: ever0528@hotmail.com

Received December 20, 2011; Accepted January 30, 2012; Published February 01, 2012

Citation: Nakaoka K, Branch J, Yamaguchi M, Ozeki T, Hazi Y, et al. (2012) A Case of Primary Adrenal Tuberculosis - A Diagnostic Quandary. Endocrinol Metabol Syndr 1:103. doi:10.4172/2161-1017.1000103

Copyright: © 2012 Nakaoka K, et al. This is an open-access article distributed under the terms of the Creative Commons Attribution License, which permits unrestricted use, distribution, and reproduction in any medium, provided the original author and source are credited.

examination of the adrenal gland (Figure 3A & 3B) showed abnormal adrenal structure. Histologically, caseating necrosis and Langhans-type giant cells were identified (Figure 3C & 3D). The tissue polymerase chain reaction test was positive for *M. tuberculosis*, confirming primary adrenal TB.

Discussion

Adrenal insufficiency was first described by Thomas Addison in 1855. At that time, the major cause of adrenal insufficiency was Mycobacterium tuberculosis infection. Today, in developed countries, primary adrenal insufficiency is a relatively rare disease. For example, the prevalence of this disease per 100,000 populations is 0.45 in New Zealand, 11.7 in Italy, between 4-11 for Northern European countries and 5 in the United States [1]. In Japan, The Ministry of Health, Labour and Welfare estimated that 660 cases of primary Addison's disease are diagnosed per year. In Japan, the TB incidence has decreased dramatically as exemplified in the 2010 annual report of the tuberculosis survey of registrant information, which estimated the prevalence as 18.2 per 100,000 (down 0.8 from the previous year). Accordingly, the incidence and major etiology of Addison's disease has changed over time and is now commonly associated with autoimmunity. In Japan,

the etiology of this disease is as follows: 48.6% idiopathic (which also encompasses autoimmune causes), 37.8% tuberculosis and 13.6% other causes [2]. The proportion of idiopathic causes has been increasing over time. Betterle et al. [1] noted a high level of the autoimmune form of Addison's disease from European studies, which was most common and ranged from 44.5–94% of all cases, compared with Addison's disease due to tuberculosis or other causes, which ranged from 0–33.3% of all cases. Betterle et al. [1] study also noted that in Italy, the major cause of Addison's disease was autoimmunity, with tuberculosis being a somewhat rare cause (12%) [1]. Falorni [3] also noted that in Western countries, the rate of tuberculous adrenal insufficiency had also dramatically decreased. The study showed that 22 of 222 (12.5%) patients had Addison's disease caused by tuberculosis. Conversely, in developing countries, the rates of TB are still high. Primary adrenal insufficiency is caused by destruction of the adrenocortical tissue due to autoimmune disease, TB, cryptococcosis, fungal infection and metastatic tumors, etc. The resulting adrenal gland destruction may manifest clinically as generalized fatigue, weight loss, fever, dizziness which are nonspecific features of Addison disease. In the extreme situation, an "adrenal crisis" may occur as a result of infection, surgery or trauma, manifesting as low blood pressure, hyponatremia, hyperkalemia and/or hypoglycemia, many of the features present in this case. Nomura et al. [2] have reported that 92.9% of patients with adrenal TB have a previous history of lung and/or pleural TB. In these patients, the onset of Addison's disease occurs after a mean interval of 32 ± 15 years. The symptoms of primary Addison's disease manifest when more than 90% of the adrenal glands have been destroyed [4]. For this reason Addison's disease due to TB manifests relatively late in life, predominantly in persons aged 40 to 60 years [2]. It has been reported that the major CT finding of adrenal gland TB are the bilateral enlargement of the adrenal glands with calcification. When adrenal TB is active, enhanced CT shows increased enhancement of the peripheral rim of the gland, with the gland center showing a lower degree of attenuation. On the other hand, idiopathic Addison's disease is not characterized by either adrenal enlargement or calcification on CT. According to Guo et al. [5] adrenal gland enlargement on CT is frequently recognized within a year of the disease onset. However, the enlarged adrenals gradually shrink because of fibrosis and calcification [5]. Sun et al. [6] also identified adrenal gland enlargement on CT images within the first four years after the onset of adrenal gland TB. In our patient, bilateral adrenal enlargement without calcification was observed, suggesting the diagnosis of primary adrenal TB. Malignancy could not be completely excluded by CT or MRI, as bilateral enlargement is also a known imaging finding of this disease [7]. It has been reported that adrenal TB can be identified by positron emission tomography, but FDG-PET cannot distinguish between malignancy and TB [8]. We selected laparoscopic adrenalectomy, which was performed for definitive diagnosis. Typically, fine needle biopsy is often performed for the diagnosis of adrenal tumors more than 4 cm or greater in size, but in this case, it was avoided for several reasons. Firstly, the patient's adrenal anatomy was not amenable for accurate image-guided biopsy and secondly, the adrenal sizes were less than 4 cm, so the risk of internal organ damage and hemorrhage were deemed greater. Thirdly, CT scanning showed that the patient's adrenal glands were surrounded by probable necrotic tissue and hence, fine needle biopsy might have provided an inaccurate tissue diagnosis. This is supported by Nirag et al. [9] wherein inaccurate rates of percutaneous image-based fine needle aspiration of adrenal tumors ranged from 0% to 37%. Mazzaglia et al. [10] noted that biopsy is valuable for the diagnosis of metastatic tumors, but it is not suitable for the differentiation between benign or malignant tumors. Moreover, in our institution, endoscopic ultrasound guided fine-needle aspiration was not available, which is regarded to

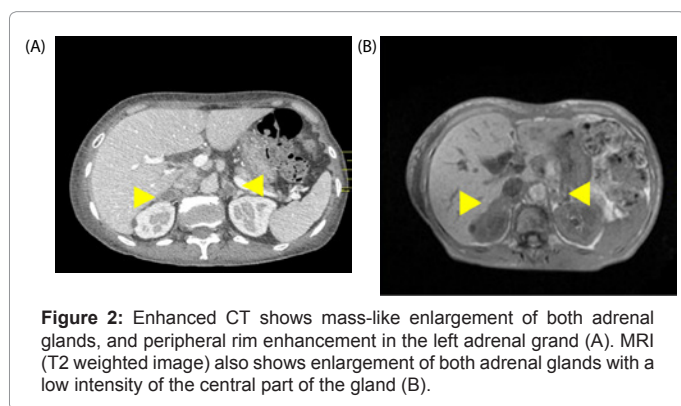


Figure 2: Enhanced CT shows mass-like enlargement of both adrenal glands, and peripheral rim enhancement in the left adrenal gland (A). MRI (T2 weighted image) also shows enlargement of both adrenal glands with a low intensity of the central part of the gland (B).

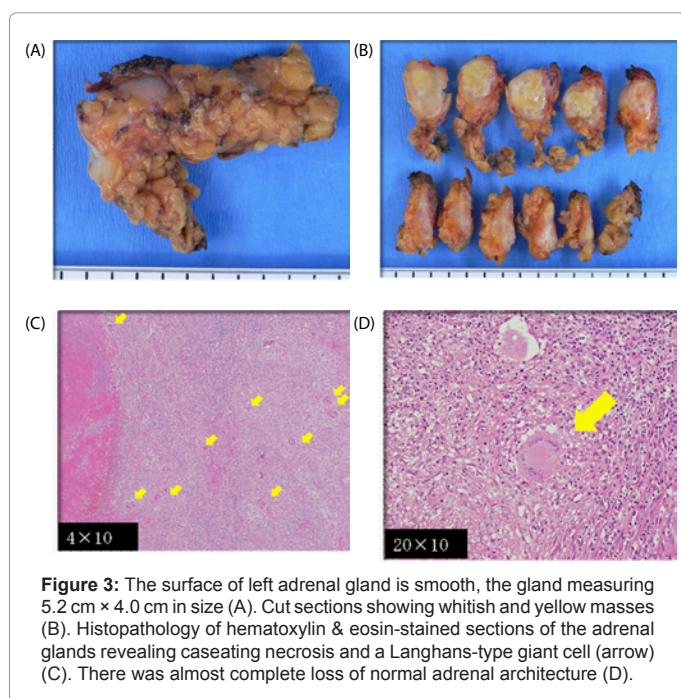


Figure 3: The surface of left adrenal gland is smooth, the gland measuring 5.2 cm x 4.0 cm in size (A). Cut sections showing whitish and yellow masses (B). Histopathology of hematoxylin & eosin-stained sections of the adrenal glands revealing caseating necrosis and a Langhans-type giant cell (arrow) (C). There was almost complete loss of normal adrenal architecture (D).

have a better sensitivity and with fewer adverse events compared to the percutaneous route [9]. Hence, in this case, bilateral adrenalectomy was the most appropriate intervention to establish a definitive diagnosis. AC and 21-OH autoantibodies were both negative in this case but this cannot exclude the diagnosis of autoimmune Addison's disease entirely. Conversely, the presence of such autoantibodies does not necessarily diagnose autoimmune Addison's disease either, as such autoantibodies, when found in isolation rather than together, can be positive in tuberculosis. This was exemplified by Nigam et al. [11] who revealed 18 tuberculosis and 1 fungal infection of 38 patients with granulomatous adrenal glands but who also had positive adrenal autoantibodies. Falorni et al. [3] noted that the detection of AC or 21-OH autoantibodies in patients' with adrenal insufficiency did not lead to a definitive diagnosis of autoimmune Addison's disease, in view that adrenal autoantibodies are found sporadically in patients with post-tuberculosis adrenalitis. Indeed, the study showed 3 of 18 autoimmune Addison's disease patients' who had isolated 21-OH autoantibody also had an episode of tuberculosis and the same for 8 of 27 autoimmune Addison's disease patients' who had isolated AC autoantibody [3]. Nomura also found 7-13% of tuberculous Addison's disease patients' were AC autoantibody positive [3].

Conclusion

Adrenal TB is a rare but important disease entity that must be identified early and treated promptly and aggressively. Despite indirect evidence suggesting TB as the cause of the adrenal gland abnormalities in our patient, malignancy could not be excluded without first obtaining tissue for pathological examination. In the authors' opinion, it is considered that TB is often under-diagnosed in Japan as there is a misguided belief that TB drugs are completely effective and that it is a disease of the past rather than the present. However, in Japan, there is a frequent overuse of fluoroquinolone antibiotics by physicians [12], which can partially treat TB and therefore delay the diagnosis of the disease [13] with the potential to induce drug resistance to this second-line drug and particularly after multiple doses [14]. Therefore, if the diagnosis of Addison's disease is uncertain and malignancy is suspected, prior to invasive investigations, TB testing should be strongly considered in areas with a high rate of disease. Lastly, despite fine needle biopsy being of low risk to the patient, it can nevertheless miss the diagnosis in a substantial number of patients, which may therefore still require that adrenalectomy be performed.

This case prompts us to revisit the past and consider TB as an uncommon, albeit potentially devastating cause of adrenal failure in modern society.

References

1. Betterle C, Dal Pra C, Mantero F, Zanchetta R (2002) Autoimmune Adrenal Insufficiency and Autoimmune Polyendocrine Syndromes: Autoantibodies, Autoantigens, and Their Applicability in Diagnosis and Disease Prediction. *Endocr Rev* 23: 327-364.
2. Nomura K, Demura H, Saruta T (1994) Addison's disease in Japan: characteristics and changes revealed in a nationwide survey. *Intern Med* 33: 602-606.
3. Falorni A, Laureti S, De Bellis A, Zanchetta R, Tiberti C, et al. (2004) Italian Addison Network Study: Update of Diagnostic Criteria for the Etiological Classification of Primary Adrenal Insufficiency. *J Clin Endocrinol Metab* 89: 1598-1604.
4. Gordon HW, Robert GD (2008) Disorders of the adrenal cortex: Harrison's Principles of Internal Medicine (17ed) The McGraw-Hill companies New York.
5. Guo YK, Yang ZG, Li Y, Ma ES, Deng YP, et al. (2006) Addison's disease due to adrenal tuberculosis: Contrast-enhanced CT features and clinical duration correlation. *Eur J Radiol* 62: 126-131.
6. Sun ZH, Nomura K, Toraya S, Ujihara M, Horiba N, et al. (1992) Clinical significance of adrenal computed tomography in Addison's disease. *Endocrinol Jpn* 39: 563-569.
7. Hauser H, Battikha JG, Wettstein P (1981) Pathology of the adrenal glands. Common and uncommon findings in computed tomography. *Eur J Radiol* 1: 215-226.
8. Long Wang, Yanq J (2008) Tuberculous Addison's Disease Mimics Malignancy in FDG-PET Images. *Inter Med* 47: 1755-1756.
9. Jhala NC, Jhala D, Eloubeidi MA, Chhieng DC, Crowe DR, et al. (2004) Endoscopic ultrasound-guided fine-needle aspiration biopsy of the adrenal glands: analysis of 24 patients. *Cancer* 102: 308-314.
10. Mazzaglia PJ, Monchik JM (2009) Limited value of adrenal biopsy in the evaluation of adrenal neoplasm: a decade of experience. *Arch Surg* 144: 465-470.
11. Nigam R, Bhatia E, Miao D, Yu L, Brozzetti A, et al. (2003) Prevalence of adrenal antibodies in Addison's disease among north Indian Caucasians. *Clin Endocrinol* 59: 593-598.
12. Higashi T, Fukuhara S (2009) Antibiotic prescriptions for upper respiratory tract infection in Japan. *Intern Med* 48: 1369-1375.
13. Ang D, Hsu AA, Tan BH (2006) Fluoroquinolones may delay the diagnosis of tuberculosis. *Singapore Med J* 47: 747-751.
14. Ginsburg AS, Hooper N, Parrish N, Dooley KE, Dorman SE, et al. (2003) Fluoroquinolone resistance in patients with newly diagnosed tuberculosis. *Clin Infect Dis* 37: 1448-1452.
15. Long R, Chong H, Hoepfner V, Shanmuganathan H, Kowalewska-Grochowska K, et al (2009) Empirical treatment of community-acquired pneumonia and the development of fluoroquinolone-resistant tuberculosis. *Clin Infect Dis* 48: 1354-1360.