

## A Case of Orbital Fibrous Histiocytoma: Case Report

Hossameldeen Elsayed Elbarbary\* and Hesham Farouk Idriss

Department of Ophthalmology, Alexandria University Faculty of Medicine, Egypt

\*Corresponding author: Hossameldeen Elsayed Elbarbary, Department of Ophthalmology, Alexandria University Faculty of Medicine, Egypt, E-mail: hossameldin.elbarbary@alexmed.edu.eg; elbarbary\_h@yahoo.com

Received date: March 26, 2018; Accepted date: April 04, 2018; Published date: April 10, 2018

Copyright: © 2018 Elbarbary HE, et al. This is an open-access article distributed under the terms of the Creative Commons Attribution License, which permits unrestricted use, distribution, and reproduction in any medium, provided the original author and source are credited.

### Abstract

This is case report of a benign fibrous histiocytoma in the orbit and completely excised by a medial orbitotomy through skin (Lynch) incision with video demonstration of its excision.

**Keywords:** Fibrous histiocytoma; Orbit; Computed tomography

### Introduction

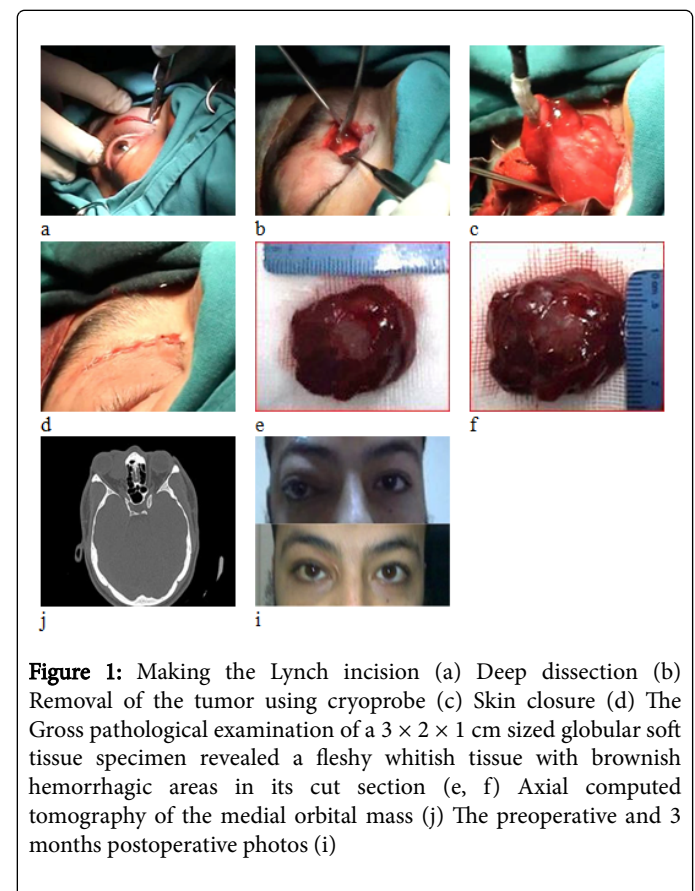
Fibrous histiocytoma is a primary mesenchymal soft tissue tumor. A case of benign fibrous histiocytoma of the orbit was reported in a 26 year old man. He sought treatment for painless, progressive swelling of the right eyelid and mild proptosis. Computed tomography showed an extraconal mass of the right orbit which was medially located with consequent lateral exophthalmos. The tumor was completely excised by medial orbitotomy through skin (Lynch) incision. Light microscopic examination showed that the tumor cells were arranged in a characteristic storiform pattern. Based on these features, a diagnosis of benign fibrous histiocytoma was made.

Fibrous histiocytoma is one of the mesenchymal soft tissue tumors. Tumors that are believed to arise from mesenchymal tissues occur in multiple sites with variable biologic behavior. The tumors in this group arise from primitive mesenchymal stem cells capable of developing into a variety of cell types. Mesenchymal tumors account for 2% of orbital lesions and 9% of neoplasia; in children they constitute 5% of all disease and 19.4% of childhood neoplasia [1,2]. Fibrous histiocytomas histologically and clinically can vary from a slowly developing benign to locally aggressive malignant lesion. Four subtypes have been described in order of frequency: storiformpleomorphic, myxoid (myxoidfibrosarcoma), giant cell (malignant giant cell tumor of soft parts), and inflammatory (xanthosarcoma, malignant xanthogranuloma) [3].

### Case Report

A 26 year old man sought medical advice for painless, progressive swelling of the right upper eyelid and abnormal eye globe position over the duration of six months. Complete ophthalmologic examination was done and it was completely free. On Hertel exophthalmometry, the proptosis of the right eye was 5 mm with 3 mm inferior vertical displacement and 4 mm lateral horizontal displacement of the right globe. Computed tomography scan showed a 2.7 × 2 × 2.7 cm sized well-demarcated right orbital extraconal medially located mass with lateral exophthalmos. Indentation and lateral displacement of the medial rectus were seen. The related portion of the lamina papyracia was compressed and bended inward due to the mass effect without evidence of any bone erosion or destruction. The patient underwent right medial orbitotomy through Lynch skin incision. The Gross

pathological examination of a 3 × 2 × 1 cm sized globular soft tissue specimen revealed a fleshy whitish tissue with brownish hemorrhagic areas in its cut section. The microscopic examination revealed a well circumscribed tumor composed of bland looking fibroblast like cells arranged in the characteristic storiform pattern and admixed with foamy histiocytes. With these data, it was finally diagnosed as a benign fibrous histiocytoma. After the surgery, proptosis was completely improved with normal visual acuity and normal function of all extraocular muscles. No signs of recurrence were noticed over duration of 5 year follow up Figure 1.



**Figure 1:** Making the Lynch incision (a) Deep dissection (b) Removal of the tumor using cryoprobe (c) Skin closure (d) The Gross pathological examination of a 3 × 2 × 1 cm sized globular soft tissue specimen revealed a fleshy whitish tissue with brownish hemorrhagic areas in its cut section (e, f) Axial computed tomography of the medial orbital mass (j) The preoperative and 3 months postoperative photos (i)

---

## Conclusion

Fibrous histiocytoma is the most common primary orbital mesenchymal neoplasm in adults. The median age at presentation is 43 years, and the superior nasal orbit is the most common site. Fibrous histiocytoma is usually slow growing and characteristically very firm, displacing normal structures. The most common clinical signs are proptosis and mass effect with decreased vision; less common signs are diplopia, pain, lid edema, tearing, ptosis, and ophthalmoplegia. Both fibroblastic and histiocytic cells in a storiform (mat-like) pattern are found in these locally aggressive tumors. Although most are benign, intermediate and malignant varieties exist, but fewer than 10% have metastatic potential. It is often difficult to distinguish this tumor clinically or microscopically from hemangiopericytoma. Management is surgical excision supplemented by adjuvant post-operative radiation therapy or possibly chemotherapy. Careful follow up is necessary for signs of recurrence [4].

## Conflict of Interest

The authors have no financial or conflicts of interest to disclose.

## Acknowledgement

Presented as a poster at 35th ESOPRS Annual Meeting organized by the European Society of Ophthalmic Plastic and Reconstructive Surgery held on September 15-17, 2016, in Athens, Greece.

## References

1. Rootman J, Weis E (2009) Mesenchymal tumors: Surgical Atlas of Orbital Diseases. Japye Brothers pp: 170-179.
2. Rootman J, Neoplasia (2003) Diseases of the Orbit: A Multidisciplinary Approach, second edition. Philadelphia, PA: Lippincott Williams & Wilkins pp: 262-278.
3. Weiss SW, Folpe AL, Goldbulm JR (2014) Enzinger and Weiss's Soft Tissue Tumors. Philadelphia: Saunders.
4. Katz BJ, Nerad JA (1998) Ophthalmic manifestations of fibrous dysplasia – a disease of children and adults. Ophthalmology 105: 2207-2215.