

A Case of Glandular Cheilitis Presenting with Recurrent Swelling of the Lips during the Course of Rheumatoid Arthritis

Dinckal C^{1*}, Karabulut G², Kumbaracı BS^{1,3}, Mete Gokmen N⁴

¹Department of Internal Medicine, Ege University School of Medicine, Izmir, Turkey; ²Department of Internal Medicine, Ege University School of Medicine, Division of Rheumatology, Izmir, Turkey; ³Department of Pathology, Ege University School of Medicine, Izmir, Turkey; ⁴Department of Internal Medicine, Ege University School of Medicine, Division of Immunology, Izmir, Turkey

ABSTRACT

Cheilitis glandularis (CG) is a rare disorder of unknown etiology characterized by inflammation of the minor salivary glands of the lower lip. Clinically, three variants have been described: cheilitis glandularis simplex, cheilitis glandularis suppurativa, and cheilitis glandularis apostematosa. Most cases are diagnosed as the simple form of glandular cheilitis, which is characterized by enlarged excretory ducts, induration, and enlargement of the salivary glands as well as production of a rather mucopurulent saliva. The diagnosis of CG is done with clinical and pathologic correlation. A swollen lip is common in clinical practice, but the differential diagnosis and management of the condition may be challenging. Lip swelling may be related to a local or systemic condition. We hereby report an unusual case of CG of lips in a female patient visited the department of Internal Medicine, Ege University. She was being followed up with the diagnosis of rheumatoid arthritis and presented with recurrent swelling of the lips repeatedly. She had previously been followed up for angioedema because of recurrent swelling of the lips. The patient's laboratory tests were normal and lip biopsy was consistent with glandular cheilitis. The aim of this article is to discuss the differential diagnosis of glandular cheilitis.

Keywords: Rheumatoid arthritis; Inflammation; Recurrent; Cheilitis glandularis; Swelling of the lips

INTRODUCTION

Cheilitis glandularis (CG) is a rare-chronic inflammatory condition of the minor salivary glands. It is mainly characterized by swelling of the lip with hyperplasia of the salivary glands; secretion of a clear, thick mucus; and variable inflammation. The etiology and pathogenesis of CG are unknown [1-4]. Cheilitis glandularis is more common in adult males, although cases have been described in women and children. It is associated with a relatively high incidence of squamous cell carcinoma of the lip. Treatment may include surgical excision by vermilionectomy, but treatment varies for each individual [5]. The aim of this report is to make the differential diagnosis of glandular cheilitis in patients presenting with recurrent swelling of the lips.

CASE REPORT

52-year-old female patient, presented with a 10 year history of lower lip swelling with the diagnosis of angioedema in many centers had been examined before (Figure 1). Anamnestically, there was no evidence for angioedema or urticaria. There were no signs of bacterial superinfection or suppurative exudate. On clinical examination, the lower lip appeared swollen with presence of crustations. Dry eye test was normal. Also, dental patch and nickel test were negative. Cheilitis granulomatosa, lupus erythematosus, actinic cheilitis and sarcoidosis, amongst other dermatoses had been ruled out by lip biopsy and autoimmune serology. Routine blood investigations performed were in normal limits except for antinuclear antibody with granular pattern a titer of 1:80 and C-Reactive Protein level of 1.49 mg/dl. Quantitative assessment of other parameters

*Correspondence to: Cigdem Dinckal, Department of Internal Medicine, Ege University School of Medicine, Izmir, Turkey, Tel: +902323111010; E-mail: drcigdemdinckal@gmail.com

Received: June 25, 2019; Accepted: July 24, 2019; Published: July 30, 2019

Citation: Dinckal C, Karabulut G, Kumbaracı BS, Mete Gokmen N (2019) A Case of Glandular Cheilitis Presenting with Recurrent Swelling of the Lips during the Course Of Rheumatoid Arthritis. *Rheumatology (Sunnyvale)*. 9:250. DOI: 10.35248/2161-1149.19.9.250

Copyright: © 2019 Dinckal C, et al. This is an open-access article distributed under the terms of the Creative Commons Attribution License, which permits unrestricted use, distribution, and reproduction in any medium, provided the original author and source are credited.

revealed normal values (ds-DNA-, U1 RNP-, Sm-, SSA-, SSB-, Scl-70-, centromere- and Jo-1-antibodies).

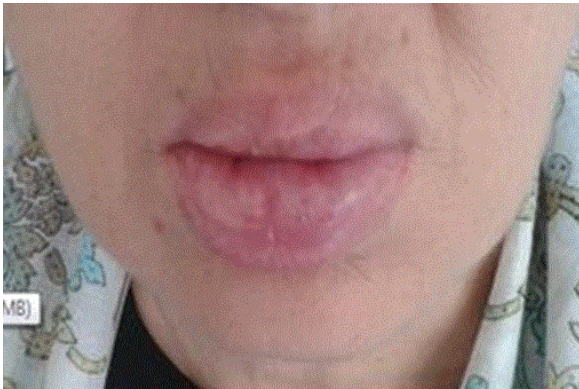


Figure 1: Extra oral photograph of lips with edema.

The patient's postmedical history was significant for rheumatoid arthritis. Medications included dexamethasone (5 mg), hydroxychloroquine sulfate (2 per day), sulfasalazine (2 per day) and methotrexate (7,5 mg once a week). The salzopyrin was discontinued because the angioedema attacks were triggered by salzopyrin, but was restarted when the swelling was repeated on the follow-up lips. Laboratory examination of the patient with rheumatoid arthritis for 2 years revealed Rheumatoid factor 11 (<14 IU/ml) and anti CCP 295 (<1 RU/mL). In view of the patient in terms of rheumatoid arthritis; both radiocarpal, intercarpal, and carpometacarpal joints narrowed and sclerotic densities increased on bone surfaces facing the joint surface. It is compatible with the joint involvement of the symptomatic disease with the diagnosis of rheumatoid arthritis. Also in medical history; the patient had no known drug allergies. She denied alcohol and cigarettes use.

Biopsy was performed to confirm the diagnosis: The presence of the lymphocyte populations in the minor salivary glands of sjogren's syndrome is consistent with minor salivary gland involvement when considered in the differential diagnosis of CG mind being seen marked expansion with cystic duct dilatation and mucus accumulation of glandular cheilitis it. Then, histologically, ectasia of glandular ducts and dermal lymphohistiocytic infiltrate, and enlarged vessels (Figures 2 and 3).

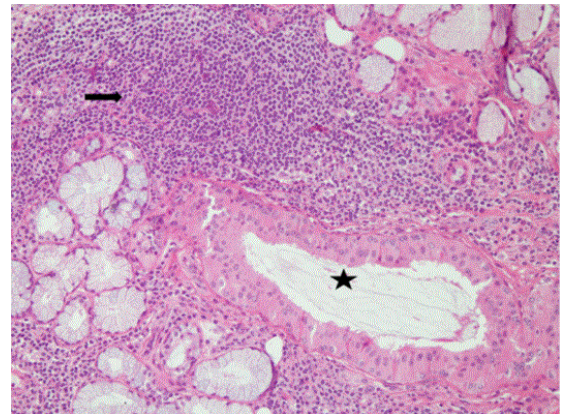


Figure 2: Histologically, ectasia of glandular ducts and dermal lymphohistiocytic infiltrate (hematoxylin and eosin stain; original magnification x100).

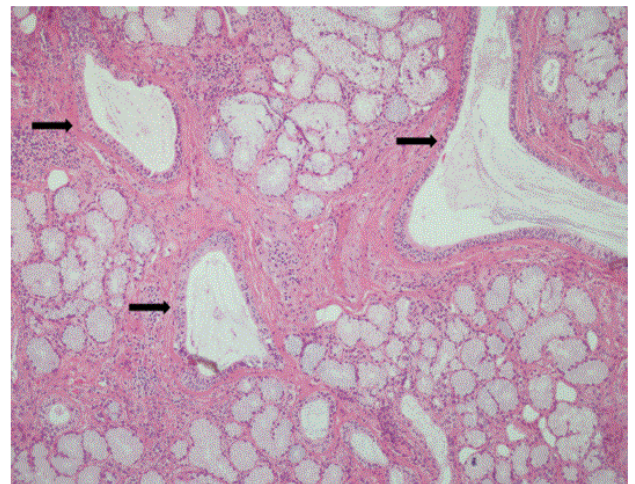


Figure 3: Histologically, enlarged vessels (hematoxylin and eosin stain; original magnification x100).

DISCUSSION

If cheilitis glandularis (CG) is a clinically descriptive diagnosis that refers to an uncommon, poorly understood inflammatory disorder of the lower lip, the swollen lips are common in clinical practice. The differential diagnosis can be simplified by grouping findings into broad categories: trauma, inflammation, infection, metabolic diseases, neoplasm and idiopathic conditions. Swelling of the lips, which can sometimes be a sign of a systemic disease [6].

Although rheumatoid arthritis is well known to be associated with primary Sjögren syndrome and with various autoimmune diseases, it is less clear whether a similar association also exists for CG. Even so, in cases in which dryness is attributable to documented Sjögren syndrome, referral to a rheumatologist and a dentist are recommended for further systemic workup, ongoing follow up, and preventive care [7]. Despite our patient it could not be supported by clinical findings expected in the foreground Sjögren syndrome connected to rheumatism.

Angioedema is a common reason for attendance at the emergency department and for referral to immunology/allergy clinics. Life-threatening angioedema can be easily understood

with a good history and physical examination. Angioedema may be excluded on the lips when the swollenness does not conform to the typical episode of angioedema and the external appearance of the lips [8]. It is not easy for physicians to exclude angioedema in our patient who has complaints that last for more than 10 years.

Primary Sjögren's syndrome (SS) is classically considered a disease of salivary and lacrimal glands as a result of focal lymphocytic infiltration. Parenchymal organ involvement can also manifest as, among others, interstitial nephritis, autoimmune cholangitis, and in rare cases autoimmune pancreatitis which have also been appreciated as part of the newly described IgG4-related disease (IgG4-RD) (3). According to some authors, diagnosis further affords the number of IgG4-producing cells exceeding 40% of total IgG-expressing plasma cells, and the presence of tissue fibrosis or even sclerosis. Given the poor knowledge about CG pathogenesis, better immunological markers are needed, analogous to those successfully used in Sjögren's syndrome [9].

NERDS is an eosinophilic disorder recently described by Butterfield and characterized by an association of nodules, eosinophilia, rheumatism, dermatitis and swelling. The cardinal features included cutaneous manifestations with prominent xerosis, recurrent urticarial eruption with angioedema associated with tissue and peripheral blood eosinophilia [10]. We consider in the differential diagnosis in our patient because of rheumatism and edema of the lips, but we exclude NERDS does not support other findings.

Küttner tumour is benign, chronic, sclerosing sialadenitis that usually occurs in the submandibular gland and is regarded as a salivary gland neoplasm because of its clinical features [11]. Sometimes this tumor is similar to glandular cheilitis cases. Even Küttner's tumour is currently associated with IgG4 related disease [12].

Melkersson-Rosenthal syndrome is another disease that can be confused with glandular cheilitis. And many other similar clinical conditions can be discussed in the differential diagnosis. However, we discussed the most important topics we discussed in the differential diagnosis of our patient [13].

Finally, CG is needs to be attended to as it will continue to worsen over time and even increase the chances of squamous cell carcinoma (cancer) of the lip in some cases [14].

CONCLUSION

In conclusion, CG is a rare disorder of unknown etiology characterized by inflammation of the minor salivary glands of the lower lip. The diagnosis of CG is done with clinical and pathologic correlation. A swollen lip is common in clinical practice, but the differential diagnosis and management of the condition may be challenging. Lip swelling may be related to a local or systemic condition. We hereby report an unusual case of

CG of lips in a female patient and emphasize, the differential diagnosis of swelling on the lips for the diagnosis of CG angioedema should be done especially.

CONFLICT OF INTEREST

No conflict of interest was declared by the authors.

FINANCIAL DISCLOSURE

The authors declared that this study has received no financial support.

REFERENCES

1. Andrade ESS, Sobral APV, Laureano Filho JR, Santos MESM, Camargo IB. Cheilitis glandularis and actinic cheilitis: differential diagnoses-report of three unusual cases. *Dermatol Online J.* 2009;15(1):5.
2. Reichart P, Scheifele C, Philipsen H. Cheilitis glandularis. Mouth, jaw, and facial surgery. *J Oral Maxillofac Surg.* 2002;6(4):266-270.
3. Samimi M. [Cheilitis: Diagnosis and treatment]. *Presse Med.* 2016;45(2):240-250.
4. Stanton DC, Chou JC, Sollecito TP, Stoopler ET, Pringle G, Carrasco LR, et al. Recurrent lower lip swelling in a 62-year-old African American female. *Cheilitis glandularis. J Oral Maxillofac Surg.* 2008;66(12):2585-2591.
5. Stoopler ET, Carrasco L, Stanton DC, Pringle G, Sollecito TP. Cheilitis glandularis: An unusual histopathologic presentation. *Oral Surg Oral Med Oral Pathol Oral Radiol Endod.* 2003;95(3):312-317.
6. Gu Y, Williams M, Poh CF. How do I evaluate a patient with a swollen lip? *J Can Dent Assoc.* 2010;76:a92.
7. Mavragani CP, Moutsopoulos HM. The geoepidemiology of Sjögren's syndrome. *Autoimmun Rev.* 2010;9(5):A305-310.
8. Grigoriadou S, Longhurst HJ. Clinical immunology review series: An approach to the patient with angio-oedema. *Clin Exp Immunol.* 2009;155(3):367-377.
9. Umehara H, Okazaki K, Masaki Y, Kawano M, Yamamoto M, Saeki T, et al. Comprehensive diagnostic criteria for IgG4-related disease (IgG4-RD), 2011. *Mod Rheumatol.* 2012;22(1):21-30.
10. Zenarola P, Melillo L, Bisceglia M, Carotenuto M, Lomuto M. NERDS syndrome: an additional case report. *Dermatol.* 1995;191(2):133-138.
11. Paul R, Shekar K, Singh M. Küttner tumour: an unusual cause of enlargement of a minor salivary gland in the lip. *Br J Oral Maxillofac Surg.* 2010;48(2):152-153.
12. Friedrich RE, Löning T. Cheilitis glandularis: Case report with respect to immunohistochemical findings. *GMS Interdiscip Plast Reconstr Surg. DGPW* 2016;5:Doc04.
13. Stanton DC, Chou JC, Sollecito TP, Stoopler ET, Pringle G, Carrasco LR, et al. Recurrent lower lip swelling in a 62-Year-old African American female. *J Oral Maxillofac Surg.* 2008;66(12):2585-2591.
14. Carrington PR, Horn TD. Cheilitis glandularis: a clinical marker for both malignancy and/or severe inflammatory disease of the oral cavity. *J Am Acad Dermatol.* 2006;54(2):336-337.