

# A Case of Eosinophilic Granulomatosis with Polyangiitis with Severe Peripheral Neuropathy Refractory to Standard Treatment Successfully Treated by Mepolizumab

Seika Terashima, Makoto Yamaguchi, Takayuki Katsuno, Hirokazu Sugiyama, Shiho Iwagaitsu, Hironobu Nobata, Hiroshi Kinashi, Shogo Banno, Yasuhiko Ito\*

Department of Nephrology and Rheumatology, Aichi Medical University, Nagakute, Japan

## ABSTRACT

The clinical benefits of administering mepolizumab to patients with Eosinophilic Granulomatosis with Polyangiitis (EGPA) to prolong the remission period have recently been reported. However, the timing of initiating mepolizumab and the clinical characteristics that are best indicators for mepolizumab treatment have not yet been identified. Herein, we report the case of a 57-year-old male Japanese patient with Anti-Neutrophil Cytoplasmic Antibody (ANCA)-negative EGPA who manifested severe peripheral neuropathy refractory to standard therapy.

The patient was administered with a high-dose steroid, intravenous cyclophosphamide, intravenous immune globulin, and finally mepolizumab, which resulted in the clinical improvement of nervous symptoms without any adverse effects. Clinicopathologically, ANCA-negative peripheral neuropathy might be caused by eosinophil-associated vascular occlusion, leading to ischaemia, toxic protein release, and, ultimately, tissue damage. Therefore, this case indicates that using mepolizumab for patients with early-phase EGPA might be clinically beneficial, especially in cases of ANCA-negative EGPA with peripheral neuropathy.

**Keywords:** Eosinophilic granulomatosis with polyangiitis; Mepolizumab; Peripheral neuropathy; Anti-neutrophil cytoplasmic antibody associated vasculitis

## INTRODUCTION

Eosinophilic Granulomatosis with Polyangiitis (EGPA) is a type of Anti-Neutrophil Cytoplasmic Antibody (ANCA) Associated Vasculitis (AAV), characterized by small to medium-sized vessel vasculitis, and is typically associated with eosinophilic granulomatous inflammation [1-3]. EGPA is the rarest among AAV, and studies have reported that the annual incidence and prevalence of EGPA were 0.9-2.4 per million and 10.7-17.8 per million, respectively [4,5].

EGPA is generally responsive to glucocorticoids, however, the relapses are common [6-8], and some refractory cases have been reported [9,10]. The clinical benefits of administering mepolizumab to patients with EGPA for prolonging the remission period of the disease have been reported [11-14]. However, it has not yet been elucidated when mepolizumab should be started or what clinical characteristics are the best indicators for mepolizumab treatment.

Herein, we present a case of ANCA-negative EGPA with severe peripheral neuropathy refractory to standard therapy. The patient was administered with a high-dose steroid, intravenous cyclophosphamide, intravenous immune globulin, and finally mepolizumab, which resulted in marked clinical improvement of nervous symptom without any adverse effects.

## CASE PRESENTATION

A 57-year-old man presented to our hospital with a 1 week history of fever, deteriorating bilateral leg pain and numbness, and difficulty in walking due to progressive weakness in the bilateral lower extremities. He was subsequently admitted. He had been diagnosed with bronchial asthma and eosinophilic sinusitis 2 years prior to this case, at which time he was treated with anti-leukotrienes, inhaled steroids, and theophylline. His body temperature was 38.4°C. Neurological examination showed touch-temperature-pain hypoesthesia in a stocking and glove distribution.

**Correspondence to:** Dr. Yasuhiko Ito, Department of Nephrology and Rheumatology, Aichi Medical University, 1-1 Karimata, Yazako, Nagakute 480-1195, Japan, Tel: +81-0561-62-3311, Fax: +81-0561-63-1583; E-mail: yasuito@aichi-med-u.ac.jp

**Received:** January 18, 2021; **Accepted:** February 03, 2021; **Published:** February 10, 2021

**Citation:** Terashima S, Yamaguchi M, Katsuno T, Sugiyama H, Iwagaitsu S, Nobata H, et al. (2021) A Case of Eosinophilic Granulomatosis with Polyangiitis with Severe Peripheral Neuropathy Refractory to Standard Treatment Successfully Treated by Mepolizumab. *Rheumatology (Sunnyvale)*. 11:272.

**Copyright:** © 2021 Terashima S, et al. This is an open-access article distributed under the terms of the Creative Commons Attribution License, which permits unrestricted use, distribution, and reproduction in any medium, provided the original author and source are credited.

Weakness in the distal muscle groups in the lower limbs was also observed, resulting in bilateral foot drop and weakened hand grip motion, indicating sensorimotor polyneuropathy. No skin rash was observed. Laboratory data revealed leucocytosis (31800/ $\mu$ L) with eosinophilia (52.5%) and increased C-reactive protein level (11.6 mg/dl).

Kidney function was normal, with no haematuria or proteinuria. Both proteinase-3 (PR-3)/myeloperoxidase (MPO)-ANCA and indirect immunofluorescence ANCA were negative. Computed tomography revealed sinusitis, but not pulmonary lesion. His motor nerve conduction study (NCS) showed decreased amplitude of Compound Motor Action Potentials (CMAP) in bilateral tibial nerves. The sensory NCV study showed absence of Sensory Nerve Action Potentials (SNAP) in the bilateral sural nerves, and mildly decreased amplitude of SNAP in bilateral median and ulnar nerves. Head and spinal magnetic resonance imaging showed no abnormal findings. Sural nerve biopsy could not be performed; however, based on clinical features, including the history of sinusitis and bronchial asthma, peripheral eosinophilia, and peripheral neuropathy, EGPA was diagnosed. Ultrasound cardiography revealed normal cardiac function. The 2009 Five Factor Score was zero [15].

Methylprednisolone pulse therapy and administrations of methylprednisolone 60 mg/day, intravenous cyclophosphamide 500 mg biweekly, and intravenous immune globulin (0.4 g/kg/day  $\times$  5 days) were started as an induction treatment (Figure 1).

Although the patient's peripheral eosinophil count decreased to within the normal range 10 days after admission, neurologic symptoms had not improved; severe pain, numbness, hypoesthesia, and paraesthesia in both the upper and lower extremities continued. At 22 days after starting initial treatment, the prednisolone dose was tapered to 40 mg/day, and intravenous administrations of cyclophosphamide were started biweekly for three times; however, the neurological symptoms (pain and numbness in the upper and lower extremities) deteriorated with elevated peripheral eosinophil count (5590/ $\mu$ L), resulting in the difficulty of moving the lower extremities.

Hence, we considered the case refractory to standard treatment and began administering mepolizumab 300 mg subcutaneously at 23 days after admission. Immediately after initiating mepolizumab, clinical symptoms, such as severe pain and numbness in both the upper and lower extremities, markedly improved, which was associated with decreased eosinophilic count. Thereafter, mepolizumab 300 mg administered subcutaneously has been continued every 4 weeks. The glucocorticoid dose could have been tapered quickly. At 6 months after starting treatment, neurological symptom improved and rehabilitation enabled the patient to walk by himself, although foot drop was still present. The steroid dose was tapered to 8 mg/day, and no relapse was observed during the period when mepolizumab 300 mg was administered monthly for 5 months.

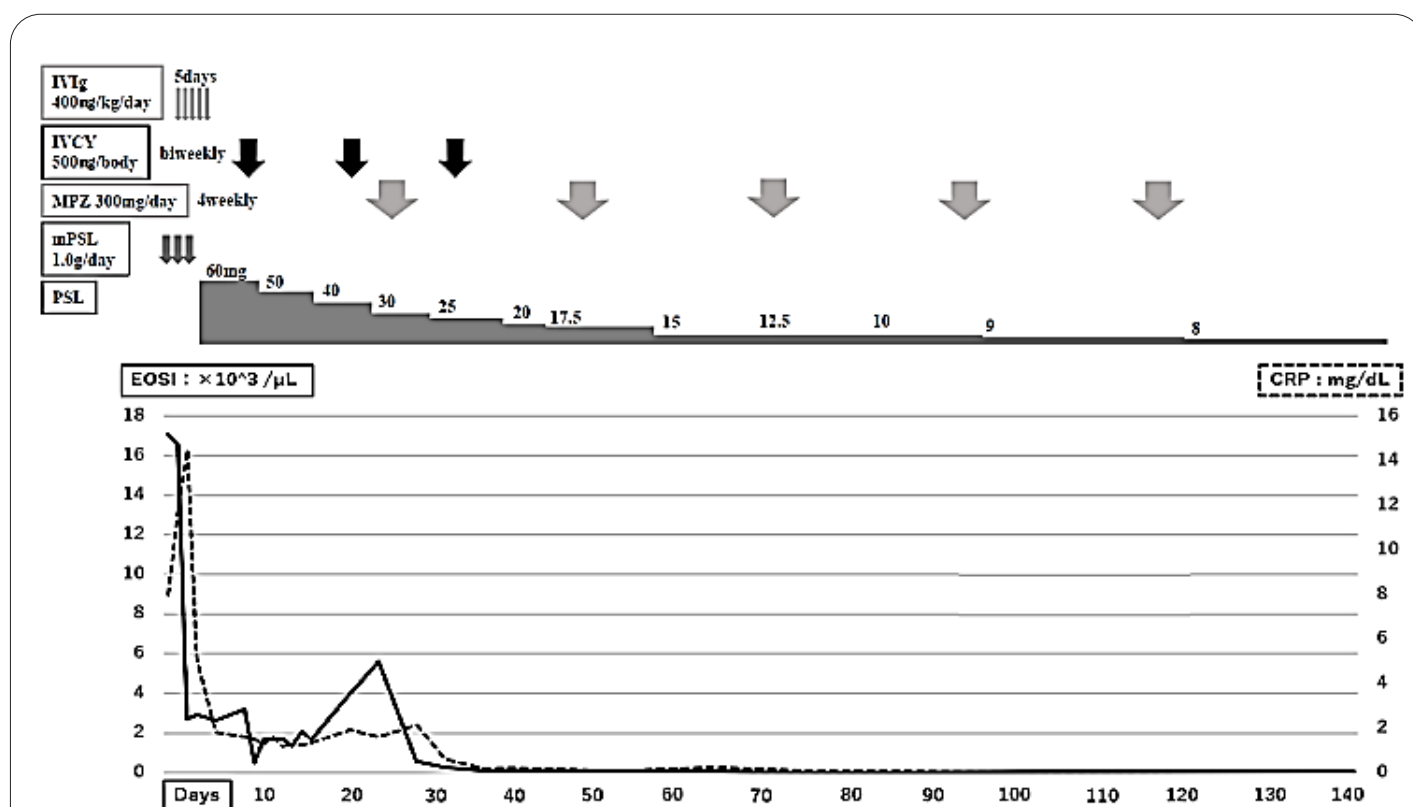


Figure 1: Clinical course of this case.

Mepolizumab was effective for improving the clinical symptoms and decreasing CRP levels in this case. CRP: C-reactive protein; EOSI: Eosinophils; IVCY: Intravenous Cyclophosphamide; IVIg: Intravenous Immune Globulin; mPSL: methylprednisolone, MPZ: Mepolizumab; PSL: Prednisolone.

## DISCUSSION

The present case highlighted the effectiveness of mepolizumab in an ANCA-negative EGPA case with severe peripheral neuropathy refractory to standard treatment, including administration of high-dose steroid, intravenous cyclophosphamide, and intravenous immune globulin.

Peripheral neuropathy is a common complication in patients with EGPA. In the largest published series of patients with EGPA, 51.4-60% had peripheral neuropathy at presentation [6,16]. Once peripheral neuropathy developed, regardless of treatment, the neuronal damage recovered slowly, and many patients had neurologic sequelae [5,17]. Neurologic sequelae were especially seen in severely ill patients in whom treatment was delayed, which significantly affected their future quality of life [17-19].

Therefore, it is essential to construct the optimal treatment strategy for peripheral neuropathy in EGPA. Basically, the primary initiating therapy is systemic glucocorticoids; an additional immunosuppressive agent is typically added in patients with more advanced or refractory disease and in those whose disease flares upon tapering of systemic glucocorticoids [20,21]. Cyclophosphamide is typically used in combination with glucocorticoids for patients with severe, multiorgan disease [20,21].

Furthermore, several case series have reported improvement in disease control in patients with refractory disease after addition of intravenous administration of high-dose immune globulin to glucocorticoids [22]. Recently, a multicentre randomised trial [11], including 136 patients with relapsing or refractory EGPA cases, showed clinical benefit of mepolizumab. Namely, over 52 weeks, treatment with mepolizumab, compared with placebo, was clinically beneficial and resulted in at least two-fold increase in the proportion of patients who achieved remission (from 19% to 53%), who could reduce their oral glucocorticoid dose by  $\geq 50\%$  (from 21% to 57%), or who were relapse-free (from 18% to 44%).

However, the results should be interpreted cautiously based on the following points. First, the study included only 56 (41.2%) patients with neuropathy, and information about the severity of neurological damage in each case was unknown. Furthermore, the study did not monitor whether organ damage, including neuropathy, had improved or continued.

Thus, it is unknown whether mepolizumab is effective for neuropathy or not. Second, this study included only patients with mild-to-moderate vasculitis activity because patients with organ-threatening damage were excluded. Moreover, the baseline median eosinophil count was relatively low (mepolizumab vs placebo: 177 vs 172/mm<sup>3</sup>), and the baseline prednisolone dose was also low (mepolizumab vs placebo: 11 vs 12 mg/day), showing lower eosinophil count and lower dose of prednisolone than our case.

Thus, the efficacy of mepolizumab for severe cases was unknown. Finally, the disease duration since diagnosis of EGPA at baseline was approximately 5 years; therefore, the effect of mepolizumab in the early phase after EGPA diagnosis was not elucidated. Considering the results, when mepolizumab should be started or what clinical characteristics are the best indicators for mepolizumab treatment it remained unclear.

To realise the optimal use of mepolizumab by evaluating the pathogenesis of peripheral neuropathy in EGPA, a retrospective study investigated the clinicopathologic features of 82 patients

with EGPA-associated neuropathy who underwent sural nerve biopsy, focusing on the presence or absence of MPO-ANCA [16]. The results indicated that the pathogenesis of EGPA comprises at least two distinct mechanisms: ANCA-associated vasculitis and eosinophil-associated vascular occlusion.

ANCA-associated vasculitis results in ischaemic effects and inflammation and is prominent in MPO-ANCA-positive patients. Eosinophil-associated vascular occlusion leads to ischaemia and eosinophil-associated tissue damage and is prominent in MPO-ANCA-negative patients. In our case, considering that neurological symptoms (i.e., lower extremity pain and numbness) improved immediately after starting mepolizumab, the nerve damage might have been predominantly due to eosinophil-associated inflammation.

Based on the results of this case report, early use of mepolizumab as an induction treatment, especially in ANCA-negative patients with peripheral neuropathy, might be a better strategy. This strategy suppresses the eosinophil-associated inflammatory reaction in the early phase, avoiding irreversible neurological damage and reducing total steroid dosage.

Future research should focus on evaluating and constructing the best treatment strategy, including the optimal timing and dose of and indications for mepolizumab, in addition to conventional treatment (steroids or immunosuppressants). To essentially elucidate this, obtaining genomic information to determine predictive tools that might have good response for mepolizumab may be essential [22-24].

## CONCLUSION

Early use of mepolizumab as an induction treatment might be an effective strategy, especially in ANCA-negative EGPA patients with polyneuropathy. Further studies should be undertaken to construct the best treatment strategy for EGPA.

## AUTHORS' CONTRIBUTIONS

All authors contributed to the concept and design of the study; performed data acquisition, analysis, and interpretation; drafted the manuscript; critically revised the manuscript for important intellectual content; and have read and approved the manuscript.

## REFERENCES

1. Lanham JG, Elkon KB, Pusey CD, Hughes GR. Systemic vasculitis with asthma and eosinophilia: a clinical approach to the Churg-Strauss syndrome. *Medicine (Baltimore)*. 1984;63(2):65-81.
2. Sinico RA, Bottero P. Churg-Strauss angiitis. *Best Pract Res Clin Rheumatol*. 2009;23(3):355-366.
3. Pagnoux C, Guilpain P, Guillevin L. Churg-Strauss syndrome. *Curr Opin Rheumatol*. 2007;19(1):25-32.
4. Fujimoto S, Watts RA, Kobayashi S, Suzuki, Jayne DRW, Scott DG, et al. Comparison of the epidemiology of anti-neutrophil cytoplasmic antibody-associated vasculitis between Japan and the UK. *Rheumatology*. 2011;50(10):1916-1920.
5. Sada KE, Amano K, Uehara R, Yamamura M, Arimura Y, Nakamura Y, et al. A nationwide survey on the epidemiology and clinical features of eosinophilic granulomatosis with polyangiitis (Churg-Strauss) in Japan. *Mod Rheumatol*. 2014;24(4):640-644.
6. Comarmond C, Pagnoux C, Khellaf M, Cordier JF, Hamidou M, Viallard JF, et al. Eosinophilic granulomatosis with polyangiitis (Churg-Strauss): clinical characteristics and long-term followup of the 383 patients enrolled in the French Vasculitis Study Group cohort. *Arthritis Rheum*. 2013;65(1):270-281.

7. Samson M, Puéchal X, Devilliers H, Ribi C, Cohen P, Stern M, et al. Long-term outcomes of 118 patients with eosinophilic granulomatosis with polyangiitis (Churg-Strauss syndrome) enrolled in two prospective trials. *J Autoimmun.* 2013;43:60-69.
8. Baldini C, Talarico R, Della Rossa A, Bombardieri S. Clinical manifestations and treatment of Churg-Strauss syndrome. *Rheum Dis Clin North Am.* 2010;36(3):527-543.
9. Mahr A, Moosig F, Neumann T, Szczeklik W, Taillé C, Vaglio A, et al. Eosinophilic granulomatosis with polyangiitis (Churg-Strauss): evolutions in classification, etiopathogenesis, assessment and management. *Curr Opin Rheumatol.* 2014;26(1):16-23.
10. Yates M, Watts RA, Bajema IM, Cid MC, Crestani B, Hauser T, et al. EULAR/ERA-EDTA recommendations for the management of ANCA-associated vasculitis. *Ann Rheum Dis.* 2016;75(9):1583-1594.
11. Wechsler ME, Akuthota P, Jayne D, Khoury P, Klion A, Langford CA, et al. Mepolizumab or placebo for eosinophilic granulomatosis with polyangiitis. *N Engl J Med.* 2017;376(20):1921-1932.
12. Brien CN, Gow MA. Mepolizumab for the treatment of eosinophilic granulomatosis with polyangiitis. *Drugs Today (Barc).* 2018;54(2):93-101.
13. Steinfeld J, Bradford ES, Brown J, Mallett S, Yancey SW, Akuthota P, et al. Evaluation of clinical benefit from treatment with mepolizumab for patients with eosinophilic granulomatosis with polyangiitis. *J Allergy Clin Immunol.* 2019;143(6):2170-2177.
14. Pradhan RR, Nepal G, Mandal S. Safety and efficacy of mepolizumab in patients with eosinophilic granulomatosis with polyangiitis. *Pulm Med.* 2019.
15. Guillevin L, Pagnoux C, Seror R, Mahr A, Mouthon L, Toumelin PL, et al. The five-factor score revisited: assessment of prognoses of systemic necrotizing vasculitides based on the French Vasculitis Study Group (FVSG) cohort. *Medicine (Baltimore).* 2011;90(1):19-27.
16. Nishi R, Koike H, Ohyama K, Fukami Y, Ikeda S, Kawagashira Y, et al. Differential clinicopathologic features of EGPA-associated neuropathy with and without ANCA. *Neurology.* 2020;94(16):e1726-e1737.
17. Moosig F, Bremer JP, Hellmich B, Holle JU, Holl-Ulrich K, Laudien M, et al. A vasculitis centre based management strategy leads to improved outcome in eosinophilic granulomatosis and polyangiitis (Churg-Strauss, EGPA): monocentric experiences in 150 patients. *Ann Rheum Dis.* 2013;72(6):1011-1017.
18. Zhang Z, Liu S, Guo L, Wang L, Wu Q, Zheng W, et al. Clinical characteristics of peripheral neuropathy in eosinophilic granulomatosis with polyangiitis: a retrospective single-center study in China. *J Immunol Res.* 2020.
19. Padoan R, Marconato M, Felicetti M, Cinetto F, Cerchiaro M, Rizzo F, et al. Overall disability sum score for clinical assessment of neurological involvement in eosinophilic granulomatosis with polyangiitis. *J Clin Rheumatol.* 2018;24(4):197-202.
20. Bosch X, Guilabert A, Espinosa G, Mirapeix E. Treatment of antineutrophil cytoplasmic antibody associated vasculitis: a systematic review. *JAMA.* 2007;298(6):655-669.
21. Furuta S, Iwamoto T, Nakajima H. Update on eosinophilic granulomatosis with polyangiitis. *Allergol Int.* 2019;68(4):430-436.
22. Tsurikisawa N, Taniguchi M, Saito H, Himeno H, Ishibashi A, Suzuki S, et al. Treatment of Churg-Strauss syndrome with high-dose intravenous immunoglobulin. *Ann Allergy Asthma Immunol.* 2004;92(1):80-87.
23. Lyons PA, Peters JE, Alberici F, Liley J, Coulson RMR, Astle W, et al. Genome-wide association study of eosinophilic granulomatosis with polyangiitis reveals genomic loci stratified by ANCA status. *Nat Commun.* 2019;10(1):5120.
24. Marvisi C, Sinico RA, Salvarani C, Jayne D, Prisco D, Terrier B, et al. New perspectives in eosinophilic granulomatosis with polyangiitis (EGPA): report of the first meeting of the European EGPA Study Group. *Intern Emerg Med.* 2019;14(8):1193-1197.