

Primary extradural lymphoma with marginal zone transformation: A rare presentation

Shuchita Pathak* and **Santhosh KD**

M S Ramaiah Medical College, India

A 38 year old female presented in our institute with 2 months history of paraparesis with loss of sensation below Umbilicus. Diagnostic workup revealed extradural mass at thoracic vertebral level 4 to 6. She underwent D3-D6 laminoplasty with excision of lesion. Histopathology report revealed Non Hodgkin lymphoma for follicular centre cell type with marginal zone transformation. On further evaluation PET-CT scan was done which confirmed localized primary extradural location of Non-Hodgkin lymphoma. She received modified R-GMALL protocol chemotherapy [Figure 1]. Her neurological condition improved at end of chemotherapy.

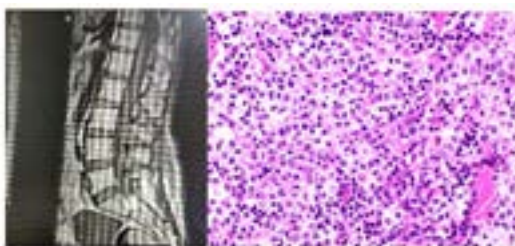


Figure 1. R-GMALL protocol chemotherapy.

Biography

Shuchita Pathak is working as DM medical oncology resident in M S Ramaiah Medical College, Bangalore. She completed her MBBS in 2014 from GMC Haldwani Medical College in Uttarakhand. After that she completed her DNB radiation oncology post-graduation from Bhagwan Mahaveer Cancer Hospital, Jaipur. After completing her post-graduation she worked as senior resident in AIIMS New Delhi for 1 year and after