

12th International Congress on**Microbial Interaction and Applications of Beneficial Microbes**

July 17-18, 2017 Munich, Germany

Histopathological study for the effect of Intra -peritoneal (I.P) and subcutaneous (S.C) infection with different doses of *Pasteurella multocida* in Swiss mice

*Waffa A Ahmed and **Al-Gbouri Nagham M

*Department of Microbiology

**Zoonoses unit College of veterinary medicine, University of Baghdad

Haemorrhagic septicaemia (HS) is an endemic disease of bovine, occurring in most tropical regions of Asia and Africa. *P. multocida* Robert-1 carter B is responsible for Asian HS. This study was conducted to evaluate the histopathological changes induced by I.P and S.C inoculation of *P. multocida* Robert-1, Carter:B and suitability of mice for the experimental infection. Thirty apparently healthy Swiss mice of both sexes aged between 7-8 weeks, weighted 13-16g were divided into two main groups: (infective group), consist of 18 mice, which was divided into three groups, each group subdivided into two subgroups (3 mice in each group), the subgroup (A1,B1) of 1st group infected with 0.1ml (104 cfu). (I.P) and (S.C). The subgroups of 2nd group (A2,B2), and 3rd group (A3,B3) were infected with (102 cfu), (50 cfu) respectively with the same routes as above. Second control group was subdivided into three control groups (4 mice) in each group, each group subdivided into two subgroups (C1,B1), (C2,B2), (C3,B3), each subgroup consist of two mouse, these subgroups were inoculated 0.1 ml Phosphate buffer saline through related route for each subgroup. Specimens from (liver, spleen, lung, kidney, heart and Brain) from infected alive and died mice, after scarification, were placed immediately in 10% formalin, after processing, and staining, histopathological examination was carried out. Results of the present study indicate that even 50CFU inoculum was enough to cause (100%) mortality in mice, also the results showed degrees of degenerative changes and necrosis, hemorrhage and infiltration of inflammatory cells were the most observed lesions in all the organs, while thrombosis and edema were the least observed, following route and dose of bacterial inoculum. The study concluded that the mice seem to provide an ideal tool to study the histopathological changes of HS in cattle and buffaloes due to the similarity of lesions with those animals infected naturally or experimentally with *P. multocida*.

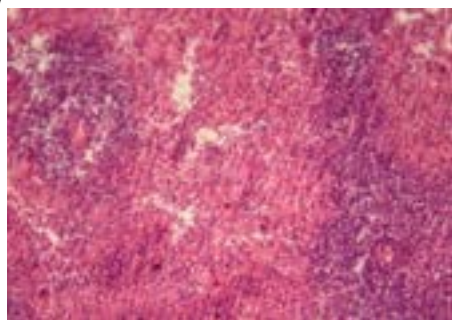


Figure 1: Spleen of mice from the (subgroup B2) died within 24 hr., showed mild hyperplasia of white pulp with diffuse infiltration of PMNs in white and red pulp (H & E ×40).

Biography

Waffa A. Ahmed has completed PhD at the age of 48 years from University of Baghdad, she worked as ahead of department of quality control – Veterinary state company – Ministry of Agriculture, (2005–2006), she has worked for eight years as assistant professor and Scientific researcher in Unit of Zoonotic researches. (2006–2014), also in Department of Microbiology (2014 – 2016), College of Vet. Medicine – University of Baghdad she had participated in several conferences in different universities of Iraq, she had participated in many examining committees for postgraduate students in Baghdad University and other universities in Iraq. She had taught more than seven courses for under and Post graduate students (Diploma, M.Sc. and PhD) in pathology, microbiology, zoonotic diseases in college of Vet. Med. and College of Dentist. She supervised number of postgraduate students (Diploma & M.Sc., PhD). She has published more than thirty paper in reputed journals and has been serving as an editorial board member of research journal of biology and reviewed more than 100 articles in about seven journals and more than 20 thesis (scientific evaluation).

Waffaabduleah@yahoo.com