

# 20<sup>th</sup> European **Cardiology** Conference

October 16-18, 2017 | Budapest, Hungary

## CABG in diffuse coronary artery disease

Shyam K Ashok

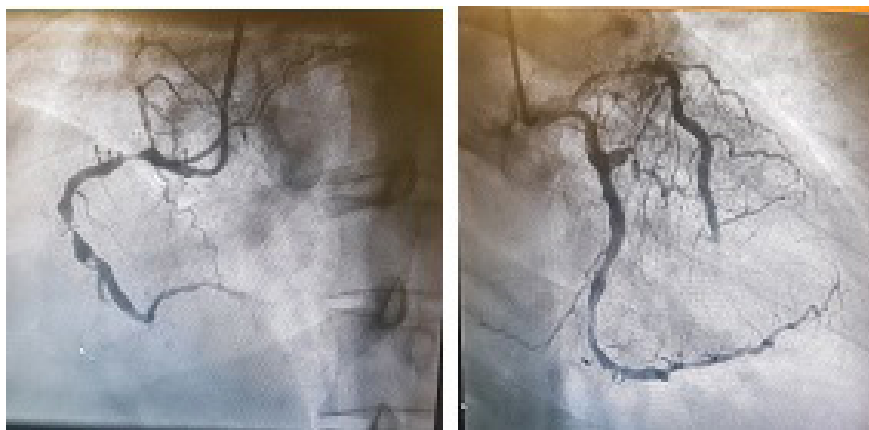
Aster CMI Hospital, India

**Statement of the Problem:** In India, 2.78 million deaths are due to cardiovascular diseases of which 50 % are due to CAD. Peculiarities of CAD patterns in Indian patients younger age at presentation, high incidence of DVD and TVD, diffuse involvement, distal disease and significant LV dysfunction at presentation. Diffuse CAD: Length of significant stenosis > 20 mm, multiple significant stenosis (> 70% narrowing) in the same artery separated by segment of apparently normal vessel and significant narrowing involving the full length of coronary artery.

**Methodology:** We in our institute, perform OP CAB and use LIMA and veins as conduits to perform the surgery. Once the conduits are harvested, we heparinize with I.V. Heparin 3 mg/Kg given to achieve an ACT >300. Using the octopus as stabilizer, we perform an endarterectomy of the LAD first and then use a vein patch to cover the defect. LIMA is then used to anastomose the LAD on the vein patch. Veins are used to bypass the LCX and RCA, as deemed appropriate. The proximal ends of the vein grafts are anastomosed to ascending aorta with side clamp and heart beating. Intra op we start Lomodex infusion 20ml/hr which is continued for 24 hours and the inotropes used are Adrenaline and Dobutamine as and when necessary. Postoperatively aspirin 75mg is given and Heparin infusion started after 6hours to maintain ACT of around 150 for 24 hours. Patients are usually extubated after 4 hours provided they are hemodynamically stable. Anticoagulation by Acitrom is commenced orally from day 1 to maintain an INR of 2 for 3 months.

**Result:** Out of the 20 patients in last 18 months outcomes have been excellent with no in-hospital mortality or cerebrovascular incidents.

**Conclusion:** Off-pump CABG with coronary endarterectomy offers a good solution to the problem of diffuse coronary artery disease.



## Biography

Shyam K Ashok has completed his MBBS and MS in General Surgery; MCh in CVTS from Seth GS Medical College, Mumbai in 2008. He later joined Narayana Hrudayalaya, Bangalore in 2008, which is a 1000 bedded hospital executing close to 600 open heart surgeries in a month. He worked as a Fellow in Adult Cardiothoracic department in Royal Melbourne Hospital, Australia, which is the second largest cardiothoracic unit in the whole of Australia. After working in Australia for two years, he rejoined Narayana Hrudayalaya, as Consultant Cardiothoracic Surgeon in 2012 and worked there till 2015. He has independently performed about 1000 open heart surgeries, consisting of coronary artery bypass surgeries and valve replacements. His area of interest is Coronary Artery Bypass, especially Total Arterial Revascularization. He joined Aster CMI Hospital in Feb 2016 as Consultant Cardiothoracic Surgeon.

shyams2u@yahoo.co.uk