

20th European **Cardiology** Conference

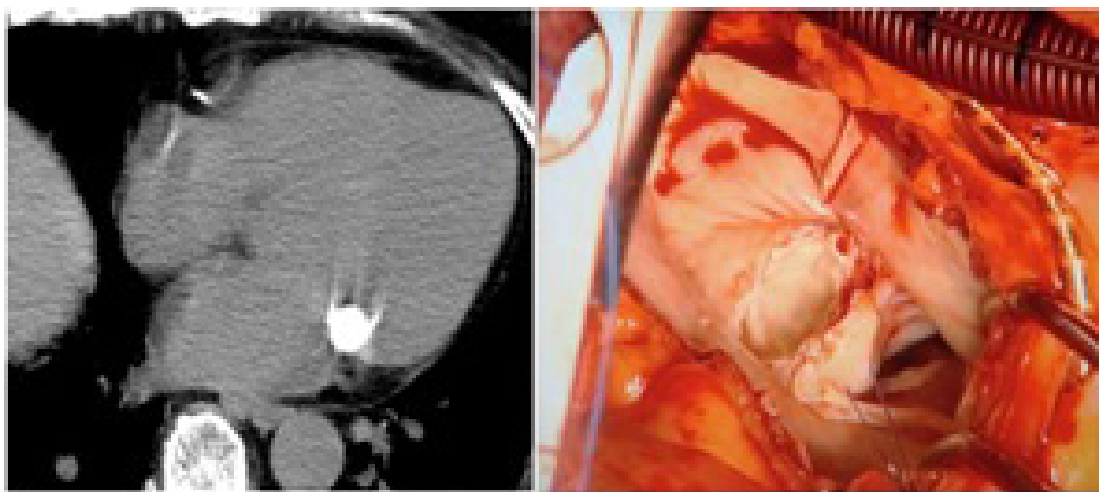
October 16-18, 2017 | Budapest, Hungary

Serial changes on computed tomographic findings of caseous calcification of the mitral annulus

Yoshinori Enomoto

Kimitsu Chuo Hospital, Japan

A 74-year-old female with interstitial pneumonia and old myocardial infarction was admitted with stroke because of calcific emboli. Caseous calcification of the mitral annulus was detected using computed tomography (CT) and transthoracic echocardiography during the follow-up of the interstitial pneumonia and myocardial infarction, respectively. On recent examination, echocardiography showed caseous calcification of the mitral annulus. CT revealed an oval calcification with a homogeneous density in and a scattered calcification under the posterior mitral annulus, which was detected for the first time and could not be detected by echocardiography. Rupture of the caseous calcification was suspected. Surgical treatment was postponed because the interstitial pneumonia worsened. CT performed during treatment of pneumonia showed changes in the shape and density of caseous calcification; however, scattered calcification under the mitral annulus persisted. Operative findings were consistent with signs on CT, i.e., a white, soft, plaster-like content and a similar scattered material around the chordae of the posterior leaflet. The sequences of changes of caseous calcification of the mitral annulus obtained by CT suggest its importance as a follow-up tool and indicate the necessity and timing of surgery.



Biography

Yoshinori Enomoto is currently working as a Director of Department of Cardiovascular Surgery at Kimitsu Chuo Hospital. He completed his PhD degree in Medicine from Akita University in 2007 and worked as an Assistant Professor of Intensive Care Unit at Akita University Hospital for a period of one year. He completed his Residency in General Surgery at Funabashi Municipal Medical Care Center from 2008 to 2010. And he was a Medical Specialist at Chiba Prefecture for Cardiovascular Surgery from 2010 to 2012. He is currently a member of different Japanese Associations as follows: the Japanese Association for Thoracic Surgery, the Japanese Society for Cardiovascular Surgery, the Japanese Society for Vascular surgery, the Japanese Society of Pediatric Cardiology and Cardiac Surgery, and the Japanese Circulation Society. His main profession is Cardiovascular Surgery and other related matters.

y.e18730@gmail.com