

The combined use of Adrenocorticotrophic hormone (ACTH) and Calcineurin inhibitor (CNI) in the treatment of Refractory Nephrotic Syndrome in a child

Amirtha Chinnadurai*, Julie E. Goodwin

Department of Pediatrics, Yale University School of Medicine, Connecticut, USA

Abstract

Background: Primary podocytopathies including Focal Segmental Glomerulosclerosis (FSGS) have been recognized to show variable responses to conventional treatment and overall prognosis. Persistent failure to respond to therapies remains a vexing problem for clinicians. ACTH has recently resurged as a therapy for treatment-resistant podocytopathies. We describe a case of steroid-resistant NS in a 10-year-old boy with a history of multiple failed secondary therapies, who showed partial response to biweekly ACTH therapy. Further clinical improvement was observed with the addition of the calcineurin inhibitor (CNI), tacrolimus.

Case description: A 10-year-old Hispanic boy, diagnosed with frequently-relapsing steroid sensitive NS at the age of 2, and was largely relapse-free for 5 years on Cyclosporine A (CsA). Within two months after a trial off CsA, he relapsed. His course was complicated by more frequent relapses and steroid resistance. Renal biopsy performed at this time showed early focal segmental glomerulosclerosis (FSGS) and no signs of CsA-induced nephropathy. Whole exome sequencing revealed a heterozygous variant of uncertain significance in *PLCE1* (Phospholipase C Epsilon 1). Trials of the steroid sparing agents tacrolimus and mycophenolate mofetil, both with and without steroids, were ineffective. He had several prolonged hospitalizations due to poorly controlled relapse. He became dependent on biweekly 25% albumin infusions. His renal function deteriorated from a baseline creatinine of 0.3 mg/dl to 0.7 mg/dl due to multiple episodes of acute kidney injury. ACTH initiated at a low dose of 40 units/1.73 m² biweekly was ineffective. Three months later, the dose was increased to 80 units/1.73 m² biweekly and he achieved partial remission and renal function returned to baseline. Tacrolimus was added at 6 months for synergy with trough levels maintained between 3-5 ng/ml. He achieved partial remission, and avoided further hospitalizations.

Conclusion: ACTH alone or in combination with calcineurin inhibitor (CNI) can be a viable alternative for children who are resistant to other therapies. Variability in renal phenotype has been implicated with the *PLCE1* (Phospholipase C Epsilon 1) gene. In this case, we suspect the role of his heterozygous variant *PLCE1* mutation, or likely a compound heterozygous state with another unidentified mutation or modifiers or environmental factors, plays a role in the progression to a refractory NS state.

Abbreviations: NS: Nephrotic Syndrome; ACTH: Adrenocorticotrophic Hormone; CNI: Calcineurin Inhibitor; FSGS: Focal Segmental Glomerulo Sclerosis; CsA: Cyclosporin A; MMF: Mycophenolate mofetil; ACEi: Angiotensin Converting Enzyme inhibitor; UPC: Urine Protein/Creatinine Ratio; WES: Whole Exome Sequencing; MC1R–Melanocortin1 Receptor; MGN: Membranous Glomerulopathy

Citation: Chinnadurai A, Goodwin JE (2020) The combined use of Adrenocorticotrophic hormone (ACTH) and Calcineurin inhibitor (CNI) in the treatment of Refractory Nephrotic Syndrome in a child. *Adv Pediatr Res* 7:39. doi: 10.35248/2385-4529.20.7.39

Received: April 27, 2020; **Accepted:** May 18, 2020; **Published:** May 26, 2020

Copyright: © 2020 Chinnadurai, et al. This is an open access article distributed under the terms of the Creative Commons Attribution License, which permits unrestricted use, distribution, and reproduction in any medium, provided the original work is properly cited.

Competing interests: The authors do not have any competing interests.

*E-mail: amirtha_v@yahoo.com

Introduction

Primary podocytopathies in childhood idiopathic nephrotic syndrome (NS) include minimal change disease (MCD) and focal segmental glomerulosclerosis (FSGS). While the clinical presentation of these two diseases is similar, they differ in steroid responsiveness and prognosis [1]. Response to corticosteroids remains the best prognostic marker for childhood nephrotic syndrome [2]. The majority of children with idiopathic NS show steroid responsiveness, but 40-50% become frequently relapsing or steroid dependent [3]. Interestingly, steroid resistant NS may present with the initial episode of NS or as a late event, months to years after initial steroid sensitivity [2]. Steroid resistant NS remains a challenging clinical entity due to limited therapeutic options and poor renal outcomes with 36-50% progressing to end stage renal disease within 10 years [4].

ACTH has been described as a treatment for proteinuria and hyperlipidemia in childhood NS since the 1950s [5]. This therapy reappeared in the late 1990s when synthetic ACTH was found to effectively reduce proteinuria in adults with membranous nephropathy, MCD and FSGS in several small case studies [1,2]. More recently, the ATLANTIS trial examining the safety and efficacy of ACTH in children with frequently relapsing NS, was terminated early because it showed that ACTH was ineffective in preventing relapse [6]. However, a shortcoming of this large trial was the lack of investigation of the possible synergy between ACTH and other steroid-sparing agents such as calcineurin inhibitors. This combination therapy has been found to increase both complete and partial remission in a small adult study [7].

Case Presentation

A 10-year old Hispanic boy who was diagnosed with frequently-relapsing steroid sensitive nephrotic syndrome at the age of 2, had remained largely in remission for 5 years with a combination of Cyclosporine A (CsA) and steroids. Within two months of attempting to discontinue cyclosporine the patient had relapsed again and re-initiation of CsA did not maintain remission, though he still responded to steroids. Triggers for his relapses included viral upper respiratory tract and gastrointestinal infections. Renal biopsy revealed

early changes of Focal Segmental Glomerulosclerosis (FSGS) which were enlarged glomeruli with focal pericapsular fibrosis, increased mesangial cellularity, marked increase in mesangial matrix and effacement of foot processes (50%) and no evidence of CsA-induced nephropathy. No clinical improvement in the frequency of relapses was observed despite the addition of tacrolimus at a dose of 0.05 mg/kg twice a day, titrated to maintain a trough of 2-4 ng/ml, in addition to steroids for duration of 12 months. Similar poor response was observed with initiation of mycophenolate mofetil (MMF) 600 mg/m² twice daily dose for 7 months. In addition to these secondary agents, a trial of triple therapy (tacrolimus, MMF and steroids) failed to induce remission. Figure 1 summarizes the duration and type of therapy that was used from onset of diagnosis

Clinically, he developed ongoing, uncontrolled relapse which led to multiple prolonged hospitalizations. He became dependent on twice weekly 25% albumin infusions due to persistent hypoalbuminemia (<1.5g/dl) and anasarca. He was prescribed angiotensin converting enzyme inhibition (ACEi) with Lisinopril 10 mg daily with minimal improvement. Supportive care to prevent NS-related complications was initiated including immunoglobulin replacement with subcutaneous immunoglobulin G (Hizentra™), lipid lowering therapy with pravastatin, thyroid hormone replacement with Synthroid and thromboembolic prophylaxis with aspirin. His worsening clinical progression led to additional genetic work up to look for mutations that may explain his uncontrolled relapse. Whole exome sequencing showed a heterozygous variant in the *PLCE1* gene.

Laboratory findings showed a serum albumin level of 0.9-1.2 g/dl, nephrotic range proteinuria and urine protein/creatinine (UPC) ratio ranging from 4.0 to 61.39 mg/mg. During 18 months of uncontrolled relapse, he had 5 episodes of AKI during which his serum creatinine increased to 0.70-0.80 mg/dl, from a baseline of 0.30-0.40 mg/dL.

At that time, adrenocorticotrophic hormone (H.P. Acthar™ gel) was started at an initial dose of 40 units/1.73 m² biweekly. After 3 months of minimal response, the dose was increased to 80 units/1.73 m² biweekly. At the higher dose he demonstrated clinical improvement with the urine protein/

creatinine ratio decreasing by more than 50% and the serum creatinine reverting to his baseline of 0.30 mg/dl. Biweekly parenteral 25% albumin infusions were discontinued after spontaneous improvement in albumin to 2.0 g/dl. After 6 months of ACTH therapy, tacrolimus was added for synergy and the dose titrated to maintain trough

levels between 3-5 ng/ml (Figure 2). He continues to remain in partial remission with this combination therapy. Though he still experiences partial relapses with viral infections during which time his albumin drops below 2.0 g/dl, these episodes are generally well-tolerated and he has not required hospitalization.

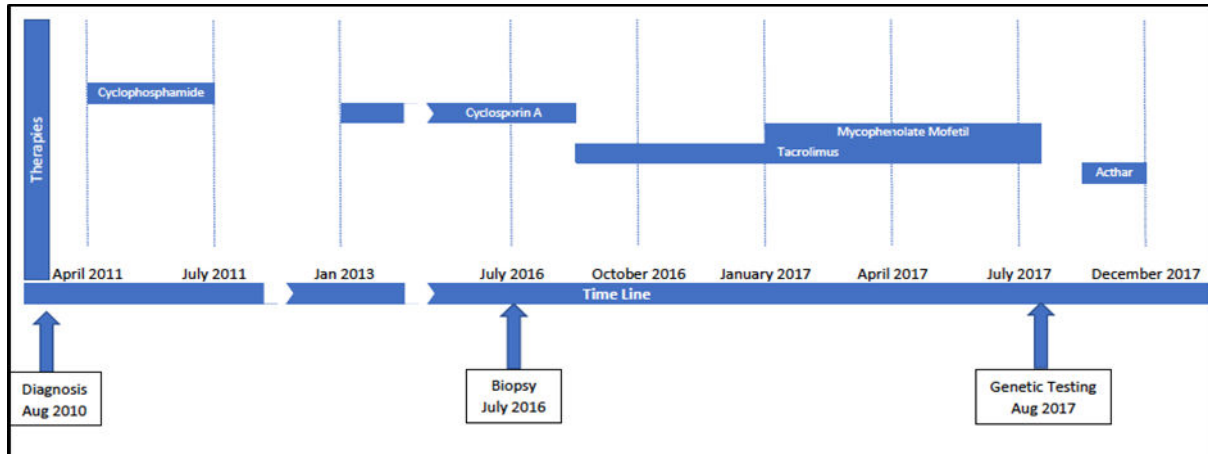


Figure 1: This graph illustrates the types of treatment initiated from the time of diagnosis until ACTH initiation.

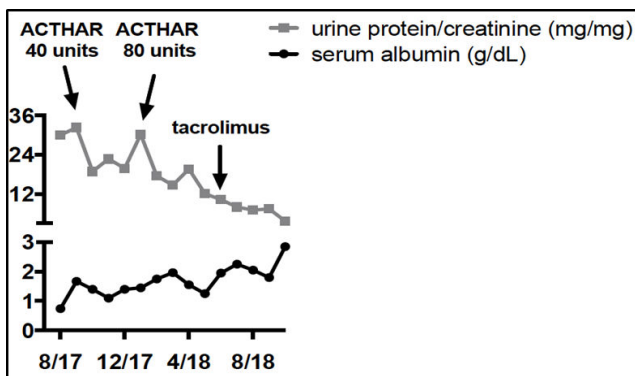


Figure 2: The above graph shows the concurrent trend of urine protein/creatinine (mg/mg) and serum albumin (g/dl) for a period of one year, from Aug 2017 (08/17) until Aug 2018 (08/18).

Discussion

Primary or idiopathic nephrotic syndrome (NS) is one of the most common glomerular diseases in children [3] and it can be caused by loss or altered function of the podocytes, resulting in massive proteinuria. Idiopathic NS can be classified based on steroid responsiveness, pattern of relapse, histopathology or by genetic mutations [8]. The etiology of idiopathic NS is elusive, though an increasing number of genetic abnormalities are being detected which include defects in the proteins

expressed by podocytes, the slit-diaphragm or the cytoskeletal structure, which can lead to podocyte damage and proteinuria [9].

In this case, we describe a child who was initially steroid-responsive and had a 5-year period of stability while on CsA. However, he progressively became un-responsive to steroids, and to several secondary steroid-sparing agents. We postulate that his clinical course may be related to his underlying heterozygous *PLCE1* mutation. While homozygous *PLCE1* mutations are known to present with steroid resistant phenotype, we suspect his underlying heterozygous mutation may play a role in the clinical progression. Lowik et al. described a case of steroid-resistant FSGS with a heterozygous *PLCE1* mutation [9]. The development of a renal phenotype in this setting remains unclear and the authors speculated that it was possibly due to the presence of another causative variant that had not been detected [9]. Thus, these authors suggest a role of combined gene defects in the development of this disease phenotype [9]. Given that whole exome sequencing (WES) covers only protein-coding regions of the genome, which account for only about 2% of human DNA [10], it is not surprising that clinically relevant genetic mutations may not be detected using this technique. Furthermore, variability in the renal phenotype has been

described in families with *PLCE1* mutations [11]; therefore, it is conceivable that modifier genes or environmental factors may play a role in the phenotypic variability in these patients [11].

The use of ACTH emerged in the 1950s and was predominantly used to treat children with NS who were treatment-naïve. Prior to the discovery of ACTH in the late 1940s [12], there were no reliable treatments that provided symptomatic relief or remission of NS and mortality rates were reported to be as high as 40-71% within 4-5 years of disease onset [13]. ACTH was found to reduce gross edema via diuresis with short-term treatment and induce remission with longer-term treatment. The effects of ACTH were believed to be mediated via steroidogenesis, and, as such, the intravenous ACTH was then replaced by oral prednisone in the 1960s due to ease of administration [13].

ACTH therapy, also known as repository corticotropin injection (H.P. Acthar™ gel), is a highly purified, prolonged-release porcine preparation of adrenocorticotrophic hormone analogue. The mechanism underlying responsiveness to ACTH in the face of resistance to oral prednisone is unclear but may involve a steroid-independent mechanism. ACTH exerts its effects via two pathways: (1) steroid-dependent or (2) steroid-independent pathway of extra-adrenal melanocortin effects [12]. The former induces steroidogenesis, which promotes anti-inflammatory effects, while the latter induces effects via the melanocortin receptor (MC1R), which is present on podocytes, glomerular endothelial cells, and mesangial cells [12]. MC1R agonists have been found to reduce proteinuria in an animal model [12]. This observation may provide a rationale for the use of ACTH in problematic patients with steroid-dependent, frequently-relapsing and steroid-resistant NS.

The recently published ATLANTIS trial was the first randomized control trial to examine the safety and efficacy of ACTH for a 12-month period in children with steroid dependent, frequently-relapsing NS. The study was terminated earlier than planned due to the finding that ACTH 80 unit/1.73 m² biweekly proved ineffective in preventing relapses and maintaining disease remission [6]. However, these results contrast with our patient's course; this patient responded favorably with partial remission, and improved renal function.

The combination of tacrolimus and ACTH was trialed, following the results from a small prospective trial involving adults with membranous glomerulopathy (MGN) and FSGS which showed that combination therapy increased complete and partial response rates to 17% and 66%, respectively, when compared to the complete and partial response rates of ACTH alone which were 7.7% and 62%, respectively [7]. In terms of the mechanism of action of this combination therapy, ACTHar is described as inducing its effects via melanocortin 1 receptors in the glomerular podocytes. These receptors have been shown to co-localize with synaptopodin, which is highly expressed in podocytes [7]. The antiproteinuric effect of calcineurin inhibitors stems from inhibition of calcineurin-mediated dephosphorylation of synaptopodin, which maintains the integrity of the podocyte function and filtration barrier [14]. This suggests that the combination of melanocortin agonist like ACTHar and CNI may reduce the effects of proteinuria via a synergistic effect on the podocyte cytoskeleton. To date, similar combination therapy has not been evaluated systematically in children.

Conclusion

ACTH in combination with CNI can serve as a viable therapy in children who are refractory to conventional therapies (tacrolimus, cyclosporine, mycophenolate mofetil with and without steroids). In our opinion, a later progression to a steroid resistant state is likely related to the underlying heterozygous *PLCE1* mutation combined with other unidentified mutations or modifiers that enable a 'second-hit' phenomenon which produces this phenotype. Further studies examining novel podocyte genes, epigenetic modifications or non-coding genomic DNA may eventually provide insight into the pathophysiology of this disease.

Declarations

Ethics approval and consent to participate

Not applicable.

Consent for publications

Written informed consent was obtained from the patient's mother for publication of this case report.

A copy of this consent is available for review by the Editor of this journal.

Availability of data and material

Not applicable.

Competing interests

Authors have no competing interests.

Funding

No funding received for this case report.

Authors' contributions

AC wrote and conceptualized the clinical case, compiled and interpreted the relevant data, drafted the manuscript and approved the final version of the manuscript. JG conceptualized the clinical case, compiled and interpreted the relevant data, revised and edited the manuscript and approved the final version of the manuscript. All authors of this manuscript have read and approved the final manuscript.

Acknowledgements

Not applicable.

References

1. Filippone E, Dopson S, Rivers D, Monk R, Udani S, Jafari G, et al. Adrenocorticotrophic hormone analog use for podocytopathies. *Int Med Case Rep J*. 2016;9:125-133.
2. Crawford B, Gipson D. Improving the evidence for the management of childhood nephrotic syndrome. *Kidney International*. 2017;92(1):21-23
3. Niaudet P. Long-term outcome of children with steroid-sensitive idiopathic nephrotic syndrome. *Clin J Am Soc Nephro*. 2009;4(10):1547-1548.

4. Mekahli D, Liutkus A, Ranchin B, Yu A, Bessenay L, Girardin E, et al. Long-term outcome of idiopathic steroid-resistant nephrotic syndrome: a multicenter study. *Pediatric Nephrology*. 2009;24(8):1525-1532.
5. Rapoport M. Effect of Corticotropin (ACTH) on children with the nephrotic syndrome. *JAMA*. 1951;147(12):1101.
6. Wang C, Travers C, McCracken C, Leong T, Gbadegesin R, Quiroga A, et al. Adrenocorticotrophic hormone for childhood nephrotic syndrome. *Clin J Am Soc Nephro*. 2018;13(12):1859-1865.
7. Tumlin J, Galphin C, Santos R, Rovin B. Safety and efficacy of combination acthar gel and tacrolimus in treatment-resistant focal segmental glomerulosclerosis and membranous glomerulopathy. *Kidney International Reports*. 2017;2(5):924-932.
8. Noone D, Iijima K, Parekh R. Idiopathic nephrotic syndrome in children. *The Lancet*. 2018;392(10141):61-74.
9. Lowik M, Levtchenko E, Westra D, Groenen P, Steenbergen E, Weening J, et al. Bigenic heterozygosity and the development of steroid-resistant focal segmental glomerulosclerosis. *Nephrol Dial Transpl*. 2008;23(10):3146-3151.
10. Eichinger A, Ponsel S, Bergmann C, Günthner R, Hoefele J, Amann K, et al. Cyclosporine A responsive congenital nephrotic syndrome with single heterozygous variants in *NPHS1*, *NPHS2*, and *PLCE1*. *Pediatric Nephrology*. 2018;33(7):1269-1272.
11. Benoit G, Machuca E, Antignac C. Hereditary nephrotic syndrome: a systematic approach for genetic testing and a review of associated podocyte gene mutations. *Pediatric Nephrology*. 2010;25(9):1621-1632.
12. Lieberman K, Pavlova-Wolf A. Adrenocorticotrophic hormone therapy for the treatment of idiopathic nephrotic syndrome in children and young adults: A systematic review of early clinical studies with contemporary relevance. *Journal of Nephrology*. 2016;30(1):35-44.
13. Rance CP, Chute AL. Treatment of the nephrotic syndrome in children. *Can Med Assoc J*. 1955;73(12):959-964.
14. Faul C, Donnelly M, Merscher-Gomez S, Chang Y, Franz S, Delfgaauw J, et al. The actin cytoskeleton of kidney podocytes is a direct target of the antiproteinuric effect of cyclosporine A. *Nature Medicine*. 2008;14(9):931-938.