

## Management of Open Bite

\*Prasad Mandava

\*\* Ashok Kumar

\*Professor and HOD of Orthodontics, Narayana Dental College, Nellore.

\*\* reader, Department of Orthodontics, Narayana Dental College, Nellore.

**Abstract** ; Open bite is a malocclusion that occurs in the vertical plane, characterized by lack of vertical overlap between the maxillary and Mandibular dentition. **The anterior open bites particularly skeletal open bites are called as “stigmata of malocclusion”.** The varied etiological characteristic features of openbite are discussed in this article. Openbites are easy to diagnose but difficult to retain. The various modes of treatment are also discussed depending upon the age of the patient.

Key words; Openbite, etiology, treatment plan.

### Introduction

Open bite is a malocclusion that occurs in the vertical plane, characterized by lack of vertical overlap between the maxillary and Mandibular dentition. Open bites can occur in the anterior and the posterior region and are called anterior open bite and posterior open bite respectively.<sup>1-3</sup>

The diagnosis, treatment, and successful retention of treated open bite malocclusion pose a challenge to the technical ability and skills of the clinicians. Many potential etiologic factors are implicated as causes of open bite including heredity, unfavorable growth patterns, digit-sucking habits, tongue and orofacial muscle abnormal function, orofacial functional matrices and their interaction with the skeletal components, imbalances between jaw posture, occlusal and eruptive forces and head position. A detailed understanding of its etiology and developmental process is thus essential in its management.

**Epidemiology** Openbites occur less frequently than deep bites. Severe deep bite (overbite of 5 mm) is found in nearly 20% of children and 13% of adults, while open bite (negative overbite >-2 mm) occurs in less than 1%.

### **ANTERIOR OPEN BITE**

An **anterior** open bite (AOB) may be defined as a negative overbite between the incisal edges of the maxillary and mandibular **anterior** teeth, with the posterior teeth in occlusion. Thus in anterior openbite there is no vertical overlap between the upper and lower anteriors. Anterior open bites are esthetically unattractive particularly during speech when the tongue is pressed between the teeth and lips. The anterior openbites particularly skeletal open bites are called as “stigmata of malocclusion”

### **Etiology of anterior open bite( Fig 1 and 2)<sup>4,5,6</sup>**

The etiology of anterior open bite is multifactorial. Anterior open bites can occur due to variety of hereditary and non-hereditary factors. The resultant openbite is an interaction between these factors. The following are some of the etiologic factors responsible for anterior open bites :

1. Heredity with genetic disposition  
Inherited factors such as increased tongue size, and abnormal skeletal size and growth pattern of the maxilla and mandible can also be responsible for open bite malocclusion.

### **Habits**

- i. Prolonged thumb-sucking habit is one of the chief etiological factors of open bite. The posture of thumb positioning, the intensity, and the frequency of sucking, all have an influence on the nature and severity of the open bite.
- ii. Tongue thrusting is also implicated for some cases of open bite. Tongue thrusting may develop as a complication of thumb sucking habit. Some times tongue thrusting develops as a compensatory mechanism for existing openbite. Thus whether chick comes first or egg is a matter of controversy.

### **Skeletal ( fig 2)**

An overgrowth or undergrowth of one or more alveolar segments. In anterior openbites there is undergrowth of the anterior segment with excessive growth posterior alveolar portion.

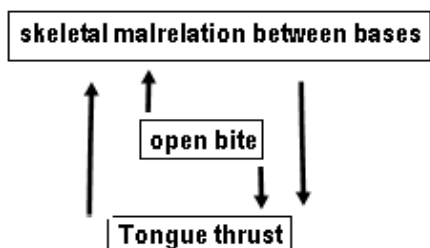
In posterior openbites there is undergrowth of the posterior alveolar segment .

- b) Increased anterior and decreased posterior facial height. The posterior face height (Sella - Gonion) and Anterior face height (Nasion – Menton) are measured on lateral cephalogram with teeth in habitual occlusion to estimate growth directions according to recommendations of JARABAK (1972).

A ratio of less than 62 percent expresses vertical growth pattern and open bite tendency whereas a ratio of more than 65 percent increases the likelihood for horizontal vector and deep bite tendency .

- c) Vertical growth pattern or backward rotation or clock wise rotation of the of the lower jaw
- d) Anticlock wise rotation of the maxillary base.
- e) Divergent jaw bases
- f) Short ramus with long or short body and Increased gonial angle( articulare—gonian – menton )

$$\text{JARABAK RATIO} = \frac{\text{Posterior face height}}{\text{Anterior face height}} \times 100$$



**Dental ( fig 3)**

When there is only dental and dentoalveolar involvement, there is predominance of environmental causes such as thumb or dummy sucking habits, mouth breathing, and tongue or lip thrusting in addition to some local factors such as tooth ankylosis and eruption disturbances that result from over eruption of the posterior teeth or under eruption of the anterior teeth. The periodontal breakdown of anterior teeth may also give rise to anterior openbites with flaring of teeth.

**Classification of anterior open bite**

Anterior open bite can be classified as :

- a. Skeletal anterior open bite

- b. Dental anterior open bite  
These may be unilateral or bilateral

**Features of Openbite**

**Features of skeletal anterior open bite (fig 4 and fig 5)**

The anterior skeletal openbite is called as Apertognathia. The problem is related to the skeletal bases. A patient having a skeletal anterior open bite is characterized by the following

- a. The patient often has a long and narrow face with marked convex profile. The esthetics is impaired. A patient with underlying skeletal class III bases may have concave profile.
- b. The patient may have a short upper lip with excessive maxillary incisor exposure
- c. Increase lower anterior facial height and decreased upper anterior facial height
- d. A steep mandibular plane angle( High angle). Thus the angle FMA is increased and more than 30 degrees. There is clock wise rotation or backward rotation of the mandible with increased lower anterior facial height .
- e. Small mandibular body and ramus
- f. Divergent jaw bases as well as other horizontal cephalometric planes
- g. There is upward rotation of maxillary jaw base ( The ANS and PNS plane gives maxillary jaw base )

**Features of dental anterior open bite (fig 3)**

Dental anterior open bites do not present with the skeletal complications mentioned above. The following are the features of dental open bite:

- a. Proclined upper anterior teeth.
- b. The upper and lower anteriors fail to overlap each other resulting in a mild open bite.
- c. The patient may have a narrow maxillary arch due to lowered tongue posture due to a habit.
- d. There may be spacing between the upper and lower anteriors

**Other features**

Speech defects can be found with lisping of voice. There may be associated upper respiratory infections . Lispisng associated with anterior openbite and spacings is called **interdental stigmatism**.

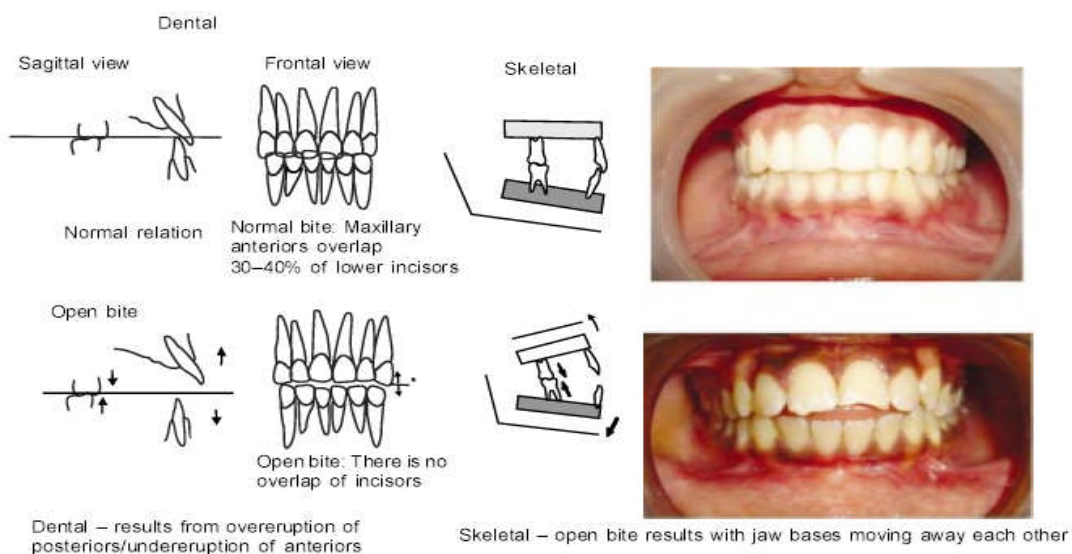


Fig. .1 Normal and openbite

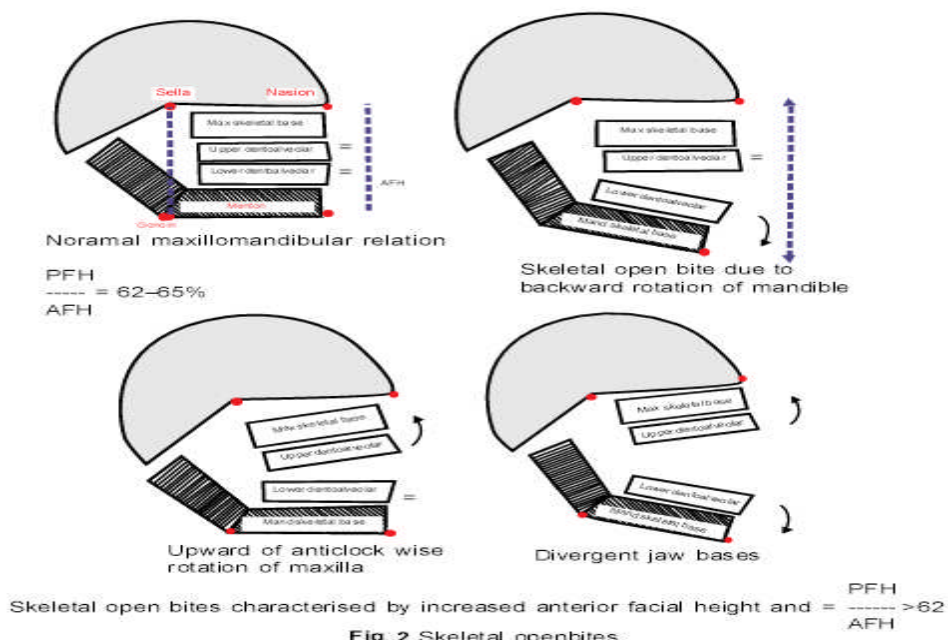
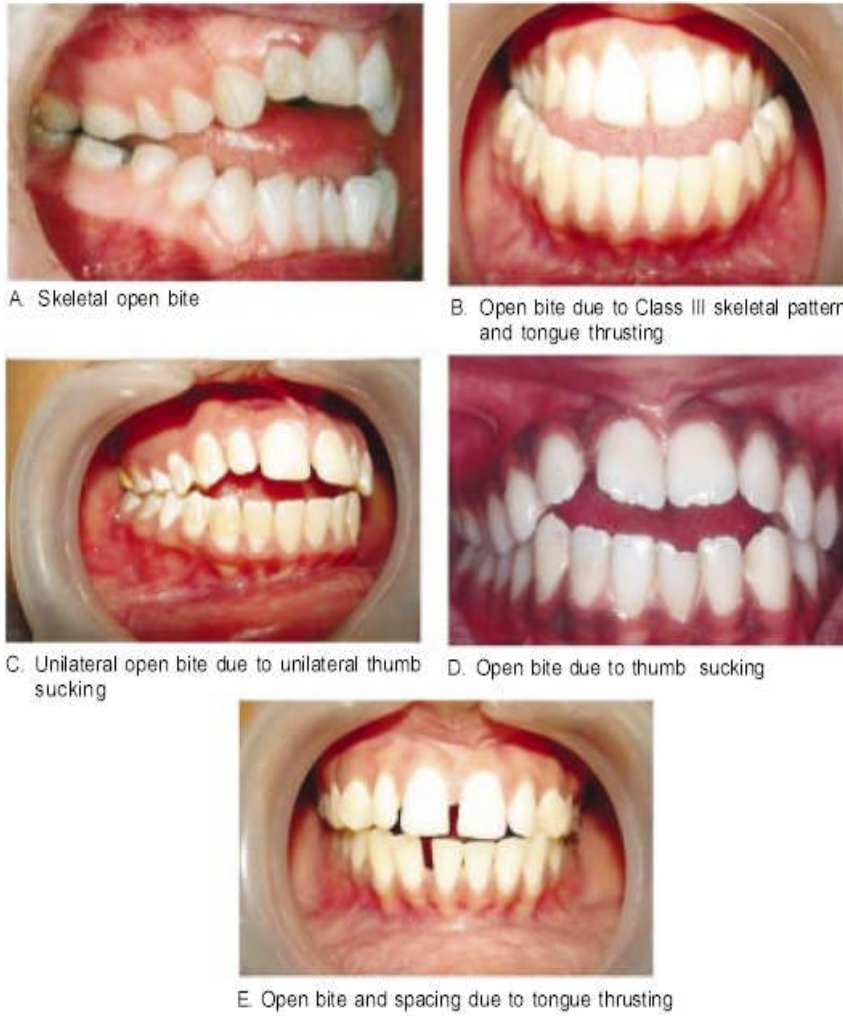
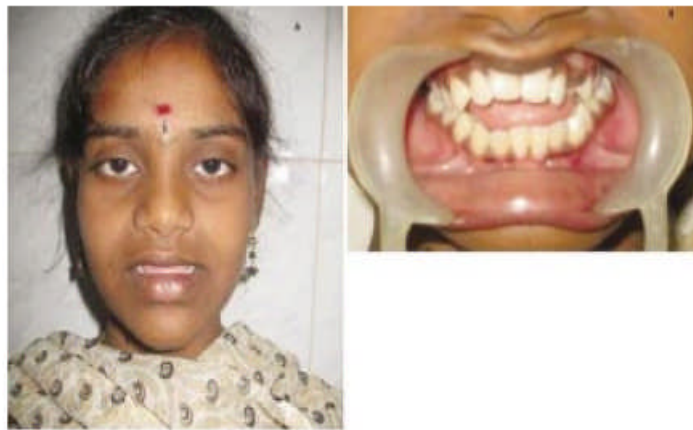
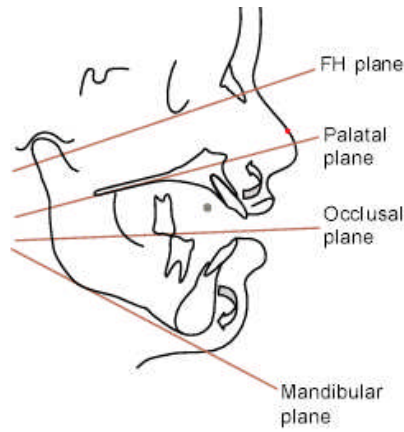
Fig .2 Skeletal openbites



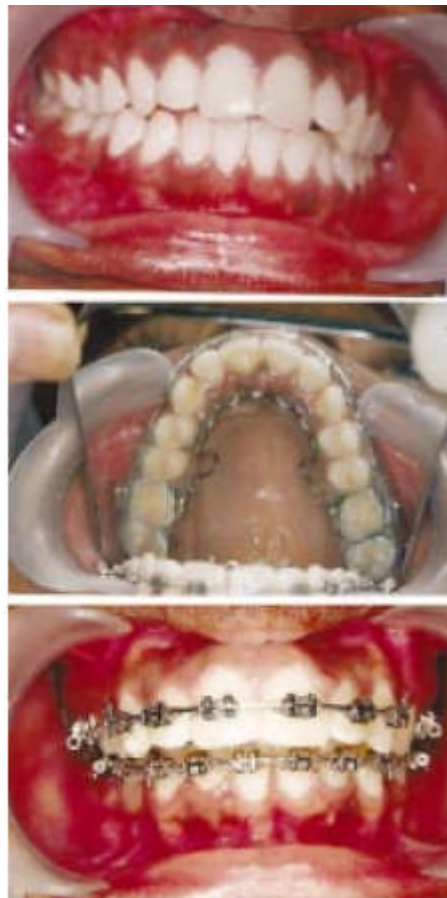**Fig.3** Etiology of open bite



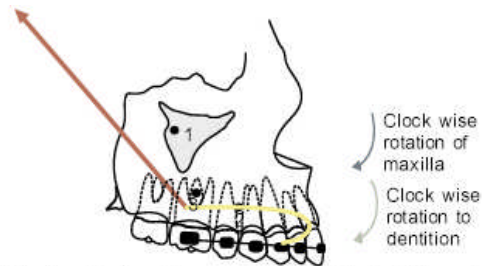
**Fig:4** The patients with skeletal open bites have long and narrow faces. The lower facial height is increased. The mandibular plane angle is also increased. Intraorally there is negative overbite often with narrow maxilla and posterior crossbites.



**Fig. 5** The planes of face are diverging in case of skeletal open bite. Note, this is reverse of skeletal deep bite. The jaw bases are diverging



**Fig. 6** Fixed habit-breaking appliance during fixed appliance therapy



If the line of action of force passes below (behind) the center of resistance of the maxilla as well as maxillary dentition there is clockwise rotation of maxilla as well as dentition and the occlusal plane steepens. Clockwise rotation of maxilla and dentition can help in closing the bite.

Fig.7 Occipital headgear for open bite treatment

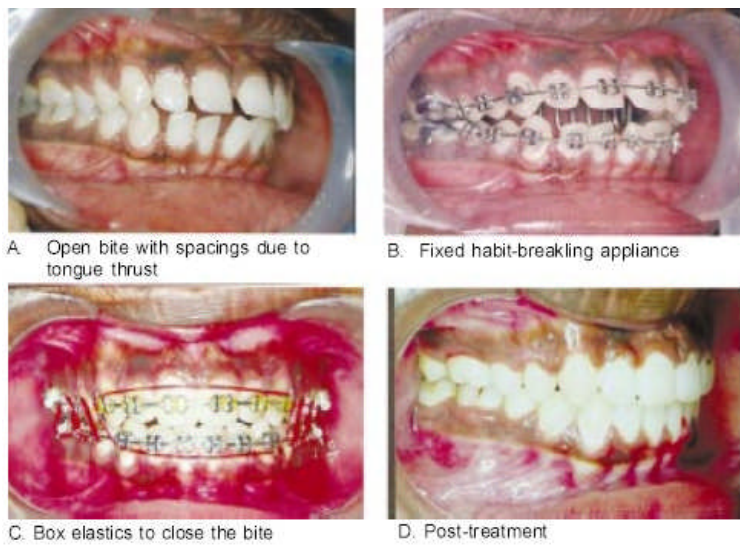


Fig.8 Box elastics

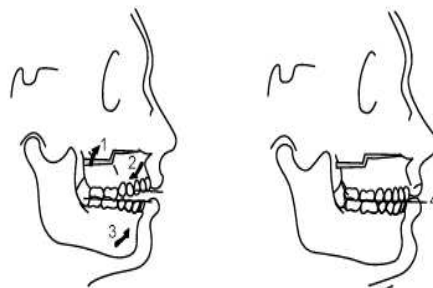
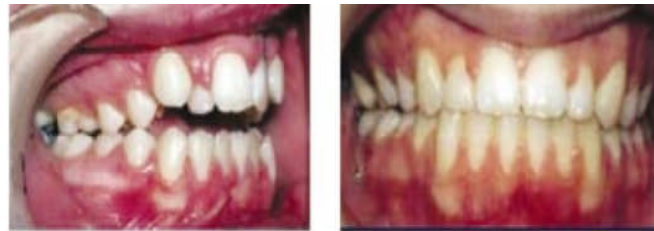

Fig.9 Maxillary impaction. The maxillary can be superiorly repositioned posterior (1). As a result, the maxilla is made to rotate anteriorly downwards (2), the mandible rotates upwards (3) and forwards the open bite is closed (4).

### **Diagnosis**

Diagnosis should include a thorough case history pointing to critical examination towards the presence of any etiological factors like habits. Hereditary content if present should be noted. The cephalometric analysis will differentiate a dental from a skeletal component

### **Treatment of anterior open bite** <sup>8-14</sup>

The diagnosis and treatment of this malocclusion are still controversial. Many authors agree that the clinician should be able to distinguish an open bite of dental and dentoalveolar origin from a skeletal open bite so that treatment is directed towards the cause of the problem. In these patients, dental compensations produced by conventional orthodontic treatment may not lead to satisfactory outcomes

Anterior open bite in the primary dentition is the most frequent malocclusion associated with persistent digit and pacifier sucking

Removal of the etiology ( fig 6 and fig 8): Open bites that have been diagnosed as a result of habits such as thumb sucking or tongue thrusting, require their interception using passive habit breaking appliances. The habit breaker can be either a removable or a fixed type of crib. Persistence of the cause will offer a severe limitation in the corrective procedures. Thus, to allow normal development of the **anterior** dentoalveolar region, the palatal crib may be an excellent treatment option, since it prevents thumb or dummy sucking and avoids tongue thrusting. The appliances used for correction of habits is discussed in detail in chapter on habits.

The presence of abnormal nasopharyngeal pathology should be ruled out after referring the patient to an otolaryngist. The control of those factors should be given due importance before rushing to correct the existing openbite.

### **Myofunctional and orthopedic therapy:** <sup>8,9</sup>

The openbites can be intercepted by growth modulation. The aim is to achieve counterclockwise mandibular rotation for closure of an open bite, especially if there is remaining growth of the mandibular ramus, in order to control the increase in **anterior** face height and achieve improved occlusal outcomes and a balanced profile. Treatment approach is directed at vertical control of facial growth and/or 'real' or relative intrusion of the posterior teeth.

The maxillary posterior segment can be intruded by an occipital headgear which rotates the maxilla in clock wise direction thereby closing the open bite ( fig 7). The

Skeletal anterior open bites can be treated during growth using functional appliances such as F.R-IV or a modified activator. These appliances incorporate bite blocks interposed between the posterior teeth, that have an intrusive action on the upper and lower posterior teeth. Patients exhibiting a downward and backward rotation of the mandible with increased vertical growth, benefit from therapy using a vertical pull head gear with chin cup if treated during the mixed dentition period. Vertical chin cup inhibits the vertical growth in the mandibular posterior dentoalveolar region. It decreases mandibular plane angle and helps in closure of gonial angle indicating **anterior** rotation of the mandible

**Orthodontic corrective therapy** : Mild to moderate dental open bites can be successfully managed using fixed mechanical appliances in conjunction with box elastics. This form of elastic application consists of an elastic that is stretched to extend between the upper and lower anteriors. This brings about extrusion of the upper and lower anteriors. This form of therapy may not give favourable results in severe skeletal open bites. (fig8)

**Surgical correction** : Skeletal open bites in adults are best treated by surgical procedures involving the maxilla and the mandible. This includes step down of maxilla and setup of mandible. The surgical treatment depends upon the other factors like anteriorposterior relationship of maxilla and mandible

**Retention** :- The persistence of the etiological agents is the main cause of relapse in open bite cases. Second factor the continuous growth at the molar region to a little extent and the intrusive effect of etiological factors on the incisors is cited to be another reason for relapse. Use of open bite type of activator or bionator with posterior bite blocks is indicated for long term retention. High pull head gear with standard retainer may also be used but is not practically possible.

## II. POSTERIOR OPEN BITE

Posterior open bite is a condition characterized by lack of contact between the posteriors when the teeth are in centric occlusion. It mostly occurs in a segment of the posterior teeth.

### Causes of posterior open bite

There are two possible causes of posterior open bite:

1. mechanical interference with eruption, either before or after the tooth emerges from the alveolar bone, or
2. failure of the eruptive mechanism of the tooth so that the expected amount of eruption does not occur.

Mechanical interference with eruption may be caused by ankylosis of the tooth to the alveolar bone, which can occur spontaneously or as a result of trauma, or by obstacles in the path of the erupting tooth. Examples of such obstructions prior to emergence are supernumerary teeth and non resorbing deciduous tooth roots or alveolar bone. After the tooth emerges from the bone, pressure from soft tissues interposed between the teeth (cheek, tongue, finger) can be obstacles to eruption. Ankylosed teeth are usually in infraocclusion and are said to be submerged. The most commonly submerged tooth is retained lower deciduous second molar.

The second possible cause of eruption failure is a disturbance of the eruption mechanism itself. These patients have no other recognizable disorder, and no mechanical interferences with eruption seem to exist. The condition may be the cause of posterior open-bite which does not respond to orthodontic treatment.

### Treatment

The primary aim of treatment should be to remove the cause. Lateral tongue spikes are a valuable aid in control of lateral tongue thrust. Once the habit is intercepted, a spontaneous improvement often follows. The posteriors can be forcefully extruded. In cases of posterior open bite due to infra-occlusion of ankylosed teeth, it is best treated by crowns on posteriors to restore normal occlusal level.

### References

1. Almeida RR, Henriques JFC, Almeida MR, Vasconcelos MHF. (1998) Early treatment of **anterior** open bite-prevention of orthognathic surgery. In Davidovitch Z and Mah J (Eds.). Biological mechanisms of tooth eruption, resorption and replacement by

implants(Harvard Society for the Advancement of Orthodontics, Boston) pp. 585–588.

2. Almeida RR and Ursi WJS. (1990) **Anterior** open bite. **Etiology** and treatment. *Oral Health* **80**:27–31. [\[Medline\]](#)
3. Basciftci FA and Karaman AI. (2002) Effects of a modified acrylic bonded rapid maxillary expansion appliance and vertical chin cap on dentofacial structures. *Angle Orthodontist* **72**:61–71. [\[ISI\]](#)[\[Medline\]](#)
4. Cangialosi TJ. (1984) Skeletal morphologic features of **anterior** open bite. *American Journal of Orthodontics* **85**:28–36. [\[CrossRef\]](#)[\[ISI\]](#)[\[Medline\]](#)
5. da Silva Filho OG, Gomes Gonçalves RJ, Maia FA. (1991) Sucking habits: clinical management in dentistry. *Pediatric Dentistry* **15**:137–156.
6. Ngan P and Fields HW. (1997) Open-bite: a review of **etiology** and management. *Pediatric Dentistry* **19**:91–98. [\[Medline\]](#)
7. English JD. (2002) Early treatment of skeletal open bite malocclusions. *American Journal of Orthodontics and Dentofacial Orthopedics* **121**:563–65. [\[CrossRef\]](#)[\[ISI\]](#)[\[Medline\]](#)
8. Gallagher RW, Miranda F, Buschang PH. (1998) Maxillary protraction: treatment and posttreatment effects. *American Journal of Orthodontics and Dentofacial Orthopedics* **113**:612–619. [\[CrossRef\]](#)[\[ISI\]](#)[\[Medline\]](#)
9. Spyropoulos MN. (1985) An early approach for the interception of skeletal open bites: a preliminary report. *Journal of Pedodontics* **9**:200–209.
10. Justus R. (2001) Correction of **anterior** open bite with spurs: long-term stability. *World Journal of Orthodontics* **2**:219–231.
11. Kuhn R. (1968) Control of **anterior** vertical dimension and proper selection of extraoral anchorage. *Angle Orthodontist* **38**:340–349. [\[ISI\]](#)[\[Medline\]](#)
12. Pearson LE. (1991) Treatment of a severe **openbite** excessive vertical pattern with an eclectic non-surgical approach. *Angle Orthodontist* **61**:71–76. [\[ISI\]](#)[\[Medline\]](#)
13. Sankey W, Buschang P, English JD, Owen AH III. (2000) Early treatment of vertical skeletal dysplasia: the hyperdivergent phenotype. *American Journal of Orthodontics and Dentofacial Orthopedics* **118**:317–327. [\[CrossRef\]](#)[\[ISI\]](#)[\[Medline\]](#)
14. Worms FW, Meskin LH, Isaacson RJ. (1971) Open-bite. *American Journal of Orthodontics* **59**:589–595. [\[CrossRef\]](#)[\[ISI\]](#)[\[Medline\]](#)