

UNUSUAL MAXILLARY FIRST MOLAR WITH TWO PALATAL CANALS LOCATED UNDER OPERATING MICROSCOPE

¹Shekhar k ²Radhika

^{1,2} Senior lecturer, Department of Conservative Dentistry and Endodontics, Sri Sai College Of Dental Surgery, Vikarabad, Andhra Pradesh.

ABSTRACT

Knowledge of the anatomical variations, particularly concerning the location and treatment of all canals is very important for the success of the endodontic therapy. Modifications in endodontic access and detection techniques, along with advancements in illumination and magnification technology, have aided in the location and treatment of extra canals in teeth. A case report is presented regarding a maxillary first molar with 5 root canals, two in mesiobuccal root, two in palatal root and one canal in distobuccal root located under Operating Microscope. The morphology is atypical because it is characterized by a single palatal root with 2 canals with separate orifices joining in the apical third. This report serves to remind clinicians that such anatomical variations should be taken into account during endodontic treatment of the maxillary molars.

KEY WORDS: Extra Canals, Atypical, Surgical operating Microscope.

INTRODUCTION

The anatomy of any root canal system has become so uncertain that none can claim maxillary first molar has three roots and three canals. Variations in their morphology have become very common¹. According to Cohen and Burns, canals are often not treated because they are not located.² The clinician must have a thorough understanding of normal anatomy and common variations from the norm. Burns described the maxillary first molar as "...possibly the most treated, least understood, posterior tooth".³

Traditionally, many methods like "champagne or bubble test" with warmed 2.6% NaOCl, staining the chamber with 1% Methylene Blue⁴, the use of sharp explorers, looking for bleeding signs, red line test, white line test and obliquely angled preoperative radiographs are used to locate extra canals.⁵

The enhanced vision systems like surgical headlamps and dental loupes have evolved into the use of the Surgical Operating Microscope (SOM). The SOM provides the clinician with superior lighting and magnification and the ability to treat cases that previously may have been deemed untreatable or resulted in a compromised prognosis.⁶

This case report describes a permanent maxillary first molar with 5 root canals (2 Mesiobuccal(MB), 1 Distobuccal(DB), and 2 Palatal), with unusual palatal canal morphology in that 2 canals with separate orifices joining in the apical third located under Operating Microscope.

Case report

A 35-year-old male patient presented to the hospital with pain in the left upper back teeth since several days. The patient's medical history was noncontributory. Extensive clinical and radiographic examination was done, which revealed # 26(left maxillary first molar) having MesioOcclusal caries involving pulp and showed delayed and lingering response to thermal tests. A diagnosis of irreversible pulpitis was established and Nonsurgical endodontic therapy was initiated. The patient received local anesthesia of 2% Lidocaine with 1:100,000 Epinephrine. A rubber dam was placed, and endodontic access opening was made. Three principal root canal systems were identified, Mesiobuccal, Distobuccal and Palatal.

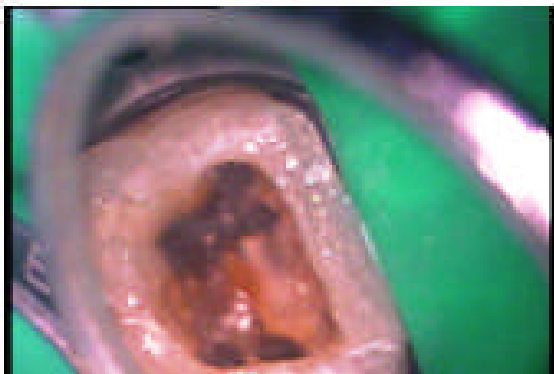


Fig.1. MB1,MB2, DB, P1, P2 orifices can be seen



Fig.2.Two palatal canals joining at the apical third

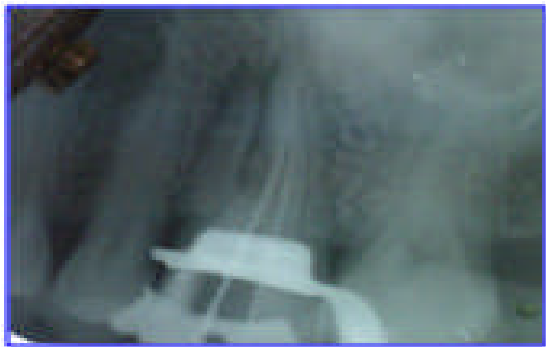

Fig.3. Working length radiograph with instruments in five canals

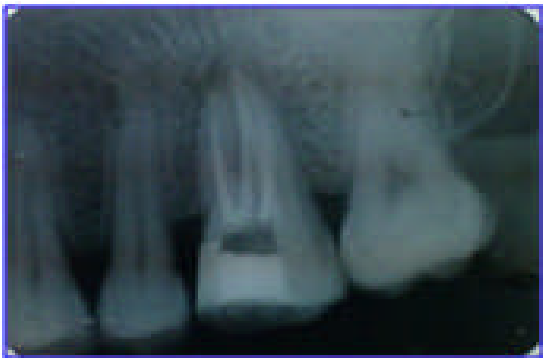

Fig.4. Immediate post operative radiograph

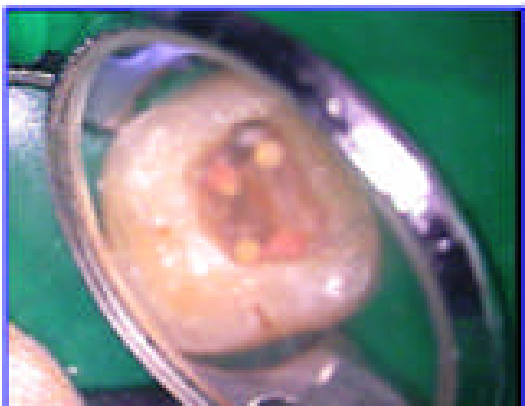

Fig.5.: All the 5 canals are obturated

The pulp chamber floor was then observed under Surgical Operating Microscope. Examination of the chamber floor with the explorer revealed 5 canal orifices (**Fig.1**). The palatal and mesial roots had 2 orifices, fairly well separated, exiting from the floor of the pulp chamber. Working length was determined (**Fig.2, Fig.3**). Gates Glidden drills #1, #2 and #3 were used to flare the coronal portion of the canals to improve straight-line access. Frequent irrigation with 2ml of 3% Sodium Hypochlorite was also carried out. All the canals are prepared with Protaper rotary instruments. The tooth was dried with paper points, and a cotton pellet with Intra canal medicament was sealed into the pulp chamber with a temporary restorative filling material.

At the next appointment, the root canals were irrigated with 3% Sodium Hypochlorite and dried with paper points. The canals were obturated using Zinc Oxide-Eugenol sealer and Protaper gutta-percha. (**Fig.4, Fig.5**) A temporary restoration was placed and a postoperative radiograph was taken. The immediate post-treatment radiograph shows the unique palatal morphology. The tooth has been asymptomatic thereafter.

Discussion

The goal of root canal treatment is to clean the root canal system thoroughly and to fill it in all dimensions. Canals often left untreated because the dentist fails to recognize its presence. Thus, it is necessary for the clinician to have knowledge of dental anatomy and its variations. Slowey stated that root canal anatomy of each tooth has certain commonly occurring characteristics as well as numerous atypical ones that can be road maps to successful endodontics⁷.

SOM has been advocated in all phases of endodontics, including location of hidden, calcified canals and it gives intimate detail of an area that otherwise would be under-illuminated and under-magnified, requiring guesswork and great caution.⁶ Kulild and Peters found that incidence of MB2 has increased to 95.2 % when Operating microscope was used.⁸ According to Burhley et al, use of magnification increased MB2 detection rate by three times that of the non magnification group.⁹ If

we compare these results with previous studies published only 5 or 10 years ago, we can conclude that the increased percentage is not due to differences in root canal anatomy but to the better skills of the clinician who uses the Operating Microscope⁶.

The form, configuration, and number of root canals in maxillary first molars have been discussed for more than half a century¹⁰. There are references to teeth with four to six canals. In the mesiobuccal and in the palatal roots, the number of canals can vary between one and three.¹¹ Among the root canal anomalies of maxillary molars, the least frequent variation appears to be that of the palatal root.

Literature was reviewed regarding the presence of extra canals in palatal root of maxillary molars. Harris documented a case where the palatal root of a maxillary first molar had 2 separate root canals.¹² Cecic and others reported a case with 5 canals (2 MB, 1 DB, and 2 palatal), in which the palatal canals bifurcated at mid root into 2 distinct canals.¹¹ Bond and others also presented a 6-canal first molar (2 MB, 2 DB, and 2 palatal)¹³. The incidence of two root canals in the palatal root of maxillary molars has been reported to be 2- 5.1%¹⁴, Christie et al speculated that maxillary molars with two palatal roots may be encountered once every 3 years in a busy endodontic practice.¹⁵ Although the incidence of a second palatal canal is not high, it is important to take this variation into consideration during root canal therapy of maxillary molars in order to ensure long term treatment success.

CONCLUSION

This case report contributes to our understanding of the complexity of the root canal morphology found in maxillary first molars. Although such cases occur infrequently, dentists should be aware of them when considering endodontic treatment of a maxillary first molar. Increased percentage of detection of extra canals is not due to differences in root canal anatomy but due to the better skills of the clinician who uses the Operating Microscope.

References

1. Bharghavi N, Velmurugan N, Kandaswamy D. The hunt for elusive canals. Endodontology 2005; 17 :18-23
2. Cohen S, Burns RC. Pathways of the pulp. 7th ed. St Louis, Missouri: CV Mosby 1998:805.
3. Burns RC. Access openings and tooth morphology. In: Cohen S, Burns RC, (eds). Pathways of the pulp (4th edn) St. Louis, MO: The CV Mosby Co; 1987: 120-121.
4. Stropko J, Canal morphology of maxillary molars: Clinical observations of canal configurations, J Endod 1999; 25(6): 446-50 [doi:10.1016/S0099-2399\(99\)80276-3](https://doi.org/10.1016/S0099-2399(99)80276-3)
5. Ingle J, Bakland L K. Endodontics. 5th ed. Canada, Elsevier: BC Decker, 2002:405.
6. Carr GB., Microscopes in endodontics. J Calif Dent Assoc 1992; 20: 55-61. PMID:1284396
7. Slowey RR, Root canal anatomy, Road map to successful endodontics. Dent. Clin. North Am. 1979; 23:555 PMID:294389
8. Kulild JC, Peters DO. Incidence and configuration of canal systems in the mesiobuccal root of maxillary first and second molars. J Endod. 1990; 16: 311-7 [doi:10.1016/S0099-2399\(06\)81940-0](https://doi.org/10.1016/S0099-2399(06)81940-0)
9. Buhrley LJ, Effect of Magnification on Locating the MB2 Canal in Maxillary Molars, J Endod 2002; 28(4), 324-7. [doi:10.1097/00004770-200204000-00016](https://doi.org/10.1097/00004770-200204000-00016) PMID:12043874
10. Stephen JI, DMD, Unusual Maxillary First Molar with 2 Palatal Canals Within a Single Root: A Case Report J Can Dent Assoc 2001; 67: 211-4
11. Cecic P, Hartwell G, Bellizzi R. The multiple root canal system in the maxillary first molar: a case report. J Endod 1982; 8: 113-18. [doi:10.1016/S0099-2399\(82\)80245-8](https://doi.org/10.1016/S0099-2399(82)80245-8)
12. Harris WE. Unusual root canal anatomy in a maxillary molar. J Endod 1980; 6(5): 573-5. [doi:10.1016/S0099-2399\(80\)80154-3](https://doi.org/10.1016/S0099-2399(80)80154-3)
13. Bond JL, Hartwell G, Portell FR. Maxillary first molar with six canals. J Endod 1988; 14(5): 258-60 [doi:10.1016/S0099-2399\(88\)80180-8](https://doi.org/10.1016/S0099-2399(88)80180-8)
14. Stone HL and Stroner FW. Maxillary molars demonstrating more than one palatal root canal. Oral Surg. 1981; 51(6) : 649-652 [doi:10.1016/S0030-4220\(81\)80017-5](https://doi.org/10.1016/S0030-4220(81)80017-5)
15. Christie WH, Peikoff MD and Fogel HM. Maxillary molars with two palatal roots: A retrospective clinical study J. Endod 1991; 17(2): 80-84. [doi:10.1016/S0099-2399\(06\)81613-4](https://doi.org/10.1016/S0099-2399(06)81613-4)

Corresponding Author

Dr. Shekar .K

Senior Lecturer

Department of Conservative and
EndodonticsSri Sai College of Dental Surgery
Vikarabad

Ph.No.: 9985825481

E-Mail: drsushma79@yahoo.com

drshekarmds@gmail.com