

UNUSUAL CANAL MORPHOLOGY IN MANDIBULAR SECOND MOLAR- A CASE REPORT

¹ Vijay Reddy V¹ Associate Professor² Sridhar M² Reader³ Satish SV³ professor⁴ krishnarao k⁴ Reader

^{1,2} Department of Conservative Dentistry and Endodontics, Hi-Tech Dental College and Hospital, Bhubneswar, orissa.

^{3,4} Department of Conservative Dentistry and Endodontics, Navodaya dental college and Hospital, Raichur, Karnataka.

ABSTRACT:

A case of unusual root morphology is presented to demonstrate anatomic variations in mandibular second molars. The most common configuration of mandibular second molar is to have two roots with three root canals; however mandibular molars may have many different combinations. Endodontic therapy was performed in a mandibular second molar with three separate roots one located mesially and two distally. Radiographically all 3 root canals terminated with individual foramina. Three orifices or 3 independent canals were found in the three separate roots, indicating a rare anatomic configuration. Looking for additional roots, canals and unusual morphology is an important part of successful endodontics, as the knowledge of their existence occasionally enable clinicians to treat a case that otherwise might have ended in failure.

KEYWORDS: Anatomy, Mandibular Second molar.

INTRODUCTION

The abnormalities of the mandibular second molar are often not fully taken into account when root canal therapy is being considered. Usually, non-surgical root canal therapy is thought of as a routine endodontic procedure. On first glance at a radiograph of a mandibular second molar, the tooth often appears normal in morphology. However, when the procedure begins, very often the practitioner then realizes the extent of the difficulties that he or she may have to overcome.¹

The mandibular second molar is typically compared to the first mandibular molar. The differences are instructive. First, they are smaller coronally than the first mandibular molar. Second, they are more symmetrical than the first molar. C-shaped root system is an anatomical variation of second molars.² They can be seen with a fin or web connecting the root systems. Lateral canals, anastomoses and apical deltas are very common. Furthermore, the second molar's roots have a tendency to be close together and may be fused-single rooted- (22%) and may have 3 roots also (2%),^{3,4} Unlike first molars wherein a second canal is found in the distal root (30-35%) of the time, this tooth exhibits two canals in the distal root in only about 3% of cases. (HARTWELL G). The mesial root usually has 2 canals in 87% of cases and only one canal in only about 13% of cases. and with 1 orifice, 1

canal and 1 foramen is a very rare entity. (INGLE)⁵⁻¹⁰

Achieving a successful result in root canal therapy on second molars presents a challenge to all clinicians. This report describes endodontic therapy on a 3 rooted mandibular second molar with single mesial canal in the mesial root and two separate distal canals (DB, DL) with separate roots and separate foramen. The access cavity is same trapezoidal in outline but reverse (i.e. base towards distal and apex towards mesial side)

Case report

A 25 yr old young man sought treatment for pain in right mandibular second molar region since 2 months. Clinical examination revealed large carious lesion concentrated occluso-buccally involving the pulp is present.

The tooth was sensitive to percussion and there was no response to thermal tests. Radiograph revealed widening of periodontal (PDL) space. Radiograph also revealed a large and long dumbbell shaped mesial root and two distinct distal roots (double PDL spaces in distal root) (**Fig 1**). Based on subjective and objective findings a diagnosis of irreversible pulpitis with apical periodontitis was made and root canal treatment was indicated.

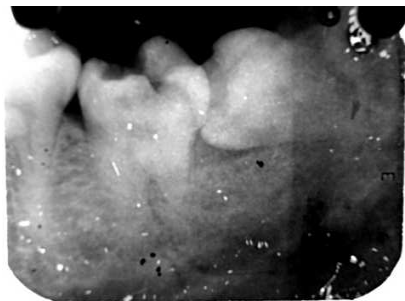


Fig.1. Radiograph showing the double PDL spaces in the distal root

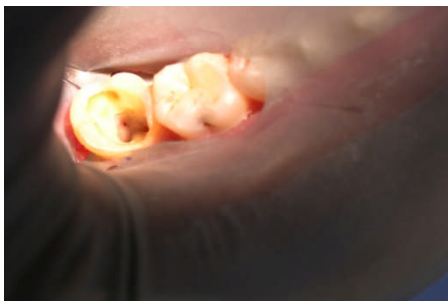

Fig.2. Photograph showing the presence of extra distal orifice

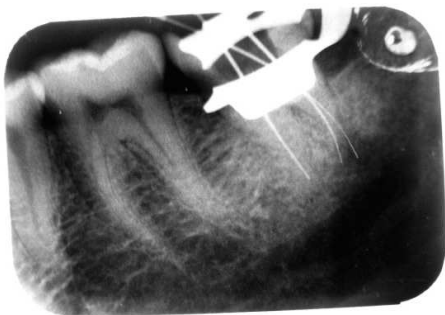

Fig.3. Radiographic confirmation of extracanal and foramen in the extra distal orifice

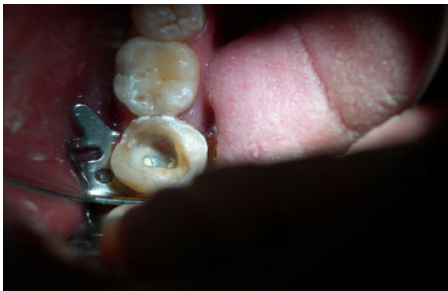

Fig. 4. Photographs after enlarging the canals

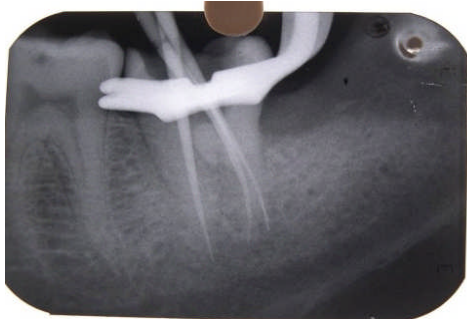

Fig.5. Check X-rays with master cones in the canals

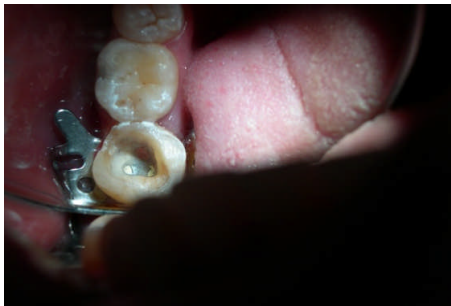

Fig.6. Photographs after obturation.

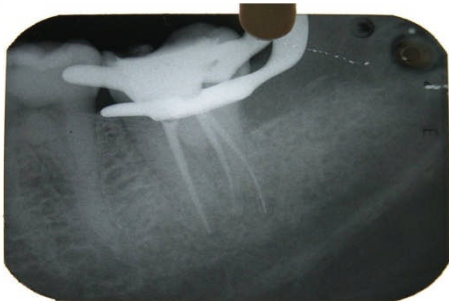


Fig.7. Radiographs after obturation

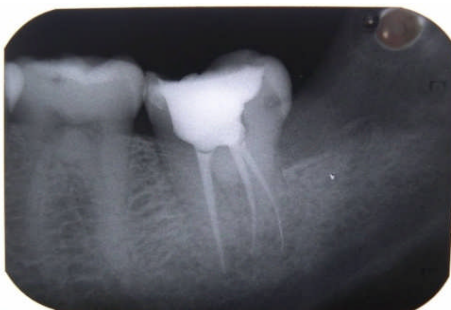

Fig.8. Follow up radiograph.

Tooth was isolated with rubber dam and access gained to pulp chamber. The coronal necrotic pulp tissue was removed (pulp extirpation) and chamber irrigated with 5.25% NaOCl and normal saline. Observation via a conventional access cavity (more mesially and buccally) and trapezoidal in outline revealed a large mesial orifice (present at the center of mesial surface) and small distal orifice (present more buccally) at the floor of pulp chamber. (Fig .2). The access cavity was enlarged by means of fissure bur at high speed and whole of the pulp chamber was deroofed. Coronal flaring done with the same bur.

Exploring the fissure along the distal end of access cavity with a sharp endodontic explorer, a "stick" was encountered. Careful investigation of pulp chamber with K-file and EDTA revealed another distal orifice (DL) with 1 canal and 1 apical foramen which was then confirmed by radiographs. (Fig .2 and Fig. 3)

Working lengths were estimated using an apex locator (Root ZX, MORITA, JAPAN) and then confirmed by radiographs. Cleaning and shaping was done using Protaper Rotary (0.006 taper). The mesial canal was enlarged up to #25(F2) where as the distal canals were enlarged to #20(F1) (Fig.4). After BMP, in the third visit canals were thoroughly irrigated with normal saline and then dried with paper points, Master cone radiograph taken (Fig 5) and obturation done with Protaper Monocone GP with AH plus sealer. (Fig. 6 and Fig. 7)

At follow up after 15 days, pt was asymptomatic and radiograph revealed normal periapical tissue. Patient advised for a full ceramic crown to prevent further fracture of crown (Fig .8)

Discussion

Anatomical variations are an acknowledged characteristic of mandibular permanent molars. Most mandibular first and second molars in Caucasians have 2 roots, with 2 mesial canals and 1 distal canal.^{11,12} The presence of a third root in the permanent first molar is the major variant in this group. The frequency of this trait is less than 5% in Caucasian, African, Eurasian and Indian populations, whereas it occurs in 5% to more than 40% of people of Mongolian origin¹³

Gulabivala and others recently reported that 13% of mandibular first molars in people of Thai origin had a third distolingual root.¹⁴ The additional root is generally located on the lingual aspect and has a Vertucci type I canal configuration. Such a variant has not been reported for the mandibular second molar, but it is found (rarely) in the mandibular third molar.^{15]}

This report highlights the unusual anatomy of mandibular second molar occurring bilaterally in the same

patient. Most Endodontic and dental anatomy textbooks describes the mandibular second molar as having 2 roots (1 mesial, 1 distal) with 2 or 3 canals (2 mesial and 1 distal or 1 mesial and 1 distal).⁵⁻¹⁰ The reported percentage of 3 rooted mandibular molars is <2%.¹⁶ The review and radiograph survey of Weine, pasiewicz, Rice has found only 4% exhibiting this condition (i.e. 1 large mesial canal).³ All the canals have Vertucci type 1 canal configuration i.e. (1 canal and 1 foramen). Therefore the combination of 1 large mesial root canal in large mesial root and 2 small distal canals in 2 separate distal roots is still more a rare entity. This gives an unusual access opening to the tooth which corresponds to unusual pulp anatomy and canal morphology of the tooth. (Trapezoidal in outline-apex towards mesial and base towards distal side)

The presence of extra roots is readily determined using routine radiograph, as was demonstrated in the current case. However, teeth with extra canals and a normal of roots presence a greater challenge in terms of diagnosis and treatment. Extra root canals may be difficult to identify because of their superimposition over other root canals or, sometimes, their relatively small size. Careful examination of the preoperative radiograph will aid in the detection of extra canals.¹⁷

Spiral CT imaging is a useful technique to provide detailed information about the morphology of the teeth.^{18.} Knowledge of anatomic aberrations, such as root position, shape and relative root outline will also help decrease the failure rate of root canal therapy.¹⁹

CONCLUSION

Anatomic variation in the number of roots and root canals can occur in any tooth. Mesial and/or distal radiographic projections can give more information on morphological features and the relationship between the canals, making the interpretation of structures easier.^[20] Knowledge of both normal and abnormal anatomy of the molars dictates the parameters for execution of the root canal therapy and can directly affect the probability of success.^{4,21}

Despite the facts that surgical therapy may be necessary in some cases, a thorough knowledge of the complexity of root canal morphology in addition to adequate operative procedures appear to be the main requirements for successful endodontic treatments of these dental abnormalities.

References

1. Maggiore C, Gallottini L, Resi JP. Mandibular first and second molar. The variability of roots and root canal system. Minerva Stomatol 1998;47:409-16 PMid:9835748

2. Fan B, Cheung GS, Fan M, Gutmann JL, Fan W. C-shaped canal system in mandibular second molars: Part II- Radiographic features. J Endod 2004;30:904-908. PMid:15564875 [doi:10.1097/01.don.0000136206.73115.93](https://doi.org/10.1097/01.don.0000136206.73115.93)
3. Weine FS, Pasiewicz RA, Rice RT : Canal configuration of the mandibular second molar using a clinically oriented in vitro method. J Endod 1988; 14 : 207-213. [doi:10.1016/S0099-2399\(88\)80171-7](https://doi.org/10.1016/S0099-2399(88)80171-7)
4. Manning, S. A. (1990), Root canal anatomy of mandibular second molars. Part I. International Endodontic Journal, 23: 34-39. [doi:10.1111/j.1365-2591.1990.tb00800.x](https://doi.org/10.1111/j.1365-2591.1990.tb00800.x) PMid:2391179
5. Walton RE, Vertucci FJ: Internal anatomy. In: Walton RE, Torabinejad M: Principles and Practice of Endodontics, 2nd Edition. Philadelphia, PA, USA: W.B. Saunders Co., 1996: pp. 166-79.
6. Wheeler, RC. Pulp Cavities of the Permanent Teeth. An Anatomical Guide to Manipulative Endodontics. Philadelphia, PA, USA. W.B. Saunders Co. 1976: 126-66.
7. Ingle J, Bakland L: Endodontics. 5th ed. Philadelphia: Lea and Febiger; 2002;558.
8. Cohen S, Burns RC. Pathways of the Pulp. 8th ed. St Louis: Mosby; 2002:196-229.
9. Weine FS: Endodontic Therapy, 4th Edition. Saint Louis, MO, USA: Mosby, 1989: pp. 225-69.
10. Frank J. Vertucci. Root canal morphology and its relationship to various endodontic procedures. Endodontic topics 2005; 10: 3-29. [doi:10.1111/j.1601-1546.2005.00129.x](https://doi.org/10.1111/j.1601-1546.2005.00129.x)
11. Vertucci FJ. Root canal anatomy of the human permanent teeth. Oral Surg Oral Med Oral Pathol 1984;58: 589-99 [doi:10.1016/0030-4220\(84\)90085-9](https://doi.org/10.1016/0030-4220(84)90085-9)
12. Barker BC, Parson KC, Mills PR, Williams GL. Anatomy of root canals. III. Permanent mandibular molars. Aust Dent J 1974;19:403-13.
13. Gulabivala K, Aung TH, Alavi A, Ng Y-L (2001) Root canal anatomy of Burmese mandibular molars. International Endodontic Journal 34, 359-70. PMid:11482719 [doi:10.1046/j.1365-2591.2001.00399.x](https://doi.org/10.1046/j.1365-2591.2001.00399.x)
14. Gulabivala K; Opananon A; Ng Y L; Alavi A Root canal morphology of Thai mandibular molars. International endodontic journal 2002;35(1):56-62 [doi:10.1046/j.1365-2591.2002.00452.x](https://doi.org/10.1046/j.1365-2591.2002.00452.x) PMid:11853239
15. Sperber GH, Moreau JL. Study of the number of roots and canals in Senegalese first permanent mandibular molars. Int Endod J 1998;31(2):117-22. [doi:10.1046/j.1365-2591.1998.00126.x](https://doi.org/10.1046/j.1365-2591.1998.00126.x)
16. Wells DW, Bernier WE. A single mesial canal and two distal canals in a mandibular second molar. J Endod 1984;10:400-3. [doi:10.1016/S0099-2399\(84\)80163-6](https://doi.org/10.1016/S0099-2399(84)80163-6)
17. Skidmore AE. The importance of preoperative radiographs and the determination of root canal configuration. Quintessence Int Dent Dig 1979;10:55-61.
18. Jayasinghe RD, TK Li. Three-rooted first permanent mandibular molars in a Hong Kong Chinese population: a computed tomographic study. Hong Kong Dent J 2007;4:90-3
19. Rocha LF, Sousa Neto MD, Fidel SR, da Costa WF, Pécora JD. External and internal anatomy of mandibular molars. Braz Dent J 1996;7:33-40 PMid:9206352
20. Fava LR, Dummer PM. Periapical radiographic techniques during endodontic diagnosis and treatment. Int Endod J 1997;30:250-61 [doi:10.1111/j.1365-2591.1997.tb00705.x](https://doi.org/10.1111/j.1365-2591.1997.tb00705.x) PMid:9477811
21. Fan, B., Min, Y., Lu, G., Yang, J., Cheung, G. P., and Gutmann, J. Negotiation of C-Shaped Canal Systems in Mandibular Second Molars. Journal of Endodontics 2009, 35(7), 1003-1008. [doi:10.1016/j.joen.2009.04.011](https://doi.org/10.1016/j.joen.2009.04.011) PMid:19567323

Corresponding Author

Dr. Vijay Reddy Venumuddala

Associate Professor

Department of Conservative Dentistry and Endodontics

Hitec Dental College and

Hospital, Bhubaneswar

Ph.No.: 91-9000199225

E-Mail: vijdent@yahoo.com