

1. TONGUE THRUST HABIT - A review.

*Gowri sankar singaraju

**Chetan kumar

*Professor, Department of orthodontics, St. Joseph Dental College, Eluru.

**Senior Lecturer, Department of Orthodontics, St. Joseph Dental College, Eluru.

Abstract:

There is interrelation ship between the form and function. The different abnormal habits may effect the form of orofacial structures. The presence of one oral habit may induce the other. In this review article a new induction chart is prepared to show the interrelation between different abnormal habits and their effect on form. The chart also in turn explains how form can lead to development of different habits. Thus there is interrelation ship between form and function.

Key words: form and function, etiology, tongue thrust habit, induction chart.

Tongue thrust is a defined as a condition in which the tongue makes contact with any teeth anterior to the molars during swallowing.

Tulley¹ 1969 - states tongue thrust as the forward movement of the tongue tip between the teeth to meet the lower lip during deglutition and in sounds of speech, so that the tongue becomes interdental.

Tongue thrust is an oral habit pattern related to the persistence of an infantile swallow pattern during childhood and adolescence and thereby produces an open bite and protrusion of the anterior tooth segments

Types of tongue thrust^{2,3}

1. **Physiologic** This comprises of the normal tongue thrust swallow of infancy
2. **Habitual** The tongue thrust swallow is present as a habit even after the correction of the malocclusion.
3. **Functional** When the tongue thrust mechanism is an adaptive behaviour developed to achieve an oral seal, it can be grouped as functional.
4. **Anatomic** Persons having enlarged tongue can have an anterior tongue posture.

Etiology⁴⁻¹⁶

Fletcher has proposed the following factors as being the cause for tongue thrusting.

a. Genetic or heredity factor : They are specific anatomic or neuromuscular variations in the orofacial region that can precipitate tongue thrust. E.g. hypertonic orbicularis oris activity.

b. Learned behavior (habit) : Tongue thrust can be acquired as a habit. The following are some of the predisposing factors that can lead to tongue thrusting ;

1. Improper bottle feeding
2. Prolonged thumb sucking
3. Prolonged tonsillar and upper respiratory tract infections.

4. Prolonged duration of tenderness of gum or teeth can result in a change in swallowing pattern to avoid pressure on the tender zone

Upper respiratory tract infections Upper respiratory tract infections such as mouth breathing, chronic tonsillitis, allergies, push the tongue forward due to pain and decrease in the amount of space which brings about a tongue thrust swallow. It may also be present due to the physiological need to maintain an adequate airway.

Feeding practices Prolonged bottle feeding and improper swallowing pattern has been attributed as one of the etiological factors of tongue thrusting.

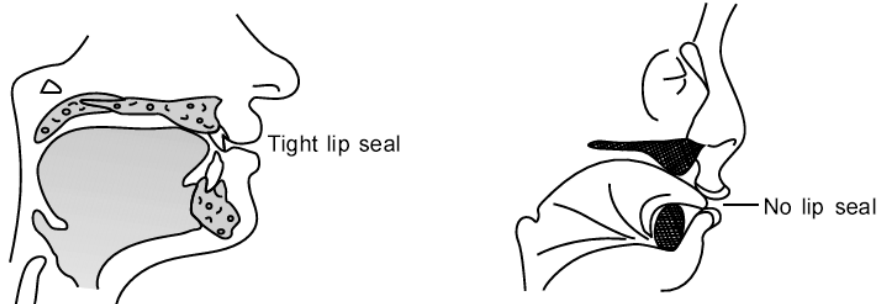
Maturational

- i. **Retained infantile swallow** There is a considerable amount of evidence which suggests that tongue thrust is merely a retention of the infantile suckling mechanism. The infantile swallow changes to a mature swallow once the posterior deciduous teeth start erupting. Sometimes the maturation is delayed and thus infantile swallow persists for a longer duration of time. The tongue thrust resulting from the retained infantile swallow has poorest prognosis(Fig I)

Functional adaptability: The tongue can protrude when the incisors are missing. Following the loss of deciduous teeth and prior to full eruption of the permanent incisors, there exists a natural opening for the tongue. The tip of the tongue may protrude into the open area during swallowing. This may disappear with the eruption of permanent central incisors. The same may happen in the posterior region during transition of deciduous to permanent dentition

a. Mechanical restrictions : The presence of certain conditions such as macroglossia, constricted dental arches and enlarged adenoids predispose to tongue thrust habit (Fig2)

b. Neurological disturbances affecting the oro-facial region such as Hyposensitive palate, moderate motor disability, disruption of sensory control and coordination of swallowing can lead to tongue thrust.



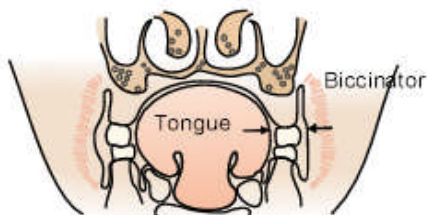
Mature adult swallow: The tongue touches the anterior palate. The lips contact tightly, forming "lipseal" creating negative pressure inside the oral cavity. The mandible is stabilised by muscles of mastication.

Infantile swallow: The tongue protrudes in between gumpads and contacts the lips. The lips are apart. The mandible is balanced by muscles of facial expression. This type of swallow matures once the teeth erupt and come into contact and when child starts taking solid food

Fig.1 Etiology of tongue thrust – retained infantile swallow



(A) Sagittal view. Under normal conditions the air is breathed through the nose and very little, if any, passes through the oral cavity and there is tight lip seal



(B) Coronal view. Under normal conditions the tongue is high up in the palatal vault. This neutralizes the buccinator mechanism and the teeth are held in neutral zone between the tongue and cheeks. The teeth are thus stable

Fig. 2 Normal respiratory function through the nose

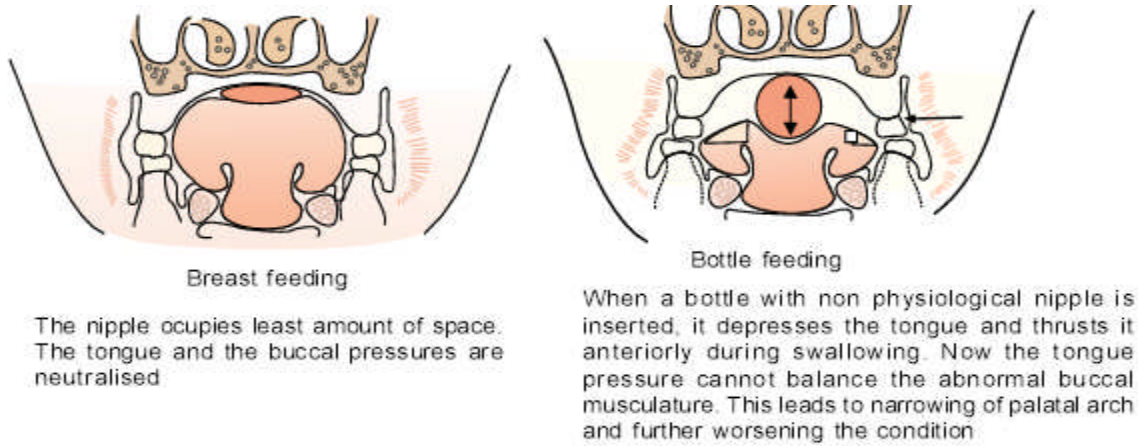
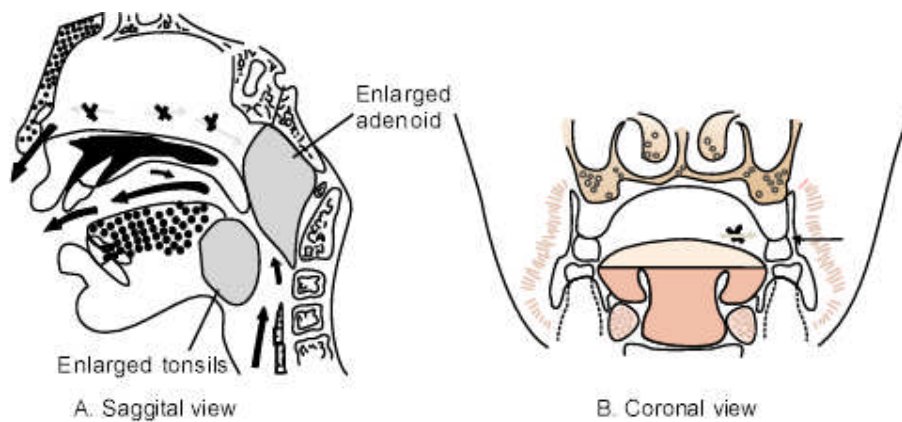


Fig. 3:



- Mouth breathing may develop due to nasal septal blockade or enlargement of adenoids and tonsils. The patients is forced to breathe through the mouth. to prevent irritation from the enlarged adenoids and tonsils the longue acquires a anterior and inferior position. This position allows the easy exchange of air through oral cavity.
- A. The anteriorly protruding tongue push the upper and lower teeth labially thereby the overjet as well as spacing between the upper and lower anterior teeth. The mandible rotates backwards and downwards to allow the new tongue position. As a result the lower facial height increases
 - B. The tongue lies low and is contained with in the mandible. The buccinator action is un opposed by the tongue and hence palatal constricts thereby leading to posterior cross bites

Fig. 4 Consequences of mouth breathing

Tongue thrust can also be classified as simple tongue thrust and complex tongue thrust.

1. SIMPLE TONGUE THRUST: (Anterior tongue thrusting)

It is defined as tongue thrust with a teeth together swallow. It is usually associated with the history of digit sucking. The features observed depends upon the duration, intensity and frequency of the habit. Some of the features are common to thumb sucking and mouth breathing also.

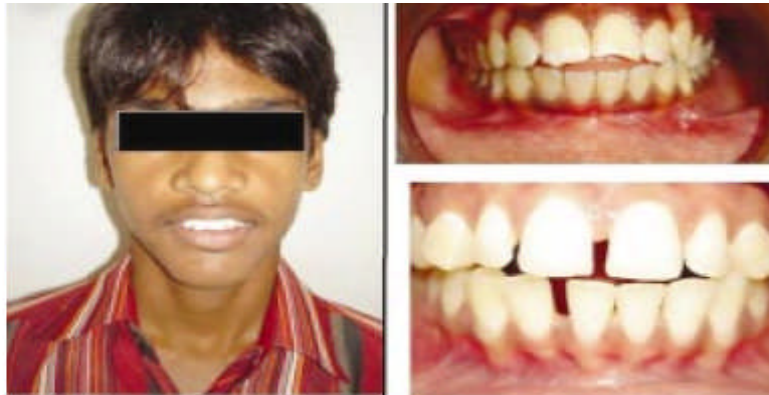

Fig. 5 Features of anterior tongue thrust. Dolichocephalic face, incompetent lips and hyperactive mentalis; B, Anterior open bite– Simple anterior tongue thrust, C Spacings of U/L arch by tongue thrusting

Extra oral features (Fig 5)

1. Usually dolichocephalic face.
 2. Increased lower anterior facial height
 3. Incompetent lips
 4. Expression less face as the mandible is stabilized by facial muscles instead of masticatory muscles during deglutition.
- Speech problems like sibilant distortions and lispings etc.. Abnormal mentalis muscle activity is seen

Intra oral features

1. Proclined, spaced and some times flared upper anteriors resulting in increased overjet.
2. Retroclined or proclined lower anteriors depending upon the type of tongue thrust.
3. Presence of an anterior open bite.
4. Presence of posterior crossbites.
5. The simple tongue thrust is characterized by a normal tooth contact during the swallowing act. They exhibit good intercuspation of posterior teeth in contrast to complex tongue thrust.
6. The tongue is thrust forward during swallowing to help establish an anterior lip seal. At rest the tongue tip lies at a lower level.

2. COMPLEX TONGUE THRUST: (ANTERIOR AND POSTERIOR TONGUE THRUST)(FIG 7)⁶⁻¹⁰

It is defined as tongue thrust with a teeth apart swallow. It is usually associated with chronic nasorespiratory distress, mouth breathing, tonsillitis, and pharyngitis.

Etiology

Pain and lessening of space in the throat precipitate a new forward tongue posture and swallowing reflex. Because maintenance of airway patency is a more primitive and demanding reflex than the mature swallow, the later is conditioned to the necessity for mouth breathing. The jaws are thus

held apart during swallow in order that the tongue can remain in a protruded position

Features

The following features are seen :

1. Proclination of anterior teeth
2. Bimaxillary protrusion
3. This kind of tongue thrust is characterized by a teeth apart swallow.
4. The anterior open bite can be diffuse or absent.
5. Absence of temporal muscle constriction during swallowing.
6. Patients with a complex tongue thrust combine contractions of the lip, facial and mentalis muscle.
7. The occlusion of teeth may be poor. Poor occlusal fit, no firm intercuspation.
8. Posterior open bite in case of lateral tongue thrust
9. Posterior crossbite

Simple	Complex
1. Open bite is well defined with definite beginning and ending.	1. Open bite is diffuse, ill defined.
2. Mandible is stabilized by muscles of mastication	2. Mandible is stabilized by muscles of lips and cheeks (facial muscles)
3. Facial muscle contraction during swallowing is not seen	3. Facial muscle contraction can be seen during swallowing
4. Proper, secure, posterior occlusal fit.	4. No proper posterior occlusal fit.
5. Usually will have a previous history of thumb sucking.	5. Usually will have history of tonsillitis or airway obstruction.
6. Treatment is simple with less relapse tendency.	6. Treatment is difficult with , more relapse tendency.
7. Occlusal equilibration may be needed.	7. Occlusal equilibration is mandatory.

3.Lateral tongue thrust (posterior tongue thrust) Some patients usually develop into a habit by thrusting the tongue on to the lateral aspect. Clinically lateral open bite can be seen.

It may be unilateral or bilateral and depends upon the type of tongue thrust. A double oral screen is used to correct this problem

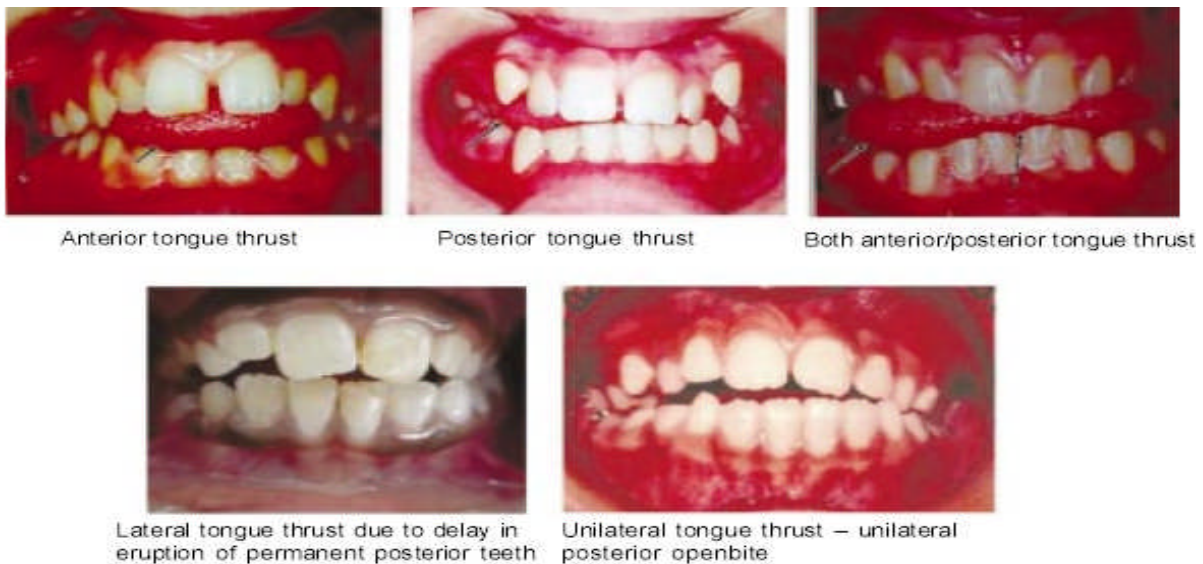


Fig. 7 Different types of tongue thrust

V. Management of tongue thrust:

Age Tongue thrust often self-corrects by 8 or 9 years of age by the time the permanent anterior teeth completely erupt. The self-correction occurs because of an improved muscular balance during swallowing as the mature swallow is adopted.

However it is seen that orthodontic interception is usually more successful than correction if initiated during the early mixed dentition stage of dental development or between ages 9-11 years.

Treatment is generally not recommended when tongue thrust is present without malocclusion or a speech problem. If the tongue thrust is present with malocclusion

but no speech problem orthodontic correction of the malocclusion will usually eliminate the tongue thrust.

If the tongue thrust is present along with malocclusion and a speech problem, speech-and orthodontic correction are needed.

Management of Simple tongue thrust

The management of tongue thrust involves interception of the habit i.e., to remove the etiology followed by treatment to correct the malocclusion. Once the habit is intercepted the malocclusion associated with the tongue thrust is treated using removable or fixed orthodontic appliances.

The treatment of tongue thrust can be divided into various steps:

I. Training of correct swallow and posture of the tongue

a. Myofunctional exercises

Educate the patient about normal swallowing by asking the patient to keep the tongue tip against the junction of soft and hard palate. Various muscle exercise of the tongue can help in training it to adapt to the new swallowing pattern.

- i.. The child is asked to place the tip of the tongue in the rugae area for 5 minutes and is asked to swallow.
- ii. The tongue tip against the palate can hold small orthodontic elastics during swallowing. If the swallow is correct the elastic will be retained in position.



Fig. 8 Tongue trainer

- iii. **4S exercises.** This includes identifying the **spot** by tongue, **salivating**, **squeezing** the spot and **swallowing**.

First exercise is spotting exercise. **Spot** should be the rest position of the tongue. Next is the 2 S exercise. Place the tongue on the spot. It results in **salivation**. It should be followed by **squeezing** the tongue vigorously with the teeth closed against the spot. 'Squeeze' is done by squeezing followed by relaxing. This is **3S** exercise. This should be followed by 4S exercise.

The patient should practice the new swallowing pattern at least 40 times a day. After learning the new swallowing pattern at conscious level, it is necessary to reinforce it subconsciously for transforming the control of the reflex from conscious to unconscious level. Citric acid tablet with bi concave surface is used for the above said transformation. Ask the patient to hold the tablet using the tongue tip against the hard and soft palate as long as possible. Initially the patient can hold for only a few seconds, gradually the duration can be extended. The patient concentration should be diverted towards a hand held clock to note down the duration of holding the tablet in correct position. Most of the patients can be treated using the above said treatment protocol. If is not corrected, the patient has to go to the next step of the treatment.

II. Appliances to guide the correct positioning of tongue(Fig 8-11)

Once the patient is familiar with the new tongue position an appliance is given for training the correct positioning of the tongue.

Pre orthodontic trainer/ Tongue trainer This appliance aids in the correct positioning of the tongue with the help of tongue tags. The tongue guards prevent the tongue thrusting when in place. It can also be used to correct mouth breathing habit(fig 8)

III. Mechano therapy Both fixed and removable appliances (cribs or rakes) can be fabricated to restrain anterior tongue movement during swallowing with the objective of retraining the tongue to a more posterior superior position in the oral cavity. Both fixed and removable are valuable aids in breaking the habit.

All forms of habit braking appliances (tongue thrust appliance) have some form of physical obstruction to the forceful anterior movements of tongue during thrusting. These appliances tends to force the tongue downward and backward during swallowing.. The spurs and cribs which are placed palatally

acts to wall off the tongue during thrusting. The appliance also conditions the reflexes and guides the tongue position so that the dorsum of the tongue approximates the palatal vault and the tip of the tongue contacts the palatal rugae during deglutition. As a result the tongue spreads laterally and exerts pressure on the maxillary buccal portion is widened thereby preventing the narrowing of the arch.

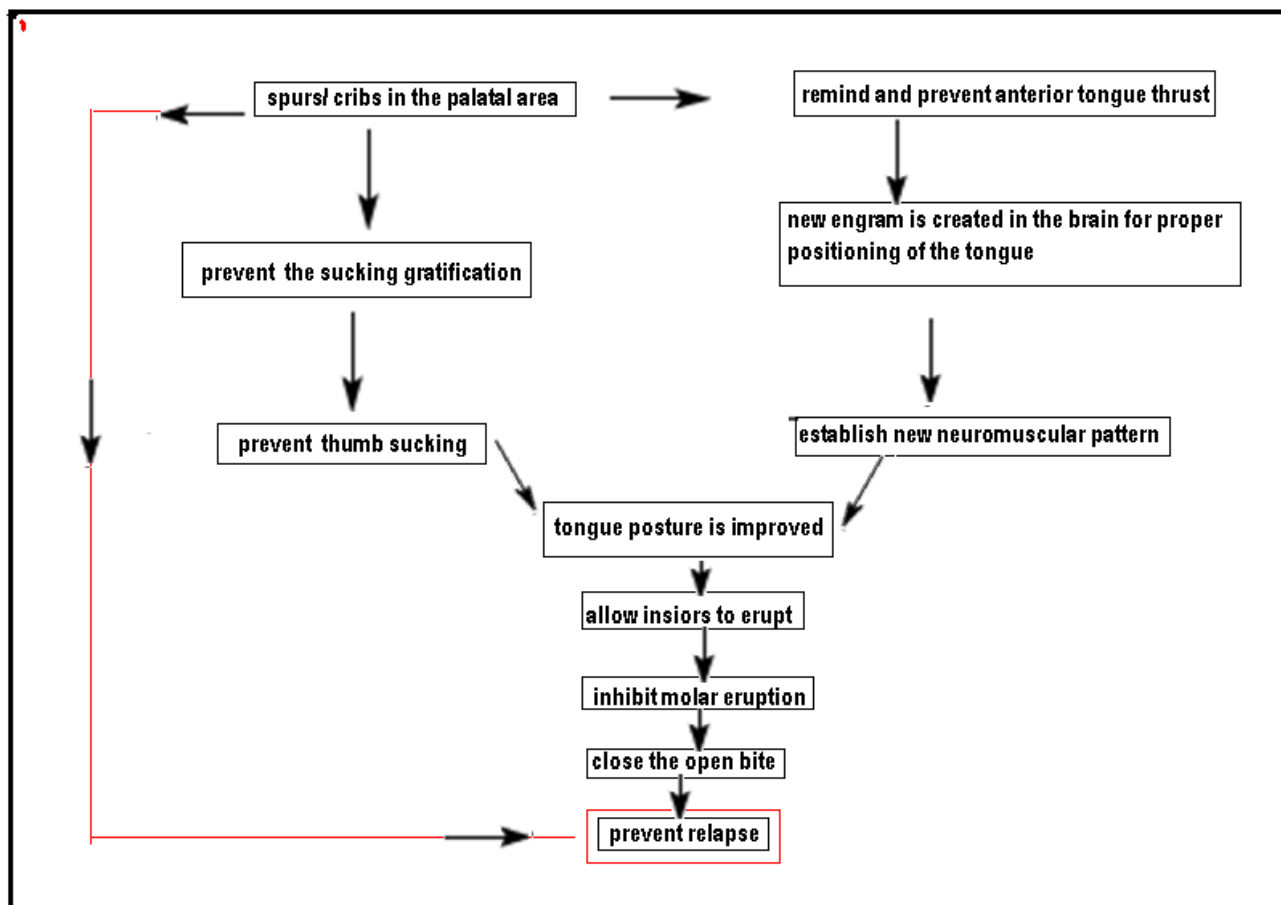
Choice of appliance:

1. A well adapted soldered lingual arch wire having short, sharp spurs can now be

inserted; protectively the tongue is withdrawn from the abnormal position and placed properly during swallowing.

2. For cooperative patients oral screen can be used.
3. Removable appliance with tongue spurs or spikes can also be used in cooperative patients.
4. A fixed crib may be used along with fixed corrective appliance.

The flow chart shows the mechanism of this appliances and how they interrupt thumb sucking and tongue thrusting habit.



Flow chart showing the mechanism of action of habit breaking appliances

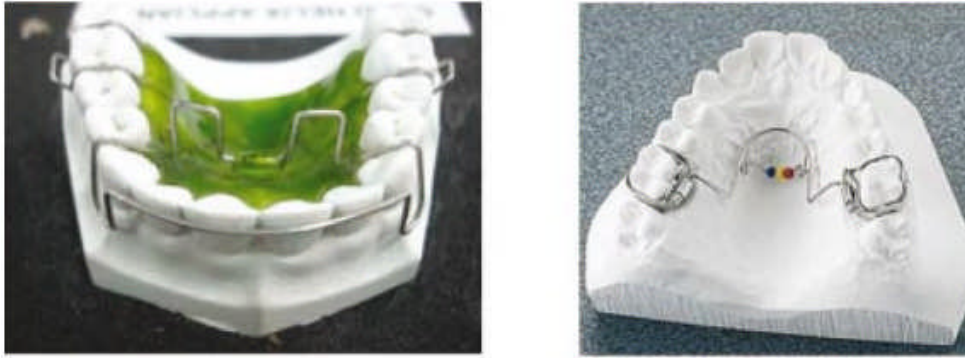

Fig.9 Blue grass appliance

a. Removable appliance therapy

A variety of modifications of Hawley's appliance can be used to treat tongue thrust. It has an active labial bow, retentive clasps, a crib or rake or spikes present posteriorly to the upper anterior teeth. The crib can serve as a reminder. The spikes should be bent in such a way that when it is worn it should not impinge on lower anteriors or anterior lingual alveoli. Usually the open bite is closed down by activating the labial bow. Activation of labial bow reduces the proclination of the upper anterior teeth. The acrylic should be trimmed off from the gingival marginal area of the lingual surfaces of the maxillary anteriors to allow the incisors to be move palatally. The loops of the tongue crib are removed one by one as the patient is weaned from the habit appliance over a 6 month period.

b. Fixed Habit breaking appliance

Bands are adopted on the first permanent molar and a 0.040 inch stainless steel 'U'- shaped wire is adopted from one molar to another molar of the opposite side. After the base bar is fabricated the crib can be formed and soldered to the base. Depending on the severity of the open bite, 6-12 months may be required for the autonomous correction of the malocclusion. The cribs acts by walling off the tongue from the dentoalveolar structures. They acts as reminders to the tongue when ever it tries to thrust forwards. A new engram is created by the nervous system so that the tongue learns proper position in long term. Thus this appliances create a new neuromuscular behavior.

The cribs can be fabricated along with expansion devices like quadhelix and expansion screw if the arch is constricted.



Fig 10 Some fixed habit breaking appliances: a, Fixed tongue crib; b, Tongue cri with Quad helix; C, Tongue crib with expansion screw

C.Oral screen

Another effective means of controlling abnormal muscle habits like tongue thrusting and at the same time utilizing the musculature to effect a correction

of the developing malocclusion, is the vestibular or oral screen or a combination. These appliances have been used mostly to intercept mouth breathing ,tongue thrusting, lip biting and cheek biting. They also correct mild proclination of anterior teeth.

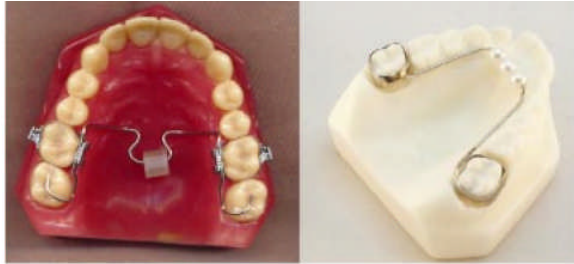

Fig. 11 Blue grass appliance (Haskell appliance)

Management of complex tongue thrust

The prognosis of complex tongue thrust will not be that much good when compared to simple tongue thrust if it is of neuromuscular origin..

The two reflexes involved are

1. Abnormal occlusal reflex
2. Abnormal swallow

TREATMENT PROTOCOL

1. Treat the occlusion first with contemporary fixed orthodontic appliance followed by careful equilibration.
2. The muscle training then begun is similar to that for a simple tongue thrust with minor modification.
3. Great emphasis must be placed on keeping the teeth together during swallowing.
4. A maxillary lingual archwire with short, sharp spurs may be used as retainer.
5. It is important to do meticulous teeth positioning and careful equilibration followed by persistent myotherapy.

Referenes

1. Iley WJ. A clinical appraisal of tongue-thrusting. *Am J Orthod* 1969;55:640-50
2. Brauer, Townsend V. Holt. Tongue Thrust Classification. *The Angle Orthodontist*,1965: 35(2):106-112.
3. Maguire JA. The evaluation and treatment of pediatric oral habits. *Dent Clin North Am.* 2000 Jul;44(3):659-69,
4. Pannbacker J *Speech*. Comment on Hanson's "Tongue Thrust: A Point of View" *Hear Disord*.1976; 41: 559
5. Maguire JA. The evaluation and treatment of pediatric oral habits. *Dent Clin North Am.* 2000 Jul;44(3):659-69.
6. Peng CL. Comparison of tongue functions between mature and tongue-thrust swallowing—an ultrasound investigation, *Am J Orthod Dentofac Orthop*,2004;125;5:562-570.
7. Fred S. Fink .The Tongue, the Lingometer, and the Role of Accommodation in Occlusion. *The Angle Orthodontist*: 1986;56(30):225-233.
8. Curtis E. Weiss .A Directional Change in Tongue Thrust. *Int J Lan Com Dis*1972;. 7(2):131-134
9. Burford, Daniel Noar, Joe H. Etiological aspects of anterior open bite. *Dent update*,2003;30(5):235-41
10. Warren J. J., Bishara S. E., Steinbock K. L., Yonezu T, Nowak A. J.: Effects of oral habits' duration on dental characteristics in primary dentition. *J Am Dent Assoc* 2001; 132: 1685 - 93.
11. Tomita N. E., Bijella V. T, Franco L. J.: The relationship between oral habits and malocclusion in preschool children. *Rev Saude Publica* 2000; 34: 299 - 303.
12. Khinda V., Grewal N.: Relationship of tongue thrust swallowing and anterior open bite with articulation disorders. *J Ind Soc of Pedo Prev Dent* 1999; 17: 33 - 39.
13. Michael Speidel, Robert J. Isaacson ,Frank W. Worms .Tongue-thrust therapy and anterior dental open-bite: A review of new facial growth data. *Am J Orthod*,1972: 62:: 287-295
14. Winders RV. Forces exerted on the dentition by the perioral and lingual musculature during swallowing. *Angle Orthod* 1958;28:226-35.
15. Takada K, Yashiro K, Sorihashi Y, Morimoto T, Sakuda M. Tongue, jaw and lip muscle activity and jaw movement during experimental chewing efforts in man. *J Dent Res* 1996;75:1598-606